

Available online at [www.sciencedirect.com](http://www.sciencedirect.com)

ScienceDirect

journal homepage: <http://Elsevier.com/locate/radcr>

## Case Report

# Control of massive hemoptysis via a “back-door” approach through the pulmonary artery

Christopher D. Malone MD<sup>a,\*</sup>, Raja S. Ramaswamy MD<sup>b</sup>, Steven C. Rose MD<sup>a</sup>

<sup>a</sup> Department of Radiology, University of California, San Diego, San Diego, CA, USA

<sup>b</sup> Mallinckrodt Institute of Radiology, Washington University School of Medicine in St. Louis, St. Louis, MO, USA

## ARTICLE INFO

## Article history:

Received 22 March 2016

Accepted 24 March 2016

Available online 20 April 2016

## Keywords:

Bronchial artery embolization

Pulmonary angiography

Hemoptysis

Tuberculosis

## ABSTRACT

Bronchial artery embolization is an effective nonsurgical therapy for massive hemoptysis. Routine selection of the bronchial arteries from the aorta usually enables the interventionalist full interrogation and embolization of the culprit vascular abnormality. In problematic cases where bronchial artery access is difficult, a systemic-to-pulmonary arterial shunt can be exploited as a retrograde means of vascular intervention. A case is presented where inaccessibility of a tortuous left bronchial artery was circumvented by accessing the left pulmonary artery, leading to successful embolization and control of hemoptysis.

Copyright © 2016, the Authors. Published by Elsevier Inc. under copyright license from the University of Washington. This is an open access article under the CC BY-NC-ND license (<http://creativecommons.org/licenses/by-nc-nd/4.0/>).

## Introduction

Bronchial artery embolization is considered the most effective nonsurgical emergent treatment for massive hemoptysis, which holds 50%-100% mortality rate if treated conservatively [1]. Although access to these abnormal vascular networks is typically through the systemic bronchial artery circulation, adequate vessel purchase and catheterization can be difficult when vessel tortuosity and unfavorable angle of origin are present. In these cases, a “back-door” approach accessing bronchial arterial vascular abnormalities by catheterizing the pulmonary artery when a systemic bronchial-to-pulmonary artery shunt exists is a viable option. However, a paucity of literature describing this approach exists [2]. A case is presented where control of hemoptysis from a shunt communicating the left pulmonary and

bronchial artery branches is achieved by pulmonary arterial access after initial attempt to adequately select the left bronchial artery failed.

## Case report

A 32-year-old woman with a remote history of tuberculosis and recurrent aspergillomas of the left lung resulting in autopenumectomy presented with frequent episodes of hemoptysis up to 400 mL in volume. Computed tomography of the thorax showed severe destruction and near complete absence of the left lung parenchyma (Fig. 1). Although surgical left pneumonectomy was initially considered, interventional radiology was consulted for emergent bronchial artery angiogram and potential embolization.

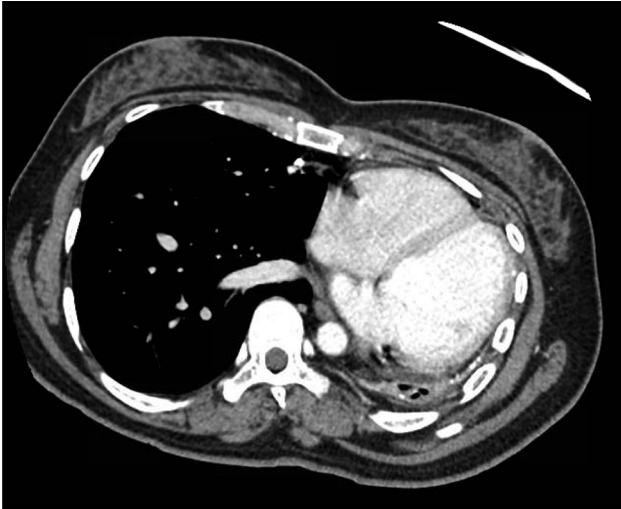
Competing Interests: All the authors have declared that no competing interests exist.

\* Corresponding author.

E-mail address: [cmalone@ucsd.edu](mailto:cmalone@ucsd.edu) (C.D. Malone).

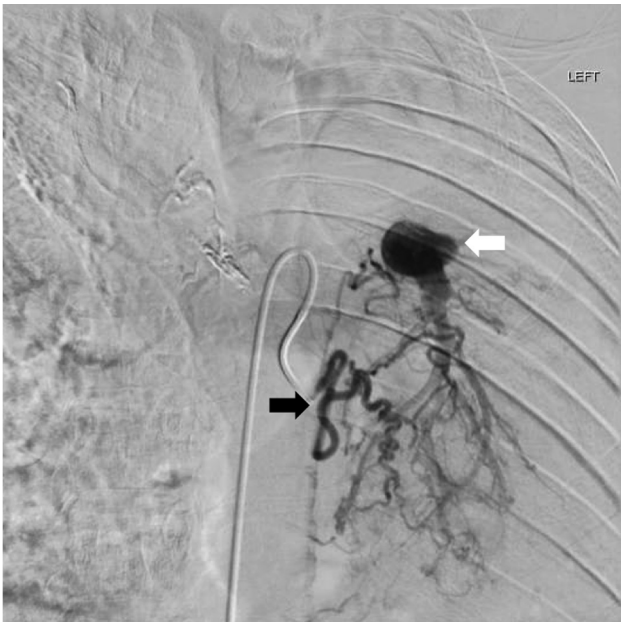<http://dx.doi.org/10.1016/j.radcr.2016.03.001>

1930-0433/Copyright © 2016, the Authors. Published by Elsevier Inc. under copyright license from the University of Washington. This is an open access article under the CC BY-NC-ND license (<http://creativecommons.org/licenses/by-nc-nd/4.0/>).



**Fig. 1 – Axial computed tomography scan of the thorax demonstrated marked atrophy of the left lung, with very little remaining lung parenchyma.**

Initial aortogram demonstrated hypertrophied bilateral bronchial arteries, without clear additional systemic arterial source of hemoptysis. Angiogram of the single left bronchial artery demonstrated it to be enlarged, tortuous, and with significant shunting to the left lower pulmonary artery (Fig. 2). Despite multiple attempts with several catheters



**Fig. 2 – Selection of the left bronchial artery (black arrow) with a 5-French Shetty catheter (Cook Medical, Bloomington, IN, USA) demonstrated a markedly tortuous, hypertrophic network of vessels with shunting to the left pulmonary artery (white arrow). Despite multiple attempts, a microcatheter was unable to be advanced distally into the left bronchial artery.**

and microcatheters, access to the left bronchial artery for intervention could not be achieved due to vessel tortuosity, vasospasm, and unfavorable angle of origin. Given the long fluoroscopy time, the procedure was aborted in favor of an alternate approach via the pulmonary artery at a later time. Bronchoscopy performed the following day demonstrated active bleeding at the left lower lobe basal segment airways, confirming this region as the primary source of hemoptysis.

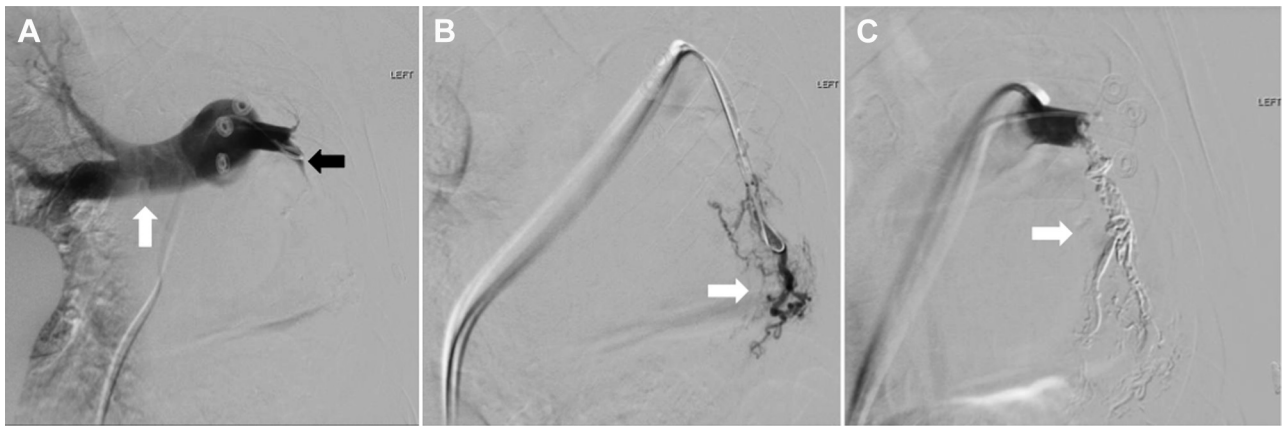
Repeat angiography was performed to gain access to the abnormal vasculature of the left lower lobe through the left pulmonary artery. Digital subtraction angiography of the proximal pulmonary artery demonstrated normal brisk flow of the right main branch and severe narrowing and near stasis of the left main branch (Figs. 3A). Distal left pulmonary artery contrast injection showed multiple distorted branches of the basal segments corresponding to the systemic-pulmonary arterial outflow seen on the prior left bronchial angiogram (Fig. 3B). The basal segment of the left pulmonary artery was catheterized with a 3-French Progreat microcatheter (Terumo Medical; Tokyo, Japan) with subsequent tandem deployment of an AVP-II Amplatzer vascular plug (St. Jude Medical, St. Paul, MN, USA) as a backstop to prevent reflux of embolization material. Through the microcatheter, the left pulmonary artery basal segmental artery was embolized with Onyx-18 (EV 3, Covidien; Mansfield, MA, USA) distally and up to the Amplatzer plug. Post-embolization digital subtraction angiography demonstrated occlusion of the entire basal segment with no residual flow (Fig. 3C).

The patient tolerated the procedure well and has experienced no episodes of recurrent hemoptysis with clinical follow up at 18 months.

## Discussion

Most vascular causes of hemoptysis are due to friable and abnormal bronchial vasculature subjected to high-systemic pressures that have developed from chronic pulmonary processes such as bronchiectasis, tuberculosis, fungal infections, and malignancy [3]. Chronic inflammation and hypoxia result in abnormal and fragile neovascularization of the bronchial arteries and its branches, which are susceptible to hemorrhage under systemic pressures [4]. These vascular abnormalities usually manifest as hypertrophied, tortuous and hypervascular bronchial arteries, systemic-to-pulmonary arterial shunts, and bronchial artery aneurysms [1].

Accessing the pulmonary artery in cases of hemoptysis has been advocated when hemoptysis is not controlled after systemic bronchial embolization and when the pulmonary artery itself is the source of bleeding, such as with Rasmussen aneurysms [5] and arteriovenous fistulas [6]. However, few cases have been described accessing the pulmonary artery in attempts to access a bronchial vascular lesion through systemic-pulmonary arterial connections in the absence of a primary pulmonary artery lesion [2]. Embolization of the distal pulmonary arterial network supply may also increase the efficacy of hemoptysis control. Bredin et al. [7] described a case where massive hemoptysis that had decreased after systemic bronchial artery embolization, completely ceased



**Fig. 3 – (A)** Angiogram of the main pulmonary artery showed brisk and normal opacification of the right pulmonary artery (white arrow) and significant pruning and stasis of the left pulmonary artery (black arrow). Note metallic snaps external to the patient project over the pulmonary trunk. **(B)** microcatheter selection of the basal segments of the left pulmonary artery demonstrated a network of significantly tortuous and hypertrophic vessels (white arrow) that corresponded to the outflow of the systemic-pulmonary arterial shunt seen on the prior attempt in [Figure 2](#). **(C)** Status post-Onyx embolization and Amplatzer plug of the entire basal segment tree (white arrow), with no residual flow demonstrated.

after temporarily occluding the distal pulmonary artery with a balloon catheter. In this presented case, use of an Amplatzer plug was important to prevent reflux of embolization material and nontarget contralateral pulmonary artery embolization, which may have further compromised her tenuous pulmonary reserve. Although there may be a risk of pulmonary infarction from embolic occlusion of the pulmonary artery, this patient had very little remaining left lung parenchyma.

In conclusion, this case illustrates the viability of exploiting a pulmonary-bronchial artery shunt to control hemoptysis by accessing the pulmonary arterial vasculature when initial bronchial catheterization is difficult or not possible.

#### REFERENCES

- [1] Lopez JK, Lee HY. Bronchial artery embolization for treatment of life-threatening hemoptysis. *Semin Intervent Radiol* 2006;23:223–9.
- [2] Tamashiro A, Miceli MH, Rando C, Tamashiro GA, Villegas MO, Dini AE, et al. Pulmonary artery access embolization in patients with massive hemoptysis in whom bronchial and/or nonbronchial systemic artery embolization is contraindicated. *Cardiovasc Intervent Radiol* 2008;31:633–7.
- [3] Larici AR, Franchi P, Occhipinti M, Contegiacomo A, del Ciello A, Calandriello L, et al. Diagnosis and management of hemoptysis. *Diagn Interv Radiol* 2014;20:299–309.
- [4] Chun JY, Morgan R, Belli AM. Radiological management of hemoptysis: a comprehensive review of diagnostic imaging and bronchial arterial embolization. *Cardiovasc Intervent Radiol* 2010;33:240–50.
- [5] Remy J, Lemaitre L, Lafitte JJ, Vilain MO, Saint Michel J, Steenhouwer F. Massive hemoptysis of pulmonary arterial origin: diagnosis and treatment. *AJR Am J Roentgenol* 1984;143:963–9.
- [6] Stoll JF, Bettmann MA. Bronchial artery embolization to control hemoptysis: a review. *Cardiovasc Intervent Radiol* 1988;11:263–9.
- [7] Bredin CP, Richardson PR, King TK, Sniderman KW, Sos TA, Smith JP. Treatment of massive hemoptysis by combined occlusion of pulmonary and bronchial arteries. *Am Rev Respir Dis* 1978;117:969–73.