

Cluster outbreak of *Pseudomonas stutzeri* acute endophthalmitis following phacoemulsification: A report of 14 cases from North India

Sabia Handa, Simar Rajan Singh, Bhawna Sharma¹, Vipin Rana, Krinjeela Bazgain, Uday Tekchandani, Shashank Narang, Archana Angrup¹, Manisha Biswal¹, Pallab Ray¹, Vishali Gupta

Purpose: To report clinical features, antibiotic susceptibility profile, management, and outcomes of a cluster outbreak of post-cataract surgery *Pseudomonas stutzeri* endophthalmitis. **Methods:** This was a hospital-based case series in which 14 patients with acute postoperative endophthalmitis who underwent cataract surgery on the same day were included. Based on severity of presentation, they either underwent pars plana vitrectomy (PPV) with intraocular antibiotics (IOAB) or vitreous tap with IOAB. Vitreous aspirates and environmental surveillance samples were inoculated on culture media and further processed by MALDI-TOF MS for identification and Vitek3 for susceptibility profile. **Results:** There were 8 females and 6 males with a mean age of 62.14 ± 8.08 years. Presenting signs included corneal folds (100%), hypopyon (57.1%) and fibrin (50%). Ten patients with mild presentation underwent vitreous tap with IOAB. Four patients with severe presentation underwent PPV with IOAB. *Pseudomonas stutzeri* was isolated from the vitreous samples and was pan-sensitive. Six eyes required multiple interventions. Favorable outcome was obtained in 12 eyes, one eye developed phthisis, and one patient was lost to follow-up. **Conclusion:** We report the first ever cluster outbreak of *Pseudomonas stutzeri* endophthalmitis following phacoemulsification with IOL implantation in a single surgeon setting. Majority of the patients had a mild presentation and responded well to targeted anti-microbial treatment.

Key words: Acute endophthalmitis, cluster endophthalmitis, *Pseudomonas*

Endophthalmitis is the most dreaded complication following cataract surgery with an incidence of 0.07% to 0.12%.^[1] The most common organism implicated for acute endophthalmitis (occurring within six weeks of surgery) is *Staphylococcus epidermidis*, accounting for 60%–80% of the cases, followed by Gram-negative bacteria that are responsible for 6%–29% of the cases.^[1] In developing countries like India, Gram-negative organisms can form up to 43% of the culture-proven cases.^[2,3] Endophthalmitis secondary to Gram-negative organisms tends to be rapidly progressive, resulting in poor anatomical and visual outcome despite prompt antibiotic therapy.^[4-6]

Among the Gram-negative bacteria causing acute postoperative endophthalmitis, *Pseudomonas aeruginosa* is the most common isolated species including cases of cluster outbreaks.^[7-11] Other *Pseudomonas* species like *Pseudomonas stutzeri* have been reported to cause isolated cases of postoperative endophthalmitis.^[12-15] However, there are no reports of cluster endophthalmitis post cataract surgery following infection with *Pseudomonas stutzeri*. The purpose of this study was to describe the demographic profile, clinical course, and microbiological profile of 14 patients who developed acute *Pseudomonas stutzeri* endophthalmitis

following phacoemulsification with intraocular lens (IOL) implantation in a single surgeon setting.

Methods

In the present study, 14 consecutive patients who developed acute postoperative endophthalmitis following phacoemulsification with IOL implantation at a satellite center attached to a private hospital in North India are reported. The study was conducted under the tenets of the Declaration of Helsinki and ethical clearance was obtained from the Institute Ethics Committee of the Post Graduate Institute of Medical Education and Research (PGIMER), Chandigarh, India.

Immediate disaster management response

The emergency retina services of PGIMER were alerted regarding 9 cases of suspected endophthalmitis presenting on second post-operative day by a cataract surgeon from a nearby private eye hospital. These patients were immediately asked to report to PGIMER, and the primary surgeon was advised to call back and examine all patients operated on that day. Following these, 5 more patients out of the total of 22 operated on that day were identified to have endophthalmitis and reported to

This is an open access journal, and articles are distributed under the terms of the Creative Commons Attribution-NonCommercial-ShareAlike 4.0 License, which allows others to remix, tweak, and build upon the work non-commercially, as long as appropriate credit is given and the new creations are licensed under the identical terms.

For reprints contact: WKHLRPMedknow_reprints@wolterskluwer.com

Cite this article as: Handa S, Singh SR, Sharma B, Rana V, Bazgain K, Tekchandani U, et al. Cluster outbreak of *Pseudomonas stutzeri* acute endophthalmitis following phacoemulsification: A report of 14 cases from North India. Indian J Ophthalmol 2022;70:2084-9.

Access this article online

Website:
www.ijo.in

DOI:
10.4103/ijo.IJO_3096_21

Quick Response Code:



Department of Ophthalmology, Advanced Eye Centre, ¹Department of Medical Microbiology, Post Graduate Institute of Medical Education and Research, Chandigarh, India

Correspondence to: Dr. Vishali Gupta, Professor, Advanced Eye Centre, Post Graduate Institute of Medical Education and Research, Sector 12, Chandigarh - 160 012, India. E-mail: vishalisara@gmail.com

Received: 18-Dec-2021

Revision: 15-Feb-2022

Accepted: 31-Mar-2022

Published: 31-May-2022

us the next day. An immediate management plan was drawn up based on the severity of the infection and the vitreo-retinal surgeons were divided into three teams. One team took care of patients requiring tap-and-inject while the second team prepped the operation theater for patients requiring primary vitrectomy. The third team coordinated between the two teams and took care of immediate processing of microbiological samples obtained.

Study subjects and their evaluation

The demographic and clinical details of the subjects including age, gender, laterality, presenting signs and symptoms, systemic comorbidities, and the time elapsed between the surgery and appearance of symptoms were noted. At the time of presentation, the best-corrected visual acuity (BCVA), intraocular pressure (IOP), examination of the anterior chamber using slit-lamp biomicroscopy, and fundus examination using indirect ophthalmoscopy with 20D lens were done. Anterior segment photography was performed to document the presenting clinical features. Fundus photography was done using Optos ultrawide field fundus camera (Optos P200Tx, Optos, Scotland, UK). In patients with significant media haze, ultrasound B-scan was performed.

Management

The plan of management was based on severity of presentation decided by two experienced vitreo-retinal surgeons (VG, SRS). The patients who had hypopyon, fibrinous exudates on IOL surface, media clarity grade 4–5 and dense vitreous exudates on B-scan ultrasonography were classified as “severe” and planned for immediate pars plana vitrectomy (PPV) with intraocular antibiotics (IOAB). Patients with some visibility of the retinal vessels with indirect ophthalmoscope were classified as “mild” and taken up for a vitreous tap with IOAB. Media clarity was the sole criterion used to classify patients as mild/severe in this case series. For the patients who were subjected to PPV, after removal of the fibrin membrane from the anterior chamber, an undiluted vitreous sample was obtained for microbiological analysis. Following this, a core vitrectomy was done, and IOAB vancomycin (1 mg/0.1 mL) and ceftazidime (2.25 mg/0.1 mL) were given at the end of the surgery. For those subjected to tap-and-inject, a vitreous tap was taken under microscopic visualization with a 23-gauge needle and IOAB were injected. Patients in both groups were evaluated daily and secondary interventions were planned in cases with no improvement or worsening condition as per the discretion of the surgeon.

Microbiological analysis and environmental surveillance

A total of 17 vitreous samples from 14 endophthalmitis patients over a period of three days were analyzed in the microbiology laboratory of PGIMER, Chandigarh. Gram stain microscopy was performed on all the vitreous samples. The samples were inoculated on blood agar, MacConkey agar, chocolate agar, and on Robertson’s cooked meat (RCM) medium and incubated overnight aerobically with 5% CO₂. For the fungal culture, the samples were inoculated on Sabouraud’s dextrose agar and brain heart infusion agar. After overnight incubation, samples showing pure growth on culture plates were further processed for identification by matrix-assisted laser desorption/ionization time of flight mass spectrometry (MALDI–TOF MS) (BioMérieux Inc., Durham, NC). The antibiotic susceptibility of positive cultures was performed

using Vitek-2® (BioMérieux Inc., Durham, NC) automated system which took further 6–8 hours. Furthermore, following the outbreak, microbiological analysis was also performed on surveillance samples obtained from the air-conditioning system, walls, floor, instrument trolley, microscope surface, irrigating solution (BSSOL-500) and viscoelastic of the same batch used in the patients. However, the surveillance samples could not be obtained from the internal tubing of the phacoemulsification machine, povidone iodine solution, phacoemulsification hand piece and irrigation aspiration cannula. To further confirm the outbreak, polymerase chain reaction (PCR) was done with specific primers on all obtained. DNA was extracted by inhouse boiling point extraction method. The amplification products were electrophoresed through a 2% agarose gel and visualized with UV transilluminator after ethidium bromide staining. A 100 bp DNA ladder was used as a molecular size marker in gel.

Statistical analysis

Statistical analysis was performed using GraphPad Prism V.6.0 (GraphPad Software, La Jolla, CA). The quantitative data were expressed in mean along with standard deviations.

Results

Clinical presentation

Fourteen out of 22 patients who were operated on the same day by a single surgeon developed post cataract surgery endophthalmitis. All patients had undergone an uncomplicated phacoemulsification with IOL implantation two days earlier. There were 8 females and 6 males with a mean age of 62.14 ± 8.08 years (range, 50–78 years). The demographic details, clinical features, management, and outcomes of all patients are listed in Table 1. While 9 patients presented with pain, redness, and diminution of vision on postoperative day 2, the rest 5 were detected on active call back of the remaining patients. The BCVA at presentation ranged from light perception to 20/80. Majority of the patients (78.6%) had BCVA worse than 20/200. All patients had circumciliary congestion and corneal folds; hypopyon was present in 8 patients (57.1%); fibrin over IOL surface was present in 7 patients (50%). None of the patients had corneal infiltrates. Media clarity was grade 3 or better in 10 patients (71.4%), whereas 4 patients (28.5%) had severe presentation with media clarity of grade 4–5. B-scan ultrasonography showed dense vitreous echoes suggestive of exudates in these four patients. Almost 50% (2/4) of patients with severe presentation had co-existent type 2 diabetes mellitus (DM) while only 10% (1/10) with mild presentation had DM.

Treatment

All patients were admitted indoors and were started on intravenous ciprofloxacin 200 mg twice daily. Topicals started empirically included moxifloxacin 0.5%, betamethasone 0.1% and atropine 1%. Systemic prednisolone in a dose of 1 mg/kg body weight was given to all patients after ruling out fungal infection on smears and under-monitoring of blood sugars. The intravenous antibiotic was changed to intravenous ceftazidime the next day once the antibiotic susceptibility was available. Four patients with severe presentation underwent primary PPV with IOAB injection [Fig. 1]. Intraoperatively, one patient (case 7) was noticed to have a cherry red spot and pale retina suggestive of central retinal artery occlusion [Fig. 2].

Table 1: Demographic profile, clinical presentation, management, and outcomes of patients with post cataract surgery Pseudomonas stutzeri cluster endophthalmitis presented in the order in which they presented

Age	Sex	Eye	Comorbidity	Anterior Segment			Posterior Segment			Primary Intervention	Secondary Intervention	Outcome	Special Notes
				Corneal Folds	Hypopyon	Fibrin	Media grade	Presentation					
59	F	OD	-	+	+	+	5	Severe	PPV + IOAB		Favorable	20/40	
50	F	OS	DM, HTN	+	+	+	3	Mild	Tap + IOAB	PPV + IOAB	Favorable	20/40	
55	F	OS	-	+	-	+	1	Mild	Tap + IOAB		Favorable	20/40	
68	M	OS	HTN	+	+	+	2	Mild	Tap + IOAB		Favorable	20/200	
55	F	OS	-	+	+	-	3	Mild	Tap + IOAB		Favorable	20/40	
78	F	OS	-	+	+	-	2	Mild	Tap + IOAB		Favorable	20/30	
50	F	OS	DM, HTN	+	+	+	4	Severe	PPV + IOAB	Re-PPV + IOAB	Unfavorable	PL - CRAO	
70	M	OS	DM	+	+	+	5	Severe	PPV + IOAB	IOAB	Favorable	20/20	
60	F	OS	-	+	+	+	5	Severe	PPV + IOAB	Re-PPV + SOT	Favorable	20/200	
60	M	OD	-	+	-	-	3	Mild	Tap + IOAB		Favorable	20/80	
65	M	OD	HTN	+	-	-	3	Mild	Tap + IOAB		Favorable	20/40	
70	M	OS	-	+	-	-	3	Mild	Tap + IOAB		Favorable	20/40	
65	M	OS	-	+	-	-	3	Mild	Tap + IOAB	PPV + IOAB	Favorable	20/40	
65	F	OS	HTN	+	-	-	3	Mild	Tap + IOAB	PPV + IOAB	Favorable	LAMA	

CF 1 ft - Counting fingers at one feet, CFCF - Counting fingers close to face, CRAO - Central retinal artery occlusion, DM - Diabetes mellitus, HMCf - Hand motions close to face, HTN - Hypertension, IOAB - Intraocular antibiotics, L - Left, LAMA - Left against medical advice, PL - Perception of light, PPV - Pars plana vitrectomy, R - Right, RRD - Rhegmatogenous retinal detachment

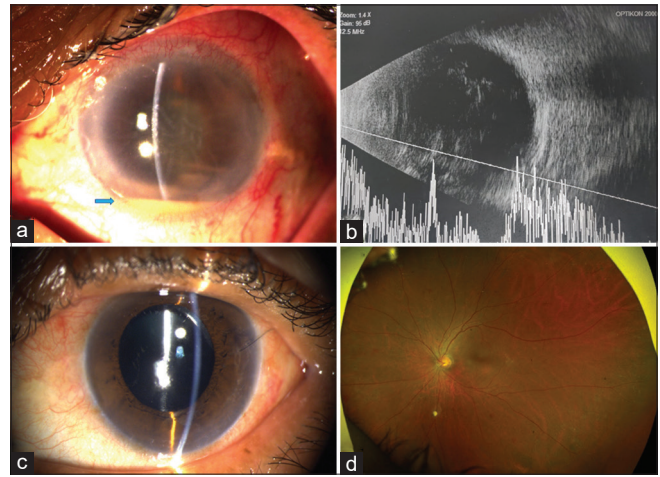


Figure 1: Severe presentation (case 8). (a) Anterior segment photograph of left eye at presentation showing circumciliary congestion, corneal folds, hypopyon (blue arrow) and fibrin on the intraocular lens surface. There was no view of the fundus. (b) Ultrasound B + A axial scan showing dense membranous echoes in the vitreous cavity suggestive of exudates with an attached retina. (c) Postoperative 3-week anterior segment photograph showing complete resolution of anterior segment inflammation. (d) Ultra-wide field fundus photograph at 3 weeks showing a clear media

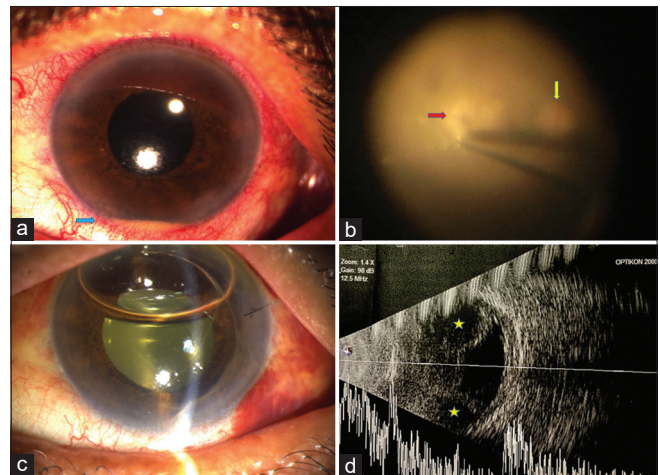


Figure 2: Severe presentation (case 7). (a) Anterior segment photograph of the left eye at presentation showing circumciliary congestion and hypopyon (blue arrow). Fundus had a red glow. (b) Intraoperative surgeon's view after clearing the vitreous exudates showing the optic disc (yellow arrow) and whitening of the retina at the posterior pole (red arrow) with a cherry red spot indicative of central retinal artery occlusion. (c) Postoperative day 3 photograph showing persistence of yellow glow behind the lens. Patient was taken up for repeat vitrectomy. (d) Ultrasound B + A axial scan 1 week following the second vitrectomy showing 360° serous choroidals (yellow star) with a thickened retino-choroid and clear vitreous cavity. This eye subsequently went into phthisis

This patient was an uncontrolled diabetic and had persistence of exudates after the initial core vitrectomy. A repeat complete vitrectomy with posterior vitreous detachment was done 72 hours later. Despite this, the patient had persistent hypotony with serous choroidal and ultimately went into phthisis bulbi. Another patient (case 8) required repeat IOAB following

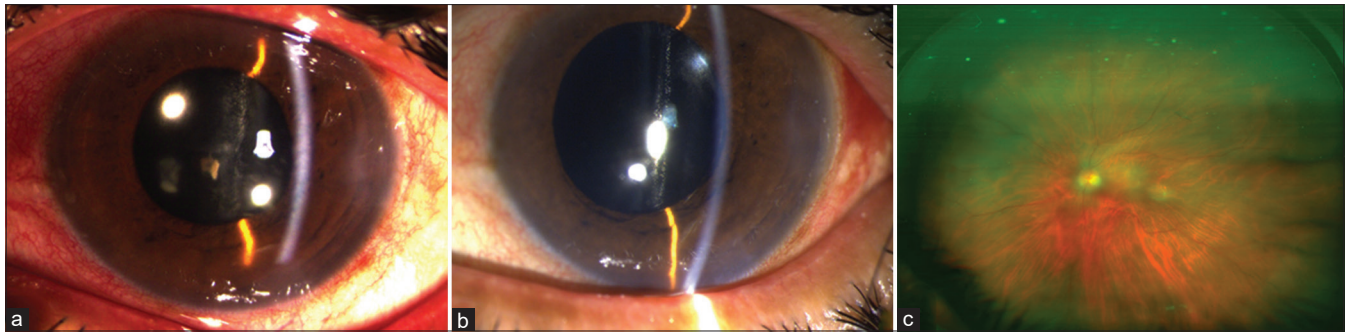


Figure 3: Mild presentation (case 3). (a) Anterior segment photograph of the left eye at presentation showing circumciliary congestion, corneal folds, and fibrin on the lens surface. There was no hypopyon. (b) Anterior segment photograph 1 week following vitreous tap with intraocular antibiotics showing resolution of inflammation. (c) Ultra-wide field fundus photograph 1-week following presentation showing a clear media with few residual vitreous membranes

PPV, and had a favorable outcome. Both these patients had type 2 DM. One patient (case 9) who underwent primary PPV developed rhegmatogenous retinal detachment after resolution of endophthalmitis and underwent re-PPV with encircling band and silicone oil tamponade. Remaining 10 patients with mild presentation underwent vitreous tap with injection of IOAB [Fig. 3]. Three out of these 10 patients underwent PPV with IOAB as a secondary intervention due to persistent inflammation after 48 hours.

Microbiological analysis

Out of 17 vitreous samples, Gram stain showed the presence of pus cells in 14 samples and a single morphotype of Gram-negative bacilli in 12 samples. On culture, pure growth of non-lactose fermenting bacteria was obtained after overnight incubation, all of which were identified as *Pseudomonas stutzeri* by MALDI-TOF MS [Fig. 4]. Colonies obtained were dry in character (whole colonies got dried up after overnight incubation) which were oxidase positive. Cultures of remnants of drugs, used vials obtained from the primary surgeon were sterile after overnight incubation. Microscopy revealed no fungal elements, and the fungal cultures were sterile after three weeks of incubation. Antibiotic susceptibility pattern was similar in all the isolates as it was sensitive to all the drugs: amikacin, ceftazidime, cefepime, piperacillin-tazobactam, imipenem, meropenem, gentamicin, levofloxacin, aztreonam, and tobramycin. Surveillance samples from the air conditioning system sent to a local laboratory by the primary surgeon reportedly grew *Pseudomonas stutzeri* though the same was not available for further analysis. Surveillance samples analyzed at our laboratory did not grow any significant organism. It should be noted that the samples provided to us were taken after an initial round of disinfection of the operation theater. PCR were done with specific primers for *Pseudomonas stutzeri* as per the protocol given by Cladera *et al.*^[16] Primers used were 16S ribosomal DNA, internally transcribed spacer region 1 (ITS 1), *gyrB* and *rpoD*. The PCR for all the primers was positive for all the isolates of *Pseudomonas stutzeri* [Fig. 5]

Anatomical and visual outcomes

A total of 13 patients were available for determination of outcome at three months following presentation. One patient (case 13) who received IOAB left against medical advice and did not follow up later also. All eyes except one (92.3%) could be salvaged. The mean BCVA at the time of presentation

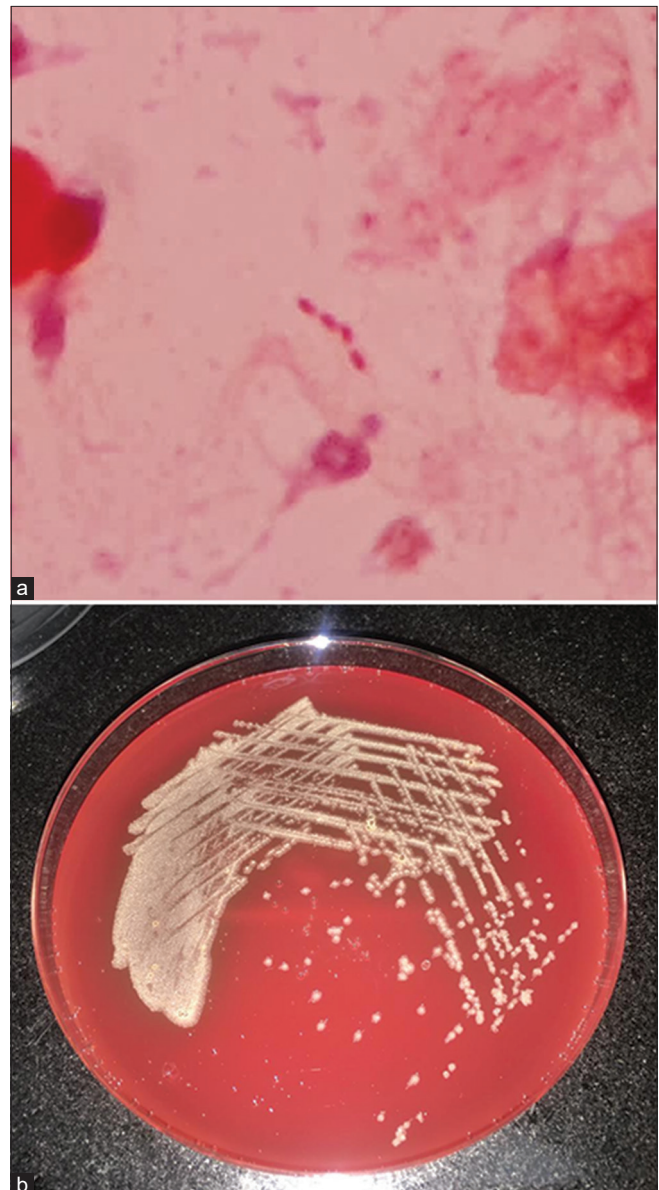


Figure 4: Microbiology examination. (a) Microscopic examination showing presence of Gram-negative bacilli. (b) Culture growth of *Pseudomonas stutzeri* on blood agar

Table 2: Literature review of previous reported cases of *Pseudomonas stutzeri* endophthalmitis and comparison with the present cluster

Authors	Year	No. of Cases	Initial surgery	Onset post-surgery	Presentation	Primary Intervention	Secondary Intervention	Outcome	Microbial Sensitivity	Microbial Resistance	Complications
Jirásková et al. ^[12]	1998	1	ECCE + IOL	11 days	Severe	Systemic + topical antibiotics	IOL explant + AV	Favorable	Tetracycline, gentamicin, amoxicillin, ofloxacin	Oxacillin, chloramphenicol, vancomycin, cefalotin	Recurrence
Lebowitz et al. ^[13]	2001	1	Trabeculectomy	7 years	Severe	Enucleation + orbital abscess drainage	-	Un-favorable	NR	NR	Panophthalmitis with orbital abscess
Shah et al. ^[14]	2020	1	ECCE + IOL	12 days	Severe	PPV + IOAB	IOAB x 2	Un-favorable	Gentamicin, ciprofloxacin, amikacin	Cefotaxime, ceftazidime, vancomycin	-
Alishahrani et al. ^[15]	2020	1	CLE + IOL	2 years	Severe	PPV + IOAB	Re-PPV + IOL Explant	Favorable	Ceftazidime, gentamicin	Vancomycin, ceftazoline	Recurrence
Present study	2021	14	PHACO + IOL	2 days	Mild x 10 Severe x 4	IOAB x 10 PPV + IOAB x 4	IOAB x 3 Re-PPV x 2	Favorable x 12 Un-favorable x 1 LAMA x 1	Amikacin ceftazidime, cefepime, piperacillin-tazobactam, imipenem, meropenem, gentamicin, levofloxacin, aztreonam, tobramycin	None	CRAO x 1 RD x 1

AV - Anterior vitrectomy, CLE - Clear lens extraction, CRAO - Central retinal artery occlusion, ECCE - Extracapsular cataract extraction, IOAB - Intraocular antibiotics, IOL - Intraocular lens, LAMA - Left against medical advice, NR - Not reported, PHACO - Phacoemulsification, PPV - Pars plana vitrectomy, RD - Retinal detachment

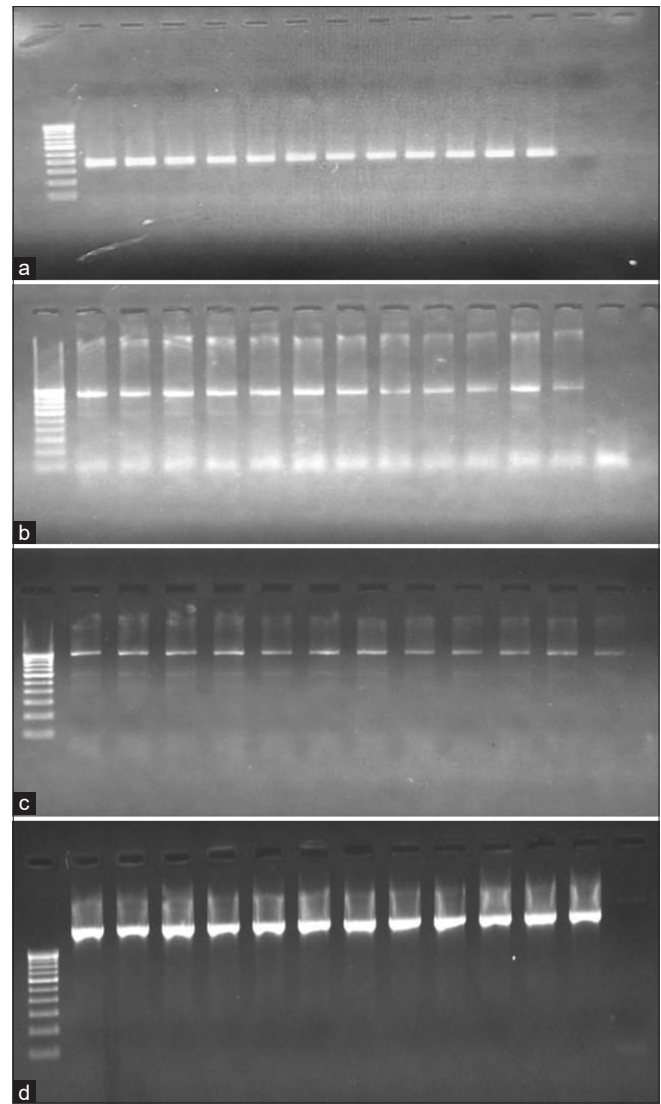


Figure 5: Gel pictures of PCR for *Pseudomonas stutzeri* with specific primers (a) 16s DNA (b) rpoD (c) gyrB (d) ITS 1 (1-12- isolates of *Pseudomonas stutzeri* obtained, NC- Negative control)

was logMAR 2.18 ± 0.85. The mean BCVA at last follow up improved to logMAR 0.71 ± 0.78. Eight patients (61.5%) improved to 20/40 or better. Three patients (23.1%), including one who developed retinal detachment, did not improve beyond 20/200.

Discussion

Pseudomonas stutzeri is an aerobic, Gram-negative bacterium. The organism is distributed in soil, manure, pond water, and sewage. It is widely prevalent in the hospital environment and is a rare opportunistic human pathogen. Isolation of this organism from ocular tissues is extremely rare and has been reported mainly in immunocompromised and elderly patients.^[17] In this study, we report the first ever cluster outbreak of *Pseudomonas stutzeri* acute endophthalmitis following cataract surgery with IOL implantation in a single surgeon setting. Majority of the cases presented with corneal folds, hypopyon, and fibrin on the IOL surface. Lid edema and pain were conspicuously absent. More than 70% of the

patients had some view of the fundus at presentation and all of them fared well with treatment. The patients with poor fundus visualization and severe presentation were mostly those associated with systemic comorbidities like DM. Even in this sub-group, only one patient lost vision while 75% had a favorable outcome.

Literature review identified only four isolated case reports of *Pseudomonas stutzeri* endophthalmitis following ocular surgery.^[12-15] The details of these cases and comparison with our cluster are presented in Table 2. Three of these cases occurred following IOL implantation while one was secondary to an infected trabeculectomy bleb. The earliest presentation was at 11 days following surgery whereas two cases occurred years after the initial surgical intervention. In contrast, all our cases showed signs of endophthalmitis only two days following the surgery, signifying acute presentation. We also identified one case with central retinal artery occlusion. All the previous reported cases had a severe presentation and 50% of them had an unfavorable outcome. In comparison, 71.4% of eyes had a mild presentation in our series and 92.3% of them could be salvaged.

Endophthalmitis secondary to *Pseudomonas* species are often associated with poor visual prognosis even with prompt initiation of treatment. Multi-drug resistance is also commonly found in these organisms.^[7-11] In our series, the early identification of the organism using the rapid MALDI-TOF MS technique and its rapid susceptibility using Vitek3 system played a major role in salvaging these eyes. We had the susceptibility results of the isolates within 24 hours, and this enabled the second batch of patients who presented the next day receiving only intravitreal ceftazidime as per the sensitivity profile. The organism identified in our series was sensitive to all the drugs tested and did not show any drug resistance. This could have been a major factor in the favorable outcome obtained in most of the cases. The infection caused by *P. stutzeri* is known to be more amenable to treatment than *P. aeruginosa* because of the superior antibiotic sensitivity profile.^[18]

Outbreaks of endophthalmitis occurring secondary to Gram-negative organisms are known to be exogenous in origin as these organisms are not normal commensals of conjunctiva or periocular skin. The various sources that have been identified as a source of outbreak are contaminated ophthalmic solutions like balanced salt solution, viscoelastic and trypan blue dye, internal tubing of phacoemulsification machine, phacoemulsification probe and irrigation aspiration cannulas.^[7-11] However, none of the surveillance sample obtained in our study showed any growth on incubation. It is important to note that the surveillance samples provided to us were after fumigation and we did not have free access to the operation theater as these surgeries were performed at a satellite center attached to a private hospital.

Conclusion

In conclusion, management of cluster endophthalmitis involves a multidisciplinary teamwork between the referring primary surgeon, the treating ophthalmologist, and the microbiologist. Prompt identification of the causative organism and its sensitivity to available antibiotics aids the treatment. Our study provides insights into the clinical profile and outcomes in cluster endophthalmitis secondary to *Pseudomonas stutzeri*—a lesser-known cause of intra-ocular infections. Majority of the

eyes had a mild presentation and could be salvaged with the prompt institution of treatment.

Financial support and sponsorship

Nil.

Conflicts of interest

There are no conflicts of interest.

References

- Kresloff MS, Castellarin AA, Zarbin MA. Endophthalmitis. *Surv Ophthalmol* 1998;43:193-224.
- Lalitha P, Sengupta S, Ravindran RD, Sharma S, Joseph J, Ambiya V, et al. A literature review and update on the incidence and microbiology spectrum of postcataract surgery endophthalmitis over past two decades in India. *Indian J Ophthalmol* 2017;65:673-7.
- Gupta A, Gupta V, Gupta A, Dogra MR, Pandav SS, Ray P, et al. Spectrum and clinical profile of post cataract surgery endophthalmitis in north India. *Indian J Ophthalmol* 2003;51:139-45.
- Endophthalmitis Vitrectomy Study Group. Results of the endophthalmitis vitrectomy study: A randomized trial of immediate vitrectomy and of intravenous antibiotics for the treatment of postoperative bacterial endophthalmitis. *Arch Ophthalmol* 1995;113:1479-96.
- Aaberg TM, Flynn HW, Schiffman J, Newton J. Nosocomial acute-onset postoperative endophthalmitis survey: A 10-year review of incidence and outcomes. *Ophthalmology* 1998;105:1004-10.
- Eifrig CW, Scott IU, Flynn HW, Miller D. Endophthalmitis caused by *Pseudomonas aeruginosa*. *Ophthalmology* 2003;110:1714-7.
- Parchand SM, Agrawal D, Chatterjee S, Gangwe A, Mishra M, Agrawal D. Post-cataract surgery cluster endophthalmitis due to multidrug-resistant *Pseudomonas aeruginosa*: A retrospective cohort study of six clusters. *Indian J Ophthalmol* 2020;68:1424-31.
- Zaluski S, Clayman HM, Karsenti G, Bourzeix S, Tournemire A, Faliu B, et al. *Pseudomonas aeruginosa* endophthalmitis caused by contamination of the internal fluid pathways of a phacoemulsifier. *J Cataract Refract Surg* 1999;25:540-5.
- Hoffmann KK, Weber DJ, Gergen MF, Rutala WA, Tate G. *Pseudomonas aeruginosa*-related postoperative endophthalmitis linked to a contaminated phacoemulsifier. *Arch Ophthalmol* 2002;120:90-3.
- Mateos I, Valencia R, Torres MJ, Cantos A, Conde M, Aznar J. Nosocomial outbreak of *Pseudomonas aeruginosa* endophthalmitis. *Infect Control Hosp Epidemiol* 2006;27:1249-51.
- Pinna A, Usai D, Sechi LA, Zanetti S, Jesudasan NC, Thomas PA, et al. An outbreak of post-cataract surgery endophthalmitis caused by *Pseudomonas aeruginosa*. *Ophthalmology* 2009;116:2321-6.
- Jirásková N, Rozsival P. Delayed-onset *Pseudomonas stutzeri* endophthalmitis after uncomplicated cataract surgery. *J Cataract Refract Surg* 1998;24:866-7.
- Lebowitz D, Gürses-Ozden R, Rothman RF, Liebmann JM, Tello C, Ritch R. Late-onset bleb-related panophthalmitis with orbital abscess caused by *Pseudomonas stutzeri*. *Arch Ophthalmol* 2001;119:1723-5.
- Shah A, Senger D, Garg B, Mishra S, Goel S, Saurabh K, et al. Post cataract *Pseudomonas stutzeri* endophthalmitis: Report of a case and review of literature. *Indian J Ophthalmol* 2020;68:232-3.
- Alshahrani ST, Arevalo JF. Chronic endophthalmitis caused by *Pseudomonas stutzeri*. *Case Rep Ophthalmol* 2020;11:595-9.
- Cladera AM, Bannasar A, Barceló M, Lalucat J, García-Valdés E. Comparative genetic diversity of *Pseudomonas stutzeri* genomovars, clonal structure, and phylogeny of the species. *J Bacteriol* 2004;186:5239-48.
- Holmes B. Identification and distribution of *Pseudomonas stutzeri* in clinical material. *J Appl Bacteriol* 1986;60:401-11.
- Dhd Lalucat J, Bannasar A, Bosch R, Gracia-Valdes E, Palleroni NJ. Biology of *Pseudomonas stutzeri*. *Microbiol Mol Biol Rev* 2006;70:510-47.