

## Role of Diffusion Tensor Imaging in Brain Tumor Surgery

### Abstract

**Object:** The objective is to evaluate the role of diffusion tensor imaging (DTI) in intra-axial brain tumor cases (gliomas and metastasis). To preoperatively assess the integrity and location of white matter (WM) tracts and plan the surgical corridor to cause least damage to the WM tracts with minimum postoperative new neurological deficits. **Materials and Methods:** A total of 34 patients were included in this study. Pre-operative contrast-enhanced magnetic resonance imaging and DTI scans of the patients were taken into consideration. Pre- and post-operative neurological examinations were performed and the outcome was assessed. **Results:** Preoperative planning of surgical corridor and extent of resection were planned so that maximum possible resection could be achieved without disturbing the WM tracts. DTI indicated the involvement of fiber tracts. A total of 21 (61.7%) patients had a displacement of tracts only and they were not invaded by tumor. A total of 11 (32.3%) patients had an invasion of tracts by the tumor, whereas in 4 (11.7%) patients the tracts were disrupted. Postoperative neurologic examination revealed deterioration of motor power in 4 (11.7%) patients, deterioration of language function in 3 (8.82%) patients, and memory in one patient. Total resection was achieved in 11/18 (61.1%) patients who had displacement of fibers, whereas it was achieved in 5/16 (31.2%) patients when there was infiltration/disruption of tracts. **Conclusion:** DTI provides crucial information regarding the infiltration of the tract and their displaced course due to the tumor. This study indicates that it is a very important tool for the preoperative planning of surgery. The involvement of WM tracts is a strong predictor of the surgical outcome.

**Keywords:** Diffusion tensor image, intra-axial brain tumor, magnetic resonance image, tractography, white matter tracts

### Introduction

Intra-axial tumors of the brain are one of the most common tumors to be encountered by neurosurgeons.<sup>[1]</sup> These tumors are frequently located in or close to eloquent areas, including motor and language areas. Surgical resection of such tumors often injures these tracts and produces severe neurologic complications.<sup>[2]</sup> Preoperative knowledge of relationship of tumor with the tract is of vital importance.

Diffusion tensor imaging (DTI) is a noninvasive magnetic resonance imaging (MRI) modality which depicts the probable location and orientation of subcortical white matter (WM) tracts *in vivo*.<sup>[3]</sup> DTI guides the surgeon regarding the relationship of the intra-axial tumor to local WM tracts in multiple planes. A variety of aspects of the tumor–tract relationship can, therefore, be revealed. The identity of the tract can be predicted from its position and course, such as

the corticospinal tract (CST) and optic radiations, and proximity of the tumor to the tract can be appreciated. Furthermore, the position of the tumor can be seen in relation to the tract, for example, superior, lateral, medial, etc., allowing the optimal approach to be determined for highly eloquent and complex areas.<sup>[3-5]</sup> Displacement of the tract by the tumor or perilesional edema can also be demonstrated.<sup>[6,7]</sup> This is crucial information when planning a surgical trajectory to avoid damage to the eloquent tissue. Incorporation of WM fibers within the tumor mass, seen especially in low-grade tumors, and destruction of WM fibers by the high-grade tumor can also be depicted.<sup>[7-9]</sup> These features have profound implications for the extent of resection amenable for the individual tumor.

The aim of this study is to evaluate the role of DTI in preoperative assessment of intra-axial brain tumors and planning of the surgical corridor to cause the least damage to the WM tracts causing least postoperative neurological deficits.

**Amitesh Dubey,  
Rashim Kataria,  
Virendra Deo Sinha**

*Department of Neurosurgery,  
SMS Medical College, Jaipur,  
Rajasthan, India*

### Address for correspondence:

*Dr. Amitesh Dubey,  
Department of Neurosurgery,  
SMS Medical College,  
Jaipur, Rajasthan, India.  
E-mail: amiteshdubey1@  
gmail.com*

### Access this article online

**Website:** www.asianjns.org

**DOI:** 10.4103/ajns.AJNS\_226\_16

### Quick Response Code:



**How to cite this article:** Dubey A, Kataria R, Sinha VD. Role of diffusion tensor imaging in brain tumor surgery. *Asian J Neurosurg* 2018;13:302-6.

This is an open access journal, and articles are distributed under the terms of the Creative Commons Attribution-NonCommercial-ShareAlike 4.0 License, which allows others to remix, tweak, and build upon the work non-commercially, as long as appropriate credit is given and the new creations are licensed under the identical terms.

**For reprints contact:** reprints@medknow.com

## Materials and Methods

### Patient population

This study was conducted at the Department of Neurosurgery, SMS Medical College, Jaipur, Rajasthan, India, after taking permission from the Ethical Committee of the Institution and written informed consent from the patients or their close relatives. No funds or scholarship was provided from the institute. A total of 34 patients operated for intra-axial supratentorial brain tumors who underwent surgery in our department were included in this prospective study.

Preoperative detailed history and neurological examinations of patients were performed. A baseline MRI brain was obtained from all the patients. T1- and T2-weighted images were taken and additional sequences such as fluid attenuation inversion recovery, diffusion-weighted imaging, and apparent diffusion coefficient sequences were obtained. Postcontrast T1W fat-saturated sequences were also obtained. DTI was then performed for preoperative planning of surgery. The surgery was then performed according to the MRI and DTI information obtained. Detailed postoperative neurological examination was performed.

### Magnetic resonance imaging protocol

The magnetic resonance (MR) examinations were performed at a 3T MR system (Philips 3T-Ingenuia; Philips medical system) using an eight-element phased array sensitivity encoding head coil.

DTI was performed using a single-shot spin-echo echo-planar-imaging pulse sequence with a diffusion sensitization ( $b = 1000$  seconds/mm<sup>2</sup>), TR 3000 ms, TE 94 ms, slice thickness between 2.5 mm, no gap between slices, matrix  $\times 92 \times 88$ , flip angle 90°. DTI measurements are obtained using either ROI analysis or tractography. The CST and some of the major subcortical tracts involved in the phonologic or semantic loop of language – superior longitudinal fascicle and inferior fronto-occipital were reconstructed, defining for each tract separately, the regions of interest (ROIs) around areas of the WM that all the fibers of each tract must pass through to reach their cortical or subcortical endstations.

### Diffusion tensor imaging tractography

Images were analyzed using DTI Studio, obtaining main eigenvector, and fractional anisotropy (FA) maps. From their combination, color maps were generated with conventional color-coding. Deterministic tractography was performed in all patients to reconstruct subcortical connections using the fiber assignment by the continuous tracking method. An FA threshold of 0.1 and a turning angle 55.8 were used as criteria to start and stop tracking. The CST and some of the major subcortical tracts were reconstructed, defining for each tract separately regions

of interest (ROIs) around areas of WM that all the fibers of each tract must pass through to reach their cortical or subcortical end stations. DTI tractography images were systematically reviewed. Tracts were then classified as Displaced, Infiltrated, and Disrupted. Displaced: if the tract showed normal or only slightly decreased FA, with abnormal location and/or direction, resulting from bulk mass displacement. Infiltrated: if the tract showed reduced anisotropy but remained identifiable on color maps. Disrupted: if the tract showed isotropic (or near-isotropic) diffusion, such that it could not be identified on directional color maps.

The entire data were then reviewed by the senior faculty of neurosurgery. With the assistance of the information provided by MRI, DTI, and fiber tractography, we knew the relationship between the lesion and important fiber tracts. Individualized surgical approaches were designed according to the information provided by the DTI and conventional MRI and the surgery was then performed accordingly.

Postoperative detailed neurological examination and imaging were performed to look for the extent of resection and any surgical complication and neurological outcome.

## Results

Of the total 34 patients, 21 (61.7%) were male and 13 (38.2%) were female [Table 1]. Age of the patients ranged from 17 to 70 years with the mean age of 48.3 years. Preoperative neurologic examination revealed motor weakness in 18 (52.9%) patients, language disorder in 3 (8.82%) patients, and 2 (5.88%) patients presented with urinary incontinence. Twelve patients (35.2%) had seizure and 5 (14.7%) patients had memory impairment while cognitive impairment was present in 15 (44.1%) patients.

Contrast-enhanced MRI study revealed 19 (55.8%) patients with left-sided lesions and 12 (35.2%) patients with right-sided lesions. Five (14.7) patients had bilateral lesions. Sixteen (47.0%) of these lesions were present in the frontal lobe, 6 (17.6%) were present in the parietal lobe, and 3 (8.82%) were present in the temporal lobe. Involvement of more than one lobe was present in 11 (32.3%) patients. DTI showed the involvement of fiber tracts with a displacement of tracts in almost every patient [Table 2].

Preoperative planning of surgical corridor and extent of resection were planned so that maximum possible resection can be achieved without disturbing the WM tracts and causing minimum possible postoperative morbidity. Gross total resection was achieved in 16 (47%) patients, whereas rest had near total or subtotal resection [Table 3]. There was no mortality in the control group. Postoperative neurologic examination revealed deterioration of motor power in 4 (11.7%) patients, there was deterioration of MRC Grade 1 (in three) or 2 (in one) and none of the

**Table 1: Patient's data**

Characteristic	Total number of patients (n=34)	Number of cases (%)
Sex	Male	21 (61.7)
	Female	13 (38.2)
Side	Right	12 (35.2)
	Left	19 (55.8)
Site	Bilateral (corpus callosum mass)	5 (14.7)
	Frontal	16 (47.0)
	Parietal	6 (17.6)
	Temporal	3 (8.82)
Grade of tumor	More than one lobe	11 (32.3)
	Low-grade glioma	12 (35.2)
	High-grade glioma	17 (50.0)
Preoperative neurological examination	Metastasis	5 (14.7)
	Motor weakness	18 (52.9)
	Language disorder	3 (8.82)
	Urine incontinence	2 (5.88)
	Seizure	12 (35.2)
	Memory impairment	5 (14.7)
DTI	Cognitive defect	15 (44.1)
	Displaced only	18 (52.9)
	Invaded	11 (32.3)
	Disrupted	5 (11.7)
Postoperative neurological examination	Power deterioration	4 (11.7)
	Power improvement	5 (14.7)
	Language function deterioration	3 (8.82)
	Language function improvement	1 (2.94)
	Seizure (postoperative)	2 (5.88)
	Memory impairment	6 (17.6)
	Cognitive defect	16 (47.0)

DTI – Diffusion tensor imaging

**Table 2: Displacement and infiltration/disruption of tracts associated with grade of tumor**

	Displacement of WM tracts (n=18) (%)	Infiltration/disruption of tracts (n=16) (%)
High-grade glioma	5 (29.4)	12 (70.5)
Low-grade glioma	9 (75.0)	3 (25.0)
Metastasis	4 (80.0)	1 (20.0)

WM – White matter

**Table 3: Displacement and infiltration/disruption of tracts associated with resection of tumor**

	Displacement of tracts (n=18) (%)	Infiltration/disruption of tracts (n=16) (%)
Total resection	11 (61.1)	5 (31.2)
Subtotal resection	7 (38.8)	11 (68.7)

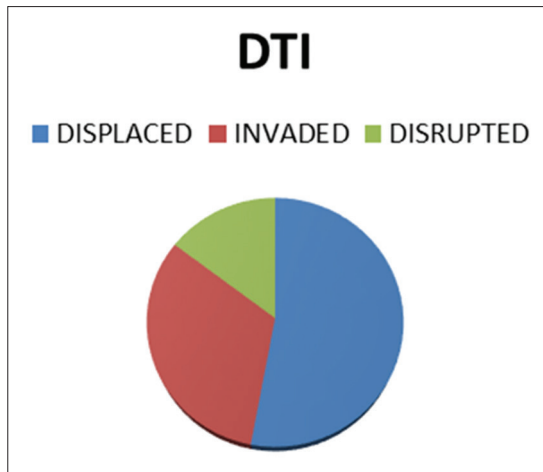
patients had dense hemiplegia, whereas 5 (14.7) patients had improvement in power. There were deterioration of language function in 3 (8.82%) patients and memory in one patient. Cognitive defect was present in 16 (47%) patients. Postoperative seizures occurred in 2 (5.88%) patients.

## Discussion

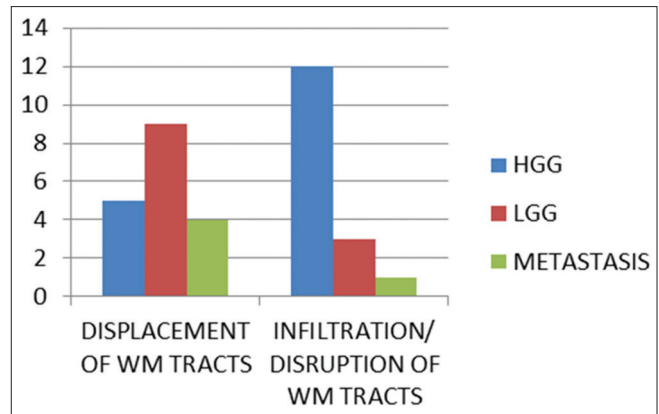
Neurosurgery for brain tumors is a trade-off between maximum surgical resection on the one hand and maximum sparing of functions on the other hand. Gross total resection of the tumor reduces the risk of relapse and allow subsequent radiotherapy or chemotherapy to be more effective.<sup>[10-13]</sup> On the other hand, sparing functionally relevant zones and therefore, preservation of motor, visual, or language functions significantly improves the quality of life of these patients.<sup>[14,15]</sup> For realizing these goals, many imaging modalities were used to assess brain tumors, which include conventional MRI, positron emission tomography, and functional MRI (fMRI).<sup>[16]</sup> Knowledge of the structural integrity and location of certain WM tracts with respect to an intracranial lesion is crucial for neurosurgical planning for defining the surgical access point and identifying the eloquent areas of the brain and the extent of tumor resection.<sup>[17]</sup> DTI is a significant advancement in the field of diagnostic imaging. It is, in fact, the only method capable of displaying cerebral WM tracts *in vivo*, and it has been shown that this knowledge assists the neurosurgeon in preoperative planning.<sup>[18,19]</sup>

The most significant use of DTI, in intracranial tumors is to preoperatively confirm the integrity and location of displaced WM tracts.<sup>[20]</sup> WM tracts may be pathologically altered by the tumor in several ways. They may be displaced, infiltrated by tumor and/or edema, or destroyed. Unfortunately, these alterations are not exclusive in a given tumor or even in a given WM tract.<sup>[21]</sup> In comparison with conventional MRI techniques which provide only anatomical information, DTI offers data on the central nervous system connectivity by enabling visualization of crucial WM tracts in the brain and provide guidance on resection operation.<sup>[22,23]</sup> Kleiser *et al.* found that DTI results were more accurate than those using anatomical landmarks alone, in which fMRI results were used to localize start points for DTI tract reconstruction.<sup>[24]</sup> Furthermore, in the previous studies of Romano *et al.*, they found that the utilization of DTI/fMRI in corticotomy led to a change of the surgical approach for resection in 16%–21% of cases.<sup>[16,25]</sup> More recent studies by Cao *et al.* found that in their retrospective analysis, preoperative planning using DTI enabled the surgeon to investigate individual patient specific surgical approach and can significantly improve the surgical outcome, they have also concluded in their study that preoperative planning using DTI improves neurologic outcome in patients with brainstem lesions.<sup>[26]</sup> Preoperative estimation of damage was shown to be possible using fMRI/DTI data in a recent study.<sup>[27]</sup> A study by Castellano *et al.* showed that the extent of resection and thus, prognosis can be predicted by DTI. In their study, tumors that were infiltrating the WM tracts were less likely to be resected completely in comparison to tumors in which WM tracts were intact.<sup>[28]</sup>





Graph 1: Involvement of the white matter tracts in our study



Graph 2: Displacement and infiltration/disruption of the white matter tracts associated with grade of the tumor

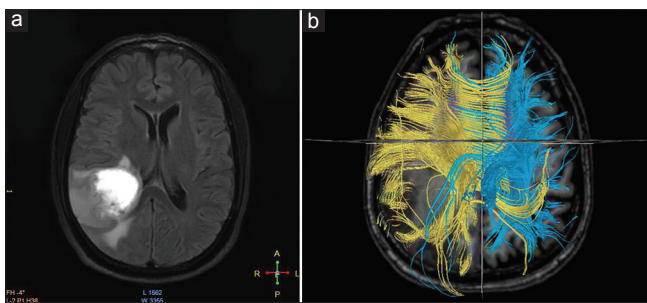


Figure 1: (a) A 52-year-old male patient presented with left-sided weakness and headache. Magnetic resonance imaging shows the right parietal mass. Total resection of tumor was performed. Postoperatively, patient has improvement in power. (b) Diffusion tensor imaging shows displacement of the white matter tracts

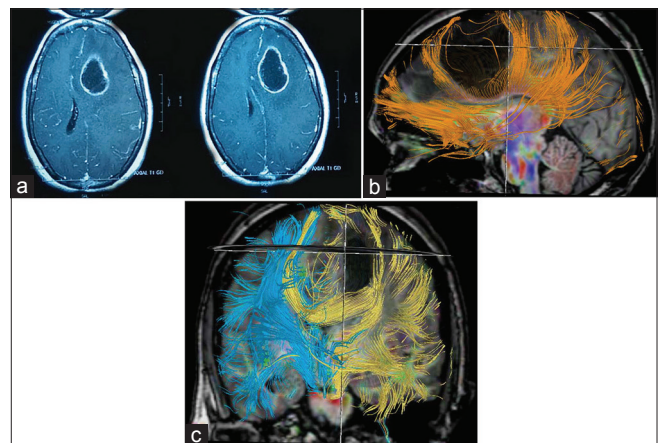


Figure 2: (a) A 50-year-old female patient presented with a headache, language disorder, and cognitive impairment. Magnetic resonance imaging showed the presence of left frontal high-grade gliomas. Diffusion tensor imaging showed displacement of the tracts. Postoperatively, patients show improvement in language and cognitive function. (b) Diffusion tensor imaging (sagittal) showed displacement of tracts. (c) Diffusion tensor imaging (coronal) showed displacement of tracts

This prospective study analyzed the impact of DTI tractography in preoperative planning and predicting surgical outcome in patients with intra-axial brain tumors. In our study, as in previous studies, we have classified the WM tract involvement as displaced, infiltrated, and disrupted based on the direction of fibers and their FA values [Graph 1]. In the previous studies, it was shown that high-grade gliomas are significantly associated with infiltration or displacement of tracts. In our study also similar trend was seen [Table 2 and Graph 2]. In our study also, as in the previous study, the extent of resection was related to the involvement of tracts with complete resection was mostly achieved when WM tracts are displaced only [Figures 1 and 2].

Reconstruction and interpretation of DTI tractography data in a presurgical setting have some drawbacks, mainly related to the differentiation between the lowering of anisotropy value because of a real neoplastic infiltration or to the peritumoral edema.<sup>[9]</sup> The inability of DTI tractography to resolve WM architecture where more than one fiber population occupies the same voxel affects the reliability of tracking mainly in regions that contain multiple crossing WM pathways.<sup>[29,30]</sup> The recent development of advanced high angular resolution diffusion imaging techniques and q-ball reconstruction methods can

provide a more accurate presurgical tractography.<sup>[22]</sup> This preliminary study including a large series of intra-axial brain tumors demonstrates that the assessment of WM involvement is an essential part of an integrate presurgical evaluation because the analysis of the relationship between tumor and eloquent bundles by DTI tractography allows to preoperatively plan the surgical approach and the degree of surgical resection and preservation maximum possible neurological function.

### Conclusion

DTI is a newer modality which shows the WM tracts and its relation to the tumor *in vivo*. It provides crucial information about the involvement of the tract and its displaced course due to the tumor. This study has shown that it can be a very important tool for the preoperative planning of surgery. The involvement of fascicles is a strong predictor of the surgical outcome because the probability of achieving a total resection is higher when

fascicles are intact; conversely, the expected probability of total resection is substantially lower in the cases in which tractography showed infiltrated or displaced WM tracts. This information could be of extremely useful prognostic value, and once integrated with the patient's anesthesiological, neurological, and neuropsychological evaluation, it could be proposed as a useful tool to help in surgical decision making.

### Financial support and sponsorship

Nil.

### Conflicts of interest

There are no conflicts of interest.

### References

- Dolecek TA, Propp JM, Stroup NE, Kruchko C. CBTRUS statistical report: Primary brain and central nervous system tumors diagnosed in the United States in 2005-2009. *Neuro Oncol* 2012;14 Suppl 5:v1-49.
- Giese A, Westphal M. Glioma invasion in the central nervous system. *Neurosurgery* 1996;39:235-50.
- Chanraud S, Zahr N, Sullivan EV, Pfefferbaum A. MR diffusion tensor imaging: A window into white matter integrity of the working brain. *Neuropsychol Rev* 2010;20:209-25.
- Provenzale JM, Mukundan S, Barboriak DP. Diffusion-weighted and perfusion MR imaging for brain tumor characterization and assessment of treatment response. *Radiology* 2006;239:632-49.
- Karimi S, Nicole M, Kyang K. Advanced MR techniques in brain tumor imaging. *Appl Radiol* 2006;35:9-18.
- Sinha S, Bastin ME, Whittle IR, Wardlaw JM. Diffusion tensor MR imaging of high-grade cerebral gliomas. *AJNR Am J Neuroradiol* 2002;23:520-7.
- Jellison BJ, Field AS, Medow J, Lazar M, Salamat MS, Alexander AL. Diffusion tensor imaging of cerebral white matter: A pictorial review of physics, fiber tract anatomy, and tumor imaging patterns. *AJNR Am J Neuroradiol* 2004;25:356-69.
- Witwer BP, Moftakhar R, Hasan KM, Deshmukh P, Houghton V, Field A, *et al.* Diffusion-tensor imaging of white matter tracts in patients with cerebral neoplasm. *J Neurosurg* 2002;97:568-75.
- Bello L, Gambini A, Castellano A, Carrabba G, Acerbi F, Fava E, *et al.* Motor and language DTI Fiber Tracking combined with intraoperative subcortical mapping for surgical removal of gliomas. *Neuroimage* 2008;39:369-82.
- Smith JS, Chang EF, Lamborn KR, Chang SM, Prados MD, Cha S, *et al.* Role of extent of resection in the long-term outcome of low-grade hemispheric gliomas. *J Clin Oncol* 2008;26:1338-45.
- Stummer W, Reulen HJ, Meinel T, Pichlmeier U, Schumacher W, Tonn JC, *et al.* Extent of resection and survival in glioblastoma multiforme: Identification of and adjustment for bias. *Neurosurgery* 2008;62:564-76.
- Sanai N, Berger MS. Glioma extent of resection and its impact on patient outcome. *Neurosurgery* 2008;62:753-64.
- Berger MS, Rostomily RC. Low grade gliomas: Functional mapping resection strategies, extent of resection, and outcome. *J Neurooncol* 1997;34:85-101.
- Talos IF, Zou KH, Ohno-Machado L, Bhagwat JG, Kikinis R, Black PM, *et al.* Supratentorial low-grade glioma resectability: Statistical predictive analysis based on anatomic MR features and tumor characteristics. *Radiology* 2006;239:506-13.
- Mandonnet E, Jbabdi S, Taillandier L, Galanaud D, Benali H, Capelle L, *et al.* Preoperative estimation of residual volume for WHO grade II glioma resected with intraoperative functional mapping. *Neuro Oncol* 2007;9:63-9.
- Romano A, Ferrante M, Cipriani V, Fasoli F, Ferrante L, D'Andrea G, *et al.* Role of magnetic resonance tractography in the preoperative planning and intraoperative assessment of patients with intra-axial brain tumours. *Radiol Med* 2007;112:906-20.
- Fujiwara N, Sakatani K, Katayama Y, Murata Y, Hoshino T, Fukaya C, *et al.* Evoked-cerebral blood oxygenation changes in false-negative activations in BOLD contrast functional MRI of patients with brain tumors. *Neuroimage* 2004;21:1464-71.
- Yu CS, Li KC, Xuan Y, Ji XM, Qin W. Diffusion tensor tractography in patients with cerebral tumors: A helpful technique for neurosurgical planning and postoperative assessment. *Eur J Radiol* 2005;56:197-204.
- Basser PJ, Pajevic S, Pierpaoli C, Duda J, Aldroubi A. *In vivo* fiber tractography using DT-MRI data. *Magn Reson Med* 2000;44:625-32.
- Helton KJ, Phillips NS, Khan RB, Boop FA, Sanford RA, Zou P, *et al.* Diffusion tensor imaging of tract involvement in children with pontine tumors. *AJNR Am J Neuroradiol* 2006;27:786-93.
- Field AS, Alexander AL, Wu YC, Hasan KM, Witwer B, Badie B. Diffusion tensor eigenvector directional color imaging patterns in the evaluation of cerebral white matter tracts altered by tumor. *J Magn Reson Imaging* 2004;20:555-62.
- Berman J. Diffusion MR tractography as a tool for surgical planning. *Magn Reson Imaging Clin N Am* 2009;17:205-14.
- Arfanakis K, Gui M, Lazar M. Optimization of white matter tractography for pre-surgical planning and image-guided surgery. *Oncol Rep* 2006;15:1061-4.
- Kleiser R, Staempfli P, Valavanis A, Boesiger P, Kollias S. Impact of fMRI-guided advanced DTI fiber tracking techniques on their clinical applications in patients with brain tumors. *Neuroradiology* 2010;52:37-46.
- Romano A, D'Andrea G, Minniti G, Mastronardi L, Ferrante L, Fantozzi LM, *et al.* Pre-surgical planning and MR-tractography utility in brain tumour resection. *Eur Radiol* 2009;19:2798-808.
- Cao Z, Lv J, Wei X, Quan W. Appliance of preoperative diffusion tensor imaging and fiber tractography in patients with brainstem lesions. *Neurol India* 2010;58:886-90.
- Fernandez-Miranda JC, Engh JA, Pathak SK, Madhok R, Boada FE, Schneider W, *et al.* High-definition fiber tracking guidance for intraparenchymal endoscopic port surgery. *J Neurosurg* 2010;113:990-9.
- Castellano A, Bello L, Michelozzi C, Gallucci M, Fava E, Iadanza A, *et al.* Role of diffusion tensor magnetic resonance tractography in predicting the extent of resection in glioma surgery. *Neuro Oncol* 2012;14:192-202.
- Jones DK. Determining and visualizing uncertainty in estimates of fiber orientation from diffusion tensor MRI. *Magn Reson Med* 2003;49:7-12.
- Pierpaoli C, Jezzard P, Basser PJ, Barnett A, Di Chiro G. Diffusion tensor MR imaging of the human brain. *Radiology* 1996;201:637-48.