

**CASE REPORT**

# Preservation of Residual Limb Length with Antibiotic-loaded Bone Cement Implantation to Treat Femoral Periprosthetic Infection: A Case Report

Natsuko Fukuoka, MD, PhD Yoshio Kaji, MD, PhD Shin Morita, RPT Yoshiki Yamagami, MD, PhD Hideki Nishimura, MD, PhD and Tetsuji Yamamoto MD, PhD

**Background:** Fitting a femoral prosthesis in a transfemoral amputee with a very short amputation stump is challenging. This case report aimed to introduce an effective and simple method that can preserve the residual limb length by the implantation of antibiotic-loaded bone cement for the treatment of a patient with femoral periprosthetic infection. **Case:** A 30-year-old man who had osteosarcoma at the age of 13 years underwent transfemoral amputation 17 years after the initial surgery because of periprosthetic infection. Antibiotic-loaded bone cement was inserted into the infected bone marrow to control the residual infection and to preserve the stump length. The infection resolved, and the patient regained functional gait using a femoral prosthesis. **Discussion:** This case report demonstrates the usefulness of antibiotic-loaded cement in preserving the length of residual limbs and for femoral prosthesis fitting after periprosthetic infection. Maintaining the residual bone length is crucial in amputees for the functional fitting of femoral prostheses. The use of antibiotic-loaded bone cement has potential as a simple and useful surgical option in amputees after periprosthetic infection.

**Key Words:** amputation; bone tumor; prosthesis fitting

## INTRODUCTION

Limb amputation has been superseded by limb salvage surgery in the treatment of primary malignant bone tumors. Moreover, improvements in the materials and designs of prostheses have made endoprosthetic replacement (EPR) the mainstay of reconstruction after tumor resection. However, periprosthetic infections can be devastating and may necessitate limb amputation. Indeed, transfemoral amputation is often performed because of femoral periprosthetic infection. If the length of the femur is decreased markedly as a result of amputation, it can be very challenging to fit a femoral prosthesis to the amputation stump.<sup>1)</sup> To solve this problem, several methods, such as bone lengthening and the use of a metal prosthesis, have been introduced to lengthen

the residual limb. However, most of these methods require complicated surgical techniques.

This case report aimed to introduce a simple and effective method for preserving the length of the residual limb by using antibiotic-loaded bone cement implantation in the treatment of femoral periprosthetic infection.

## CASE

A 30-year-old man with a history of osteosarcoma of the distal left femur underwent wide resection of the tumor and endoprosthetic replacement (EPR) when he was 13 years old. Seventeen years after the surgery, he presented to our hospital with swelling of his left lower limb and fever (39°C). At the time of admission, the laboratory results showed an

Received: May 24, 2021, Accepted: August 4, 2021, Published online: September 2, 2021

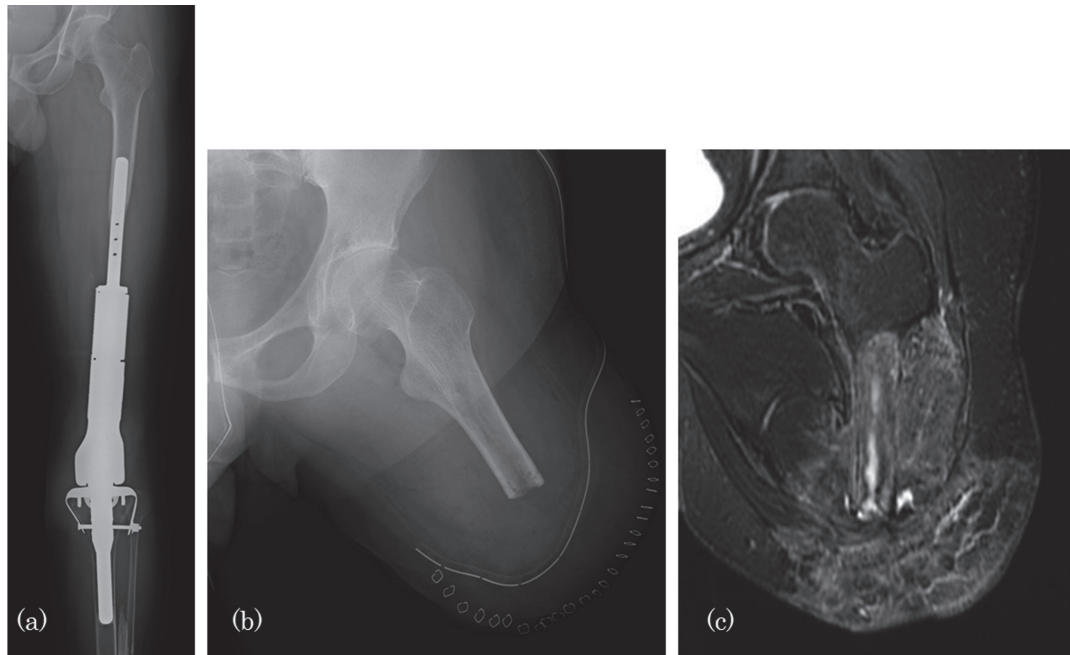
Department of Orthopedic Surgery, Kagawa University, Kagawa, Japan

Correspondence: Natsuko Fukuoka, MD, PhD, Department of Orthopedic Surgery, Kagawa University Faculty of Medicine, 1750-1 Ikenobe, Miki-cho, Kita-gun, Kagawa 761-0793, Japan, Email address: [n-iida@med.kagawa-u.ac.jp](mailto:n-iida@med.kagawa-u.ac.jp)

Copyright © 2021 The Japanese Association of Rehabilitation Medicine



This is an open-access article distributed under the terms of the Creative Commons Attribution Non-Commercial No Derivatives (CC BY-NC-ND) 4.0 License. <http://creativecommons.org/licenses/by-nc-nd/4.0/>



**Fig. 1.** (a) Preoperative anteroposterior radiograph. Osteolytic changes are seen around the implant. (b) Postoperative radiograph of the transfemoral amputation site. The functional stump length (from the inferior edge of the ischium to the bone stump) was 6 cm. (c) Magnetic resonance imaging obtained 52 days after the amputation surgery revealed subcutaneous abscess and osteomyelitis of the residual femur.

elevated white blood cell count (12,060 cells/mm<sup>3</sup>) and C-reactive protein (CRP) concentration (39.67 mg/dL).

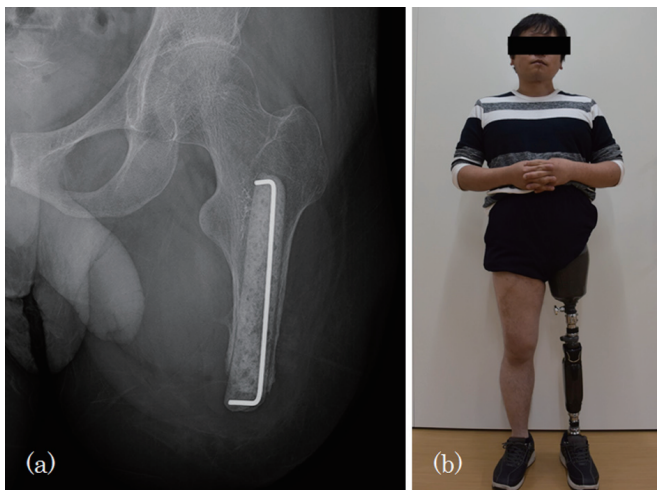
Radiography showed osteolytic changes around the implant (**Fig. 1a**). Contrast-enhanced computed tomography revealed a ring-enhancing lesion around the femur and increased fluid in the knee joint. Methicillin-susceptible *Staphylococcus aureus* (MSSA) was isolated following diagnostic aspiration of the fluid collected in the left knee joint.

Based on these findings, periprosthetic infection was suspected and conservative treatment using intravenous antibiotics was initiated. However, the conservative treatment was ineffective, and transfemoral amputation was performed 6 days after admission. Before the amputation, we explained to the patient the options of limb preservation or femoral amputation, as well as the advantages and disadvantages of each treatment method. After the explanation, the patient opted for transfemoral amputation to enable him to return to work as soon as possible and because he was concerned about a future recurrence of the infection in the limb if it was preserved.

At the time of surgery, the infected femur was osteotomized at the level of the proximal edge of the implant. As a result, the functional stump length (from the inferior edge of the lesser trochanter to the bone stump) was 6 cm (**Fig. 1b**).

After surgery, because MSSA was still present, treatment with cefazolin sodium 3 g/day was continued. Local inflammatory symptoms improved, but the swelling reappeared at the amputation stump after 52 days. Magnetic resonance imaging revealed subcutaneous abscesses and osteomyelitis of the residual femur (**Fig. 1c**).

Excision of the abscess and curettage of the medullary cavity of the femur were performed to control the infection. Consequently, the cortex of the remaining part of the femur became thin, but further bone excision was avoided so that a femoral prosthesis could be fitted. Instead of additional bone excision, 40 g of bone cement (Surgical Simplex, Stryker, Kalamazoo, MI, USA) containing 2 g of vancomycin (vancomycin hydrochloride for intravenous infusion 0.5 g [MEEK], Meiji Seika Pharma Co., Ltd., Tokyo, Japan) was implanted into the medullary cavity of the residual femur to control infection and preserve bone length (**Fig. 2a**). After antibiotic-loaded cement implantation, anti-methicillin-resistant *S. aureus* drugs were selected and administered in consideration of resistant bacteria. Based on the results of an antibiotic susceptibility test using intraoperative samples, the treatment was switched to a combination of teicoplanin 400 mg/day and minocycline hydrochloride 200 mg/day. However, suspected drug-induced hepatic dysfunction



**Fig. 2.** (a) Antibiotic-loaded cement implantation into the medullary cavity of the residual femur to control infection and preserve bone length. (b) Findings at 18 months after the last surgery. Functional gait was regained with the use of a femoral prosthesis.

occurred, and the treatment was changed to daptomycin 350 mg/day. Approximately 2 weeks postoperatively, the concentration of CRP decreased to within the normal range, and the recurrence of osteomyelitis was not observed throughout the follow-up period.

Postoperative rehabilitation was focused on the prevention of flexion–abduction contracture and the preservation of the range of motion of the hip joint on the affected side. Muscle strengthening training and gait training were also performed for the unaffected limb.

Two months after the last surgery, the patient started prosthetic gait training using a femoral prosthesis. Initially, we attempted to install a suction-type socket, but there was a problem with air leakage with the patient in the sitting posi-

tion. Therefore, by changing to a pin/lock system using an ischial-ramal containment socket, which is a silicone liner with a pin/lock system, it was possible to ensure the suspension of the prosthesis, even for the current short stump. Other parts of the prescribed prosthesis included a 4-bar hydraulic microprocessor-controlled stance, a swing phase-controlled knee, and a hydraulically controlled foot for the prosthetic limb (**Fig. 2b**). At the most recent follow-up (18 months after the last surgery), the ranges of motion of the hip joint were as follows: flexion, 45°; extension, 0°; abduction, 25°; and adduction, 5°. No stump pain was reported, and the patient could walk outdoors using a T-cane. His walking speed for 10 m was 1.30 m/s. Assessments of the patient's activities of daily living were as follows: the Barthel Index, 100 points, and the Functional Independence Measure, 124/126 points. As a measure of prosthetic leg quality of life (QOL), nine items (ambulation, appearance, frustration, perceived response, residual limb health, social burden, usefulness, satisfaction, and sound) were assessed using the Prosthesis Evaluation Questionnaire,<sup>2)</sup> Japanese version.<sup>3)</sup> This measure of prosthetic leg QOL has been shown to be valid. The current results were highly satisfactory (**Table 1**).

Written informed consent for the publication of this case report and the accompanying images was obtained from the patient.

## DISCUSSION

In this report, we describe the case of a 30-year-old man with a history of osteosarcoma who underwent transfemoral amputation. The report describes a simple and effective technique for the preservation of residual limb length, i.e., using vancomycin-loaded bone cement for the treatment of femoral periprosthetic infections.

Major late complications after EPR include loosening, the

**Table 1.** Results of Prosthesis Evaluation Questionnaire

	Subscale	Score (0–100)
Prosthetic function scales	Ambulation	87
	Usefulness	88.7
	Residual limb health	75.8
	Appearance	79.2
	Sounds	25
Psychosocial experiences	Perceived response	98.7
	Social burden	93.3
	Frustration	95
	Well-being	96.5

recurrence of primary disease, and infection. Among these, the most common cause of postoperative limb amputation is periprosthetic infection. The infection rate after general arthroplasty is 1–2%, whereas that after EPR for a primary bone tumor is 11–26%.<sup>4)</sup> The reasons for the high risk of infection include the extensive surgical exposure and lengthy operating times. Furthermore, postoperative chemotherapy increases the risk of surgical site infection. One of the biggest problems associated with limb amputation after EPR is the resulting short amputation stump. Because the EPR implant stem is very long, proximal amputation of the limb is inevitable if a postoperative periprosthetic infection occurs. For a lower limb amputee, if the amputation level is high, prosthetic gait requires a higher energy consumption than that for a lower limb amputee with a low amputation level. In particular, a hip prosthesis requires significantly higher walking energy than a femoral prosthesis. Further, the decrease in walking speed with the use of a hip prosthesis is greater than that of a femoral prosthesis.<sup>5–7)</sup> In contrast to the femoral prosthesis, which is easier to wear and enables functional walking, the hip prosthesis is associated with a decreased wear rate, and the success rate of rehabilitation is affected by the increased weight of the hip prosthesis and exhaust potential for users. Therefore, transfemoral amputation is preferred to avoid the use of a hip prosthesis.

In transfemoral amputation, achieving the longest possible residual limb length is critical to provide a suitable lever arm and to facilitate better gait ability. If the bone length below the lesser trochanter is less than 5 cm, a femoral prosthesis cannot be applied, and a hip prosthesis is usually prescribed. Kuiken *et al.* reported that wearing a femoral prosthesis becomes difficult when the stump length is less than 35% of the thigh length.<sup>8)</sup>

Despite the above-described considerations, several studies have reported the implantation of a metal prosthesis or bone lengthening procedures for extremely short transfemoral amputation stumps.<sup>9,10)</sup> Specifically, metal prosthesis implantation may be a good choice in patients without infections, such as those with bone tumor recurrence.<sup>9)</sup> However, if the requirement of amputation is based on the presence of infection, as in our case, it is difficult to use metal prostheses. Continuous local antibiotic perfusion (CLAP) is a minimally invasive method and a useful treatment for bone and soft tissue infections and may help to maintain the length of the amputation stump. However, in our patient, the bone needed sufficient strength to withstand the implementation of a femoral prosthesis. Furthermore, the cortex of the remaining part of the femur had become thin due to a recurrence

of infection after amputation. Therefore, it was considered that CLAP would be insufficient to treat the infection and maintain the bone strength of the stump.

Bone lengthening using external fixators is a good surgical option; however, it requires a longer treatment period and a cautious approach to prevent further infection.<sup>10)</sup> In the current patient, treatment was focused on providing a femoral prosthesis to achieve the earliest possible resumption of work. Consequently, the implantation of an antibiotic-loaded bone cement in the bone marrow was selected to control infection and preserve the stump length. The advantages of this method include the simple operative technique, elimination of the need for external fixators and metal implants, and simple postoperative management without the need for special care.<sup>11)</sup> Using this approach, the infection was well controlled, and the length of the residual limb was preserved.

A functional stump length of 6 cm is almost at the lower limit for a femoral prosthesis. Recently, materials for prosthetic sockets, such as silicon liners and polyurethane, have been developed to improve the lifting capacity of femoral prostheses.<sup>12)</sup> As a result, we considered that, despite the short stump length, the functional use of the femoral prosthesis was feasible. However, we experienced a few challenges. At the initiation of prosthetic gait training, a suction socket with a silicone liner was selected; however, air leakage developed with the patient in the sitting position, which disturbed gait training. Therefore, the socket was changed to a pin/lock system with a silicone liner, after which the patient could use the femoral prosthesis functionally.

We consider that the preservation of a longer stump might have been possible if antibiotic-loaded cement implantation was performed during the first amputation surgery. However, the durability of antibiotic-loaded cement is unknown. Therefore, careful long-term follow-up is necessary in this case.

Antibiotic-loaded cement implantation was performed for the treatment of osteomyelitis caused by periprosthetic infection. Using this technique, adequate residual limb length was preserved for the application of a femoral prosthesis, and functional gait was regained.

## CONFLICTS OF INTEREST

The authors declare that there are no conflicts of interest.

## REFERENCES

1. Penn-Barwell JG: Outcomes in lower limb amputation following trauma: a systematic review and meta-analysis. *Injury* 2011;42:1474–1479. DOI:10.1016/j.injury.2011.07.005, PMID:21831371
2. Legro MW, Reiber GD, Smith DG, del Aguila M, Larsen J, Boone D: Prosthesis evaluation questionnaire for persons with lower limb amputations: assessing prosthesis-related quality of life. *Arch Phys Med Rehabil* 1998;79:931–938. DOI:10.1016/S0003-9993(98)90090-9, PMID:9710165
3. Tobimatsu Y, *et al*: Reliability and validity of prosthesis evaluation questionnaire (PEQ) Japanese version. *SOGO Rehabil* 2004;32:77–82.
4. Grimer RJ, Aydin BK, Wafa H, Carter SR, Jeys L, Abudu A, Parry M: Very long-term outcomes after endoprosthetic replacement for malignant tumours of bone. *Bone Joint J* 2016;98-B:857–864. DOI:10.1302/0301-620X.98B6.37417, PMID:27235533
5. Chin T, Sawamura S, Shiba R, Oyabu H, Nagakura Y, Nakagawa A: Energy expenditure during walking in amputees after disarticulation of the hip. A microprocessor-controlled swing-phase control knee versus a mechanical-controlled stance-phase control knee. *J Bone Joint Surg Br* 2005;87-B:117–119. DOI:10.1302/0301-620X.87B1.14617, PMID:15686251
6. Nowroozi F, Salvanelli ML, Gerber LH: Energy expenditure in hip disarticulation and hemipelvectomy amputees. *Arch Phys Med Rehabil* 1983;64:300–303. PMID:6860105
7. Waters RL, Perry J, Antonelli D, Hislop H: Energy cost of walking of amputees: the influence of level of amputation. *J Bone Joint Surg Am* 1976;58:42–46. DOI:10.2106/00004623-197658010-00007, PMID:1249111
8. Kuiken TA, Butler BA, Sharkey T, Ivy AD, Li D, Peabody TD: Novel intramedullary device for lengthening transfemoral residual limbs. *J Orthop Surg Res* 2017;12:53. DOI:10.1186/s13018-017-0553-8, PMID:28359320
9. El Beaino M, Liu J, Lin PP: Modular endoprosthetic implant for maximizing residual limb length: a case report. *Prosthet Orthot Int* 2019;43:123–126. DOI:10.1177/0309364618805259, PMID:30319024
10. Savage Z, Munjal R: Multidisciplinary team approach to residual limb lengthening using the Ilizarov technique: a case study. *Prosthet Orthot Int* 2015;39:414–418. DOI:10.1177/0309364614531011, PMID:24812118
11. Booth R Jr, Lotke PA: The results of spacer block technique in revision of infected total knee arthroplasty. *Clin Orthop Relat Res* 1989;248:57–60. DOI:10.1097/00003086-198911000-00010, PMID:2805496
12. Zaffer SM, Braddom RL, Conti A, Goff J, Bokma D: Total hip disarticulation prosthesis with suction socket: report of two cases. *Am J Phys Med Rehabil* 1999;78:160–162. DOI:10.1097/00002060-199903000-00017, PMID:10088592