

Posterior longitudinal ligament suturation after lumbar discectomy provides postoperative a large intradural area: First report

ABSTRACT

Background: Stability and flexibility of the spine are provided by the posterior longitudinal ligament (PLL). It plays a key role in the pathogenesis of lumbar disc herniation (LDH) by preventing disc protrusion. The effect of the suturing of the PLL on the intradural area was investigated.

Patients and Methods: The patients were included in whom lumbar microdiscectomy was performed between January 2021 and July 1, 2022. The patients were randomly divided into two groups as PLLs were sutured and unsutured.

Results: Forty-six (23 males and 23 females) patients were included. The PLLs were sutured in 22 patients (Group 1) and not sutured in 24 patients (Group 2). The levels, sides of LDHs, and ages and gender of patients were also analyzed in both groups, which were not statistically significant. Preoperative mean spinal intradural areas were 77.29 mm² for the PLL unsutured group and 85.40 mm² for the PLL sutured group (Groups 1 and 2). For patients in Groups 1 and 2, the postoperative mean spinal intradural areas grew to 134.73 mm² and 96.12 mm², respectively. The difference in preoperative mean spinal intradural regions between the two groups was not statistically significant; however, Group 1 showed a substantial difference (sutured PLL patients).

Conclusions: This study first time indicates that suturing PLL has a protective and supportive role in patients who were operated on for LDH.

Keywords: Low back pain, lumbar disc herniation, posterior longitudinal ligament

INTRODUCTION

Lumbar disc herniation (LDH) is the most common cause of low back pain (LBP).^[1] LBP, which affects many people, is a significant public health issue.^[2,3] Lumbar discectomy is a frequently performed procedure to treat sciatica caused by LDH.^[4,5] Currently, neurosurgery has gone through moments of great renewal,^[6] and lumbar discectomy has been steadily changing. Discectomy provides rapid relief from radiculopathy pain; however, discectomy can occasionally result in persistent pain and recurrent herniation; approximately a third of patients are unhappy with the results of their surgeries,^[7] so unwanted outcomes after lumbar discectomy still occur, and lumbar discectomy procedure sometimes may discourage both surgeon and patient.^[8] In the practice of neurosurgery, we find that a wide number of patients referred for refractory LBP have a history of lumbar

discectomy.^[9] There are two questions for patients with LDHs: (1) Why some ruptured discs are painful, and others are not? (2) The reasons why some people have persistent

OSMAN ERSEGUN BATCIK, AYHAN KANAT, SERDAR DURMAZ¹, BULENT OZDEMIR, MEHMET BEYAZAL²

Departments of Neurosurgery and ²Radiology, Medical Faculty, Recep Tayyip Erdogan University, Rize, ¹Department of Neurosurgery, Aksaray Education and Training Hospital, Aksaray, Turkey

Address for correspondence: Prof. Dr. Ayhan Kanat, Department of Neurosurgery, Medical Faculty, Recep Tayyip Erdogan University, Rize, Turkey.
E-mail: ayhankanat@yahoo.com

Submitted: 03-Feb-23


Accepted: 14-Apr-23

Published: 13-Jun-23

This is an open access journal, and articles are distributed under the terms of the Creative Commons Attribution-NonCommercial-ShareAlike 4.0 License, which allows others to remix, tweak, and build upon the work non-commercially, as long as appropriate credit is given and the new creations are licensed under the identical terms.

For reprints contact: WKHLRPMedknow_reprints@wolterskluwer.com

How to cite this article: Batcik OE, Kanat A, Durmaz S, Ozdemir B, Beyazal M. Posterior longitudinal ligament suturation after lumbar discectomy provides postoperative a large intradural area: First report. *J Craniovert Jun Spine* 2023;14:181-6.

Access this article online	
Website: www.jcvjs.com	Quick Response Code 
DOI: 10.4103/jcvjs.jcvjs_10_23	

pain after lumbar discectomy. Answers to these questions remain unclear. We still have a very limited understanding of the pathophysiology of LDH.^[10] A thorough understanding of anatomy is necessary for practicing medicine.^[11] The load-bearing forces in the lumbar spine are more important than the thoracic spine and the cervical spine.^[3] The posterior longitudinal ligament (PLL) extends from the cervical spine to the sacrum^[12] on the dorsal surface of the vertebral body and represents the anterior portion of the vertebral canal and adheres to the intervertebral discs and adjacent marginal strips.^[13] The lumbar spine is stabilized by paraspinal muscles, including psoas muscles, erector spinae, and multifidus,^[7] and this ligament also provides mobility, stability, and flexibility to the spine.^[12] The PLL strongly attaches to the annulus and has been ruptured in patients with extruded and sequestered disc herniations. The PLL prevents the disc from protruding and plays a key role in the pathogenesis of LDH.^[12] The comparative effectiveness of this ligament may have a vital role in spinal surgery. Technologic development is important in neurosurgical practice;^[14] however, the pathophysiology of changes after lumbar discectomy is still not fully understood. Persistent pain after lumbar discectomy is not rare. Annular defects after lumbar discectomy may have a role. The biomechanical interaction of healthy spinal ligamentous structures is well-known, but the role of rupture of PLL has not been investigated yet. If the ruptured PLL is sutured after discectomy, there can provide a better postoperative outcome and prevent recurrent disc herniations. Given the imperfect success rate, any additional information that could improve the postoperative outcome of patients would be useful. To the best of our knowledge, currently, no studies in the existing literature explore the role of suture PLL in lumbar discectomy.

PATIENTS AND METHODS

The study was approved by the ethical committee of Recep Tayyip Erdogan University (approval date and number: 2020–149). The study included patients who underwent surgery for LDH between January 2021 and July 1, 2022. The patients were randomly assigned patients to either PLL suturing or not. Young patients (<18 years of age) and procedures in the thoracic and cervical spine were excluded from the study. LDH was assessed by magnetic resonance imaging (MRI). Inclusion criteria were the patients with LBP and extruded or sequestered intervertebral disc herniations in MRI. The patients were divided into two groups as the patients whose PLL was sutured and unsutured. A microdiscectomy was carried out through a standard interlaminar approach under local or general anesthesia. In surgery, after entering the intervertebral space, the

protruding degenerative nucleus pulposus was thoroughly removed until the nerve root was relaxed.

Postoperative evaluation

The 3.0 Tesla MRI (Discovery MR 750, GEM-70, General Electric Company, USA) imaging was used to detect the effects of PLL suturing on the intradural volume and was assessed before surgery and 6 months postoperatively using a flex body array coil. In sagittal T2-weighted images, TR: 3778 ms, TE: 102 ms, FOV: 32 cm, slice thickness: 4 mm, slice spacing: 1.5 mm, bandwidth: 41.67 KHz, NEX: 2.0, and slices (n): 12; in sagittal T1-weighted images, TR: 844 ms, TE: 10 ms, FOV: 32 cm, slice thickness: 4 mm, slice spacing: 1.5 mm, bandwidth: 50 KHz, NEX: 2.0, slices (n): 12; and in Axial T2-weighted images, TR: 4419 ms, TE: 102 ms, FOV: 20 cm, slice thickness: 4 mm, slice spacing: 1 mm, bandwidth: 41.67 KHz, NEX: 2.0, slices (n): 15 were used. Obtained images were sent to the workstation (Advantage Workstation 4.6; GE Healthcare). The spinal canal widths were measured by an independent radiologist in axial T2-weighted images at the discectomy level.

Statistical analysis

SPSS 21.0 software (SPSS Inc., IBM, Armonk, New York, USA) for Windows was used for statistical analyses. Differences between mean values were considered statistically significant when $P < 0.05$.

RESULTS

Forty-six (23 males and 23 females) patients were included in the study. There were 22 patients in the PLLs sutured (Group 1) and 24 patients in the not sutured group (Group 2). The levels involved were L3–4 (eight patients), L4–5 (21 patients), and L5–S1 (17 patients). The side was on the right in 25 patients and the left in 21 patients. The level and discectomy sides between both groups were not statistically significant, $P > 0.05$ [Table 1]. The ages, gender, and disc herniation levels of both groups were not statistically significant ($P > 0.05$) [Table 1]. Patients' average ages were 46.01 years for sutured individuals and

Table 1: Statistical findings of the study

Issue	Statistical test	P result
Gender	Pearson Chi-square test	0.238, insignificant
Side	Pearson Chi-square test	0.979, insignificant
Level	Pearson Chi-square test	0.155, insignificant
Age	Mann–Whitney U-test	0.800, insignificant
Preoperative spinal intradural area	Mann–Whitney U-test	0.495, insignificant
Postoperative spinal intradural area	Mann–Whitney U-test	0.001, significant

46.07 years for unsutured patients. Preoperative mean spinal intradural areas were 85.40 mm² in Group 1 patients who had PLL sutures and 77.29 mm² in Group 2 patients who had PLL unsutures (Group 2). In Group 1 patients, postoperative mean spinal intradural areas increased to 134.73 mm², whereas in Group 2 patients, they increased to 96.12 mm². The difference in preoperative mean spinal intradural areas between the two groups was not statistically significant, whereas Group 1 (patients with sutured PLL) showed a significant difference ($P = 0.001$) [Table 1]. Figure 1 shows the preoperative sagittal T2 (A) and axial T2 (B) weight images of the intradural area of a patient with L3–4 LDH before suturing of PLL. The intradural area was measured as 101.563 mm². After suturing of PLL during surgery, the intradural area was increased to 187.201 mm² of this patient [Figure 2a and b]. Another patient with right 4–5 LDH before surgery is shown in Figure 3a and b. The intradural area was measured as 82.4219 mm². The intradural area of this patient was moderately increased to 114.136 mm² without suturing of PLL [Figure 4a and b]. The Table 1 shows the summary of the statistical analysis. No complications such as lower limb pain and cerebrospinal fluid leakage, surgical site infection, or epidural hematoma were observed.

DISCUSSION

Key results

In the present study, we evaluated the effect of suturing annular or PLL defects. We intended to find a practical regenerative method with which to repair annulus fibrosus (AF) or PLL defects caused by disc herniation and/or lumbar discectomy surgery, and we found that closing the annular defect and providing PLL integrity by suturing

after surgery at the lateral portion leads to larger intradural space in patients than those unsutured patients after lumbar discectomy.

The rationale for suturing the posterior longitudinal ligament

The technical progress in the discipline of spinal surgery has led to many changes in our understanding of spine anatomy,^[15,16] and advances in microsurgical techniques have changed and widened the scope of neurosurgical practice.^[17] Our understanding of spinal biomechanics and bone physiology has allowed exponential growth in the field of spinal surgery.^[18,19] The concept of this study is interesting, and as the authors, we refer to prior studies of annular repair. Recently, Thakar *et al.* reported that a larger mean lumbar bony canals and dural sacs protect from the occurrence of symptomatic LDH.^[20] Considering the spine anatomy, the lumbar intervertebral disc and posterior paraspinal musculature are important structures. Segmental muscle alterations can occur by LDHs. PLL forms a narrow band, which widens symmetrically at the level of each disc. Rupture of PLL is involved in LDH. The gold standard treatment for LDH is posterior decompression, including discectomy and laminectomy. However, original or iatrogenic defects over AF occur after the discectomy procedure. Currently, there is no method or ideal device to close the annular defect. Closure of the annular defect is an ideal goal but difficult to achieve. Mechanical defect blocking by sutures or plugs has been used to close annular defects during the lumbar discectomy procedure. We think that recurrent disc herniation (RDH) can be prevented by saturation of PLL, because the closure of the annular defect

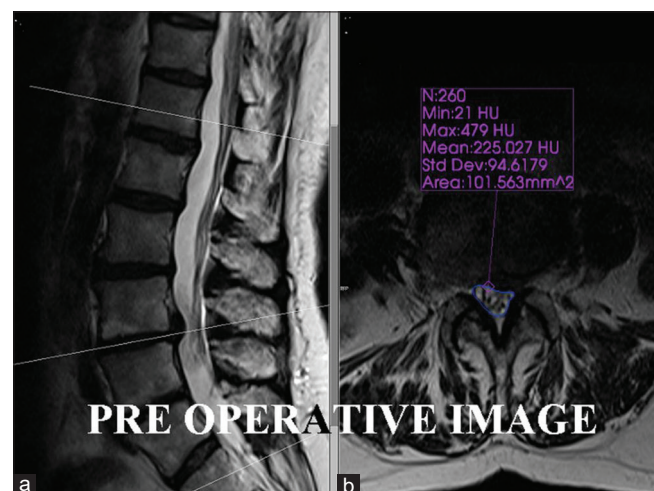


Figure 1: Preoperative Sagittal T2 (a), Axial T2 (b), weight images of the intradural area of a patient with L3–4 LDH before suturing of PLL. The intradural area was measured as 101.563 mm². LDH: Lumbar disc herniation, PLL: Posterior longitudinal ligament

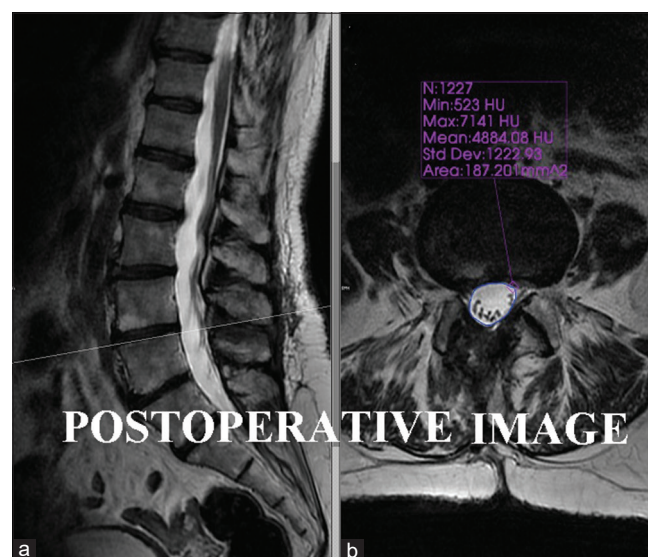


Figure 2: After suturing of PLL during surgery, (a) Sagittal, (b) Axial. Postoperative MRI of patient are seen; The intradural area was increased to 187.201 mm². PLL: Posterior longitudinal ligament

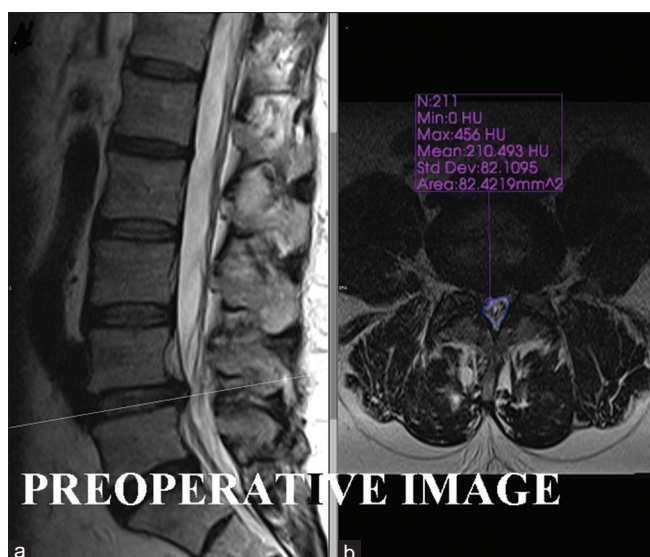


Figure 3: Preoperative sagittal T2 (a), axial T2 (b) weight images of the intradural area of a patient with right 4–5 LDH before surgery. The intradural area was measured as 82.4219 mm². LDH: Lumbar disc herniation

after lumbar discectomy may help preserve the physiological disc function and prevent long-term disc height loss and associated back and leg pain. Suturing this defect after lumbar discectomy may prevent to the migration of unrecognized disc fragments in the postoperative period. The remaining disc material after discectomy bears the weight and supports the trunk of the patient for the rest of the patient's life. Suturing PLL may affect the integrity of the disc. It is well-known that disc fragments may migrate to superior, inferior, or lateral sites in the anterior epidural space.^[11] In this study, the involved levels of herniations were L3–4 (eight patients), L4–5 (21 patients), and L5–S1 (17 patients), and differences in levels were not statistically significant ($P > 0.05$).

Spine anatomy has always been an interesting subject for medical scientists.^[21,22] Disc herniations rarely occur in the thoracic spine. This situation may be related to a stronger PLL in the thoracic spine compared to the cervical and lumbar vertebrae and may explain why thoracic disc herniation is rare. Three ligaments contribute to stability in the spine. One of them is PLL. A stronger PLL in the thoracic spine may cause a rare disc herniation rate in this region, so PLL can be because of regional different rates of disc herniation. We think that the rarity of disc herniations in the thoracic spine with stronger PLL than other parts of the spine is an important point, which supports the result of the present study. The larger intradural area by achieving the suturing PLL following discectomy, which was found in this study, may lead to a better clinical outcome for patients than those for unsutured patients. This subject should be studied in the future.

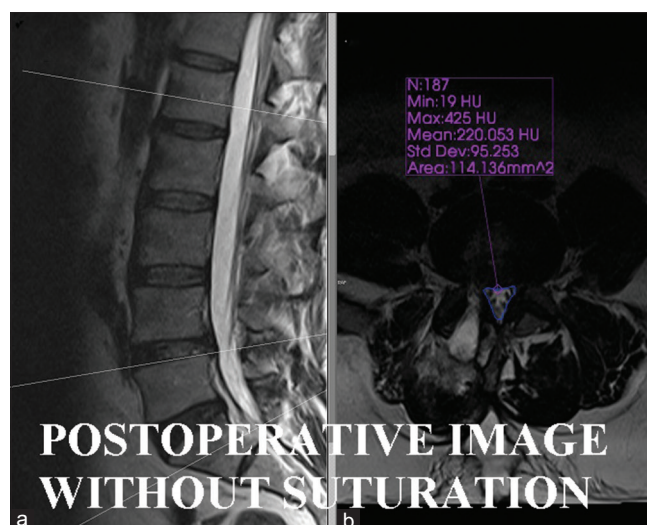


Figure 4: (a) Sagittal, (b) Axial. Show postoperative MRI of patient without suturation of PLL: The intradural area was moderately increased to 114.136 mm². PLL: Posterior longitudinal ligament

Recurrent disc herniation is still a problem

Lumbar discectomy for the management of lumbar radiculopathy is a commonly performed procedure with generally excellent patient outcomes.^[23] However, recurrent LDH remains one of the most common complications of the lumbar discectomy procedure.^[24] It is not a rare event. The incidence of recurrence ranged from 5% to 15%.^[25] Recurrent radicular pain after lumbar microdiscectomy may lead to reduced quality of life of the patient. The occurrence of recurrence following discectomy and herniectomy has been a matter of debate.^[23] Lumbar epidural fibrosis is believed to be one of the mechanisms involved in the genesis of pain. Good outcomes after surgery are an important issue,^[26,27] and the reoperation rate and persistent pain after lumbar discectomy can have to change the success of the surgery. The annular defect may be a risk factor for disc recurrence, and annular closure may be an option to reduce the risk of RDH, and we think that suturing of the PLL after discectomy might prevent the risk for recurrent disc herniation. This subject is out of the scope of this study and should be investigated in the future. Usually, disc herniation occurs not through PLL but through the annulus at the lateral margin of PLL. Therefore, a sealing of annulus has been an interest, and several techniques or instruments have been researched. In the last decade, annular closure devices have been frequently used. The aims of using annular closure devices are to minimize the herniation of the lumbar disc and further riskier revisions, these devices may lead to some complications.

This study is randomized controlled trials. In these kinds of studies, the effectiveness of one treatment over another is identified. The decision on the primary endpoint in a randomized clinical trial is of paramount importance. In

this study, the primary outcome was a large intraspinal area. Validity in research refers to how accurately a study answers the study question or the strength of the study conclusions.^[28] Here, validity refers to the effect of PLL suturing on the outcome of patients after lumbar discectomy. Disc morphology may be changed in patients with LDH. In the treatment of spine pathologies, one should consider the rules of anatomy and physiology.^[16] We think that providing the integrity of intervertebral discs after a discectomy is an important issue. For that reason, some materials have been investigated to keep the rest of the nucleus pulposus after initial discectomy in the disc space. Using annular closure devices after discectomy may lead to low rates of disc recurrences. In the future, we are planning to study the outcome and recurrent disc herniation rate after suturing the PLL. Fibrosis has been associated with a poorer outcome in lumbar disc surgery. Some structural and functional alterations are seen in a patient with LDH.^[26] Suturing of torn PLL may lead to a better outcome and lesser fibrosis by less surgical trauma. Postsurgical fibrosis is a consequence of the physiological attempt to repair the spinal structures. We did not analyze this subject, because it was out of the scope of this manuscript.

The increased use of technology in neurological and medical practices has changed the practice of neurosurgery,^[5] the advent of MRI, and the progressive increase in the definition of this modality of imaging in the last decades.^[29] Advancements in MR technology can be used to understand the nature of the spinal disorder.^[4] Today, MRI scans are an excellent, noninvasive means of imaging the entire spine^[26,30] and are generally considered to be the most sensitive noninvasive method for examining disc disease at present MRI has become the investigation of choice for patients of LBP with radiculopathy. The MRI can also be preferred in the postoperative period because it is more accurate than computed tomography in the evaluation of soft-tissue involvement. We used this modality and the effects of PLL suturing on the intradural volume after discectomy.

Limitation

The major limitation of this paper is the sample size of the present study. This is an important disadvantage of the study. It is difficult to compare the outcome of a neurosurgical procedure with a low number of cases.^[31] If a researcher selects fewer samples, it may lead to the missing of any significant difference even if it exists in the population.^[32] Neurosurgical operations have some features that are distinct from other operative procedures.^[33] The postoperative radiological view may have been good,^[34] but this does not always show that everything is going well.^[18] Strengths of

this study include a postoperative MRI at 6 months. Suturing PLL after discectomy is technically difficult as it is generally in tatters intraoperatively. The PLL closure of all cases was performed by the same surgeon. It can be asked why the spinal canal width was chosen as the outcome of interest. We did not use the patient-related outcome measure, such as pain scores, ODI, PROMs physical function, or even some sort of Odom's criteria; in the future, another study with these, the patient-related outcome measure may be conducted.

CONCLUSIONS

This study presents a small cohort study evaluating spinal canal width among patients with and without suturing of the PLL after lumbar discectomy. The outcome is the spinal canal area on axial MRI. The suturing PLL may represent a unique opportunity for meaningful improvement in clinical outcomes in patients identified as high risk for reherniation following discectomy. The importance of observational studies lies in providing impetus to future research.^[29] In the future, we think to investigate the effect of suturing on the patient outcome and recurrence rate. The importance of observational studies lies in the identification of important disorders and in providing impetus to future research.^[29] They allow research to be disseminated more rapidly and effectively.^[35] This study first time indicates that the PLL has a more protective than a supportive role according to its status (sutured or unsutured after discectomy) after discectomy. Our findings suggest that the restoration of annular integrity by suturing after discectomy may restore the lumbar disc anatomy. Whether or not restoring the anatomic structure of the lumbar disc to preoperative levels has any clinical benefit or effect on the postoperative outcome of patients is an area for further clinical research. More studies are required.

Authors' contribution section

All authors read and approved the final version of the manuscript.

Financial support and sponsorship

Nil.

Conflicts of interest

There are no conflicts of interest.

REFERENCES

- Ozturk S, Cakin H, Demir F, Albayrak S, Akgun B, Turan Y, *et al.* Cranially migrated lumbar intervertebral disc herniations: A multicenter analysis with long-term outcome. *J Craniovertebr Junction Spine* 2019;10:57-63.
- Akca N, Ozdemir B, Kanat A, Batecik OE, Yazar U, Zorba OU. Describing

- a new syndrome in L5-S1 disc herniation: Sexual and sphincter dysfunction without pain and muscle weakness. *J Craniovertebr Junction Spine* 2014;5:146-50.
3. Ozdemir B, Kanat A, Baticik OE, Gucer H, Yolas C. Ligamentum flavum hematomas: Why does it mostly occur in old Asian males? Interesting point of reported cases: Review and case report. *J Craniovertebr Junction Spine* 2016;7:7-12.
 4. Kanat A, Yazar U. Spinal surgery and neurosurgeon: Quo vadis? *J Neurosurg Sci* 2013;57:75-9.
 5. Kanat A, Tsianaka E, Gasenzer ER, Drosos E. Some interesting points of competition of x-ray using during the Greco-ottoman war in 1897 and development of neurosurgical radiology: A reminiscence. *Turk Neurosurg* 2022;32:877-81.
 6. Gasenzer ER, Kanat A, Ozdemir V, Neugebauer E. Analyzing of dark past and bright present of neurosurgical history with a picture of musicians. *Br J Neurosurg* 2018;32:303-4.
 7. Guvercin Y, Kanat A, Gundogdu H, Abdioglu AA, Guvercin AR, Balik MS. How does the side of lumbar disc herniation influence the psoas muscle size at the L4-5 level in patients operated for unilateral hip arthroplasty? *Int J Neurosci* 2022;1-10. doi: 10.1080/00207454.2022.2115907.
 8. Kanat A, Yazar U, Kazdal H, Sonmez OF. Introducing a new risk factor for lumbar disc herniation in females: Vertical angle of the sacral curvature. *J Korean Neurosurg Soc* 2012;52:447-51.
 9. Mostofi K, Moghaddam BG, Peyravi M. Late appearance of low back pain relating to Modic change after lumbar discectomy. *J Craniovertebr Junction Spine* 2018;9:93-5.
 10. Kanat A, Yazar U, Ozdemir B, Kazdal H, Balik MS. Neglected knowledge: Asymmetric features of lumbar disc disease. *Asian J Neurosurg* 2017;12:199-202.
 11. Ozdemir B, Kanat A, Baticik OE, Erturk C, Celiker FB, Guvercin AR, *et al.* First report of perforation of ligamentum flavum by sequestered lumbar intervertebral disc. *J Craniovertebr Junction Spine* 2017;8:70-3.
 12. Kilitci A, Asan Z, Yuceer A, Aykanat O, Durna F. Comparison of the histopathological differences between the spinal material and posterior longitudinal ligament in patients with lumbar disc herniation: A focus on the etiopathogenesis. *Ann Saudi Med* 2021;41:115-20.
 13. Salaud C, Ploteau S, Hamel O, Armstrong O, Hamel A. Morphometric study of the posterior longitudinal ligament at the lumbar spine. *Surg Radiol Anat* 2018;40:563-9.
 14. Kanat A, Kayaci S, Yazar U, Yilmaz A. What makes Maurice Ravel's deadly craniotomy interesting? Concerns of one of the most famous craniotomies in history. *Acta Neurochir (Wien)* 2010;152:737-42.
 15. Balik MS, Kanat A, Erkut A, Ozdemir B, Baticik OE. Inequality in leg length is important for the understanding of the pathophysiology of lumbar disc herniation. *J Craniovertebr Junction Spine* 2016;7:87-90.
 16. Ozdemir B, Kanat A, Erturk C, Baticik OE, Balik MS, Yazar U, *et al.* Restoration of anterior vertebral height by short-segment pedicle screw fixation with screwing of fractured vertebra for the treatment of unstable thoracolumbar fractures. *World Neurosurg* 2017;99:409-17.
 17. Kanat A, Epstein CR. Challenges to neurosurgical professionalism. *Clin Neurol Neurosurg* 2010;112:839-43.
 18. Kanat A, Ozdemir B. In reply to the letter to the editor regarding "restoration of anterior vertebral height by short-segment pedicle screw fixation with screwing of fractured vertebra for the treatment of unstable thoracolumbar fractures". *World Neurosurg* 2017;101:793.
 19. Kazdal H, Kanat A, Aydin MD, Yazar U, Guvercin AR, Calik M, *et al.* Sudden death and cervical spine: A new contribution to pathogenesis for sudden death in critical care unit from subarachnoid hemorrhage; first report – An experimental study. *J Craniovertebr Junction Spine* 2017;8:33-8.
 20. Thakar S, Raj V, Neelakantan S, Vasoya P, Aryan S, Mohan D, *et al.* Spinal morphometry as a novel predictor for recurrent lumbar disc herniation requiring revision surgery: Results of a case control study. *Neurol India* 2022;70:S211-7.
 21. Güvercin Y, Yaylacı M, Dizdar A, Kanat A, Uzun Yaylacı E, Ay S, *et al.* Biomechanical analysis of odontoid and transverse atlantal ligament in humans with ponticulus posticus variation under different loading conditions: Finite element study. *Injury* 2022;53:3879-86.
 22. Soner Buyukkinacı HT, Ofluoglu E. A history of the spinal cord. *Sinir Sist Cerrahisi Derg* 2008;1:67-72.
 23. Landi A, Grasso G, Mancarella C, Dugoni DE, Gregori F, Iacopino G, *et al.* Recurrent lumbar disc herniation: Is there a correlation with the surgical technique? A multivariate analysis. *J Craniovertebr Junction Spine* 2018;9:260-6.
 24. Ahsan K, Khan SI, Zaman N, Ahmed N, Montemurro N, Chaurasia B. Fusion versus nonfusion treatment for recurrent lumbar disc herniation. *J Craniovertebr Junction Spine* 2021;12:44-53.
 25. Mariscal G, Torres E, Barrios C. Incidence of recurrent lumbar disc herniation: A narrative review. *J Craniovertebr Junction Spine* 2022;13:110-3.
 26. Baticik OE, Kanat A, Ozdemir B, Gundogdu H. Asymmetric cross sectional area size of the psoas muscle seems to be a key feature in patients with L4-5 lumbar disc herniations. *Turk Neurosurg* 2022;32:237-43.
 27. Kanat A. Patient-evaluated outcome after surgery for basal meningiomas. *Neurosurgery* 2002;51:1530-1.
 28. Ozdemir B, Kanat A, Durmaz S, Ersegun Baticik O, Gundogdu H. Introducing a new possible predisposing risk factor for odontoid type 2 fractures after cervical trauma; ponticulus posticus anomaly of C1 vertebra. *J Clin Neurosci* 2022;96:194-8.
 29. Polat HB, Kanat A, Celiker FB, Tufekci A, Beyazal M, Ardic G, *et al.* Rationalization of using the MR diffusion imaging in B12 deficiency. *Ann Indian Acad Neurol* 2020;23:72-7.
 30. Kazdal H, Kanat A, Baticik OE, Ozdemir B, Senturk S, Yildirim M, *et al.* Central sagittal angle of the sacrum as a new risk factor for patients with persistent low Back pain after caesarean section. *Asian Spine J* 2017;11:726-32.
 31. Kanat A. Science in neurosurgery: The importance of the scientific method. *Neurosurgery* 1998;43:1497.
 32. Kilic M, Aydin MD, Demirci E, Kilic B, Yilmaz I, Tanriverdi O, *et al.* Unpublished neuropathologic mechanism behind the muscle weakness/paralysis and gait disturbances induced by sciatic nerve degeneration after spinal subarachnoid hemorrhage: An experimental study. *World Neurosurg* 2018;119:e1029-34.
 33. Kanat A. Risk factors for neurosurgical site infections after craniotomy: A prospective multicenter study of 2944 patients. *Neurosurgery* 1998;43:189-90.
 34. Kanat A. Comment on Bunmaprasert *et al.* Reducible nonunited type II odontoid fracture with atlantoaxial instability: Outcomes of two different fixation techniques. *Int. J. Environ. Res. Public Health* 2021, 18, 7990. *Int J Environ Res Public Health* 2022;19:5018.
 35. Gasenzer ER, Kanat A, Nakamura M. The influence of music on neurosurgical cases: A neglected knowledge. *J Neurol Surg A Cent Eur Neurosurg* 2021;82:544-51.