

Secondary syphilis mimicking marginal zone B-cell lymphoma



Emily Correia, BS,^a Laura Gleason, BS,^a Shalini Krishnasamy, MD,^{a,b} Alexa Cohen, BS,^a Safiyah Bhatti, MD,^{a,b} and Neda Nikbakht, MD, PhD^a
Philadelphia, Pennsylvania

Key words: B-cell lymphoma; clinicopathologic correlation; sexually transmitted diseases; syphilis.

INTRODUCTION

Syphilis is often referred to as the “great imitator,” as its clinical and histologic manifestations often mimic other cutaneous diseases. The clinical presentation of secondary syphilis extends over a wide spectrum of symptoms, including fever, malaise, and generalized lymphadenopathy, as well as a broad range of skin findings, including macular, papular, lichenoid, nodular, and pustular lesions.¹ Similar to its clinical presentation, the histologic findings of syphilis vary.² As a result, accurate diagnosis of atypical presentations of syphilis requires robust clinicopathologic collaborations.

CASE REPORT

A 50-year-old Caucasian man was referred to a cutaneous lymphoma clinic for evaluation of skin involvement by marginal zone B-cell lymphoma (MZL). The patient was originally assessed by Hematology for intermittent episodes of fever, night sweats, chills, fatigue, weight loss, lymphadenopathy, and a diffuse erythematous papular rash. Given the concern for systemic malignancy, an oncology workup, including imaging, blood work, and lymph node and skin biopsies, was initiated. Positron emission tomography and computed tomography scans displayed diffuse hypermetabolic cervical, axillary, and inguinal lymphadenopathy and hypermetabolic skin and subcutaneous lesions. The lymph node biopsy revealed a reactive process, while skin biopsies revealed MZL.

The skin biopsies demonstrated a dense, superficial, and nodular proliferation of lymphocytes

Abbreviations used:

MZL: marginal-zone B-cell lymphoma

and plasmacytoid cells that stained positive for CD20, B-cell lymphoma 2, and CD79a (Fig 1). A high Ki-67 proliferation index and lambda light chain restriction were noted; immunoglobulin heavy chain gene rearrangement analysis revealed monoclonality of the infiltrate. Spirochete, periodic acid–Schiff, and acid-fast stains were negative. These molecular findings raised concerns for MZL and prompted the referral to the cutaneous lymphoma clinic.

During the visit, the patient reported a 3-week history of fever, night sweats, and a diffuse papular rash that had not changed since his presentation to Hematology. Physical exam revealed crusted erythematous macules and papules diffusely scattered on the trunk, extremities, and face with dusky macules on bilateral palms and soles (Fig 2). He denied any additional symptoms or the use of any medications, including antibiotics. Even though the spirochete stain of the biopsy was negative, given the strong clinical suspicion for secondary syphilis, a rapid plasma reagent test was performed.

The rapid plasma reagent test was positive with a titer of 1:64, and the fluorescent treponemal antibody absorption test was positive. A diagnosis of secondary syphilis was made, and the patient received a penicillin injection (2,400,000 units/4 mL syringe).

From the Department of Dermatology and Cutaneous Biology^a; and Department of Medical Oncology, Sidney Kimmel Cancer Center^b, Thomas Jefferson University, Philadelphia.

Funding sources: Dr Nikbakht is a recipient of the Todd Nagel Memorial Award from the Skin Cancer Foundation.

IRB approval status: Not applicable.

Correspondence to: Neda Nikbakht, MD, PhD, Department of Dermatology and Cutaneous Biology, 833 Chestnut Street Suite 740, Philadelphia, PA 19107. E-mail: neda.nikbakht@jefferson.edu.

JAAD Case Reports 2022;20:50-3.

2352-5126

© 2021 by the American Academy of Dermatology, Inc. Published by Elsevier, Inc. This is an open access article under the CC BY-NC-ND license (<http://creativecommons.org/licenses/by-nc-nd/4.0/>).

<https://doi.org/10.1016/j.jdc.2021.11.026>

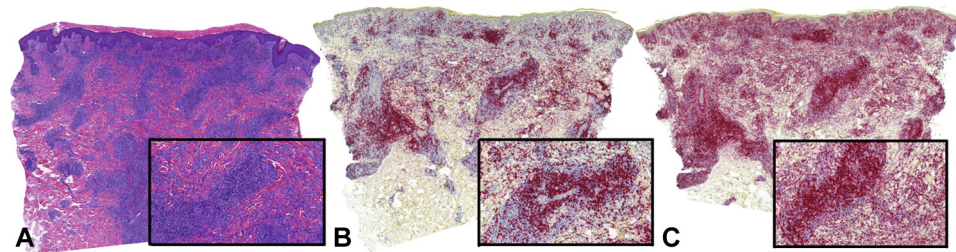


Fig 1. Dense, superficial, and nodular proliferation of lymphocytes and plasmacytoid cells (A, Hematoxylin-eosin stain; original magnification: $\times 40$; **Inset**, $\times 100$) that were CD20⁺ (B, Hematoxylin-eosin stain; original magnification: $\times 40$; **Inset** $\times 100$) and BCL-2⁺ (C, Hematoxylin-eosin stain; original magnification: $\times 40$, **Inset**, $\times 100$.) *BCL-2*, B-cell lymphoma 2.

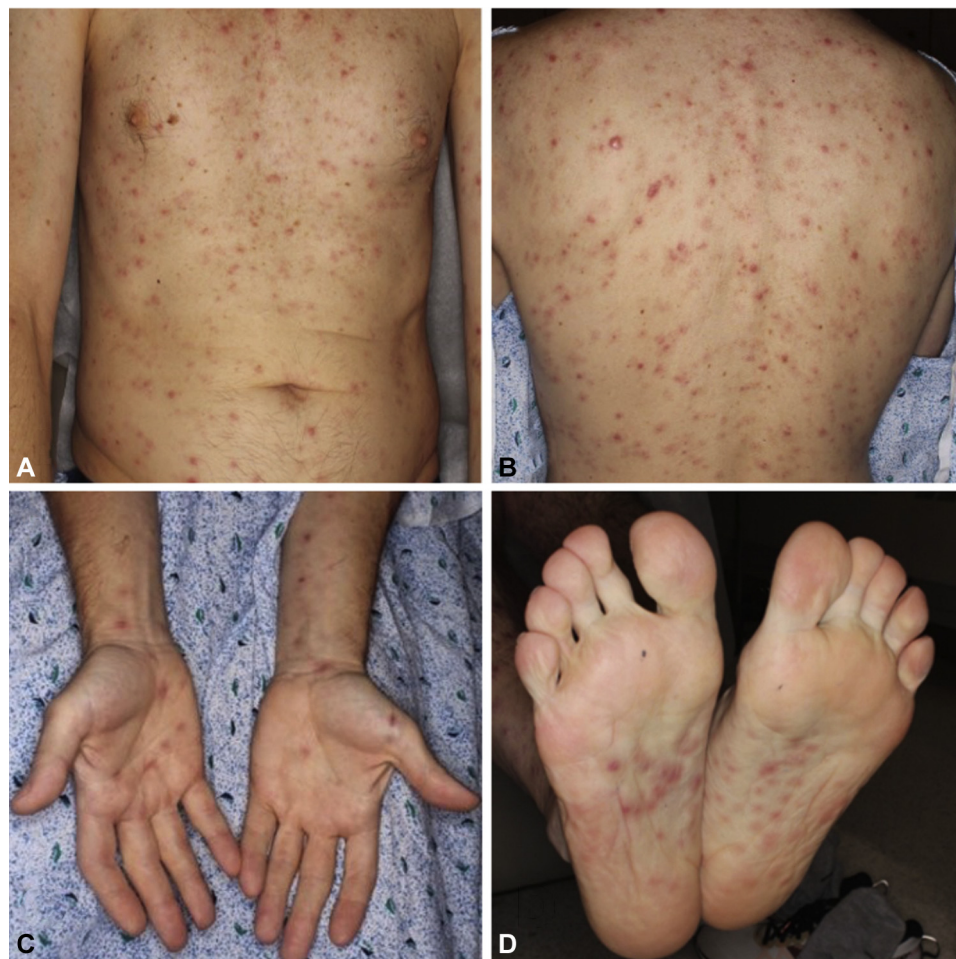

Fig 2. Crusted erythematous macules and papules on the chest (A), back (B), bilateral palms (C), and soles (D) were appreciated on initial presentation to Dermatology.

After receiving treatment, the patient's fever, night sweats, and rash subsided (Fig 3). He gained 4 kg since treatment; his lymphadenopathy resolved clinically, and the resolution of lymphadenopathy was confirmed by imaging. Three months later, a repeat rapid plasma reagent test revealed a 4-fold decline in the titer (1:4) demonstrating an appropriate response to treatment.

DISCUSSION

This case demonstrates the importance of analyzing the clinical presentation and histologic findings together to accurately diagnose syphilis and differentiate it from other inflammatory, infectious, or malignant processes. In this case, secondary syphilis was mistaken for MZL. Typically, MZL presents with a solitary or multifocal erythematous to

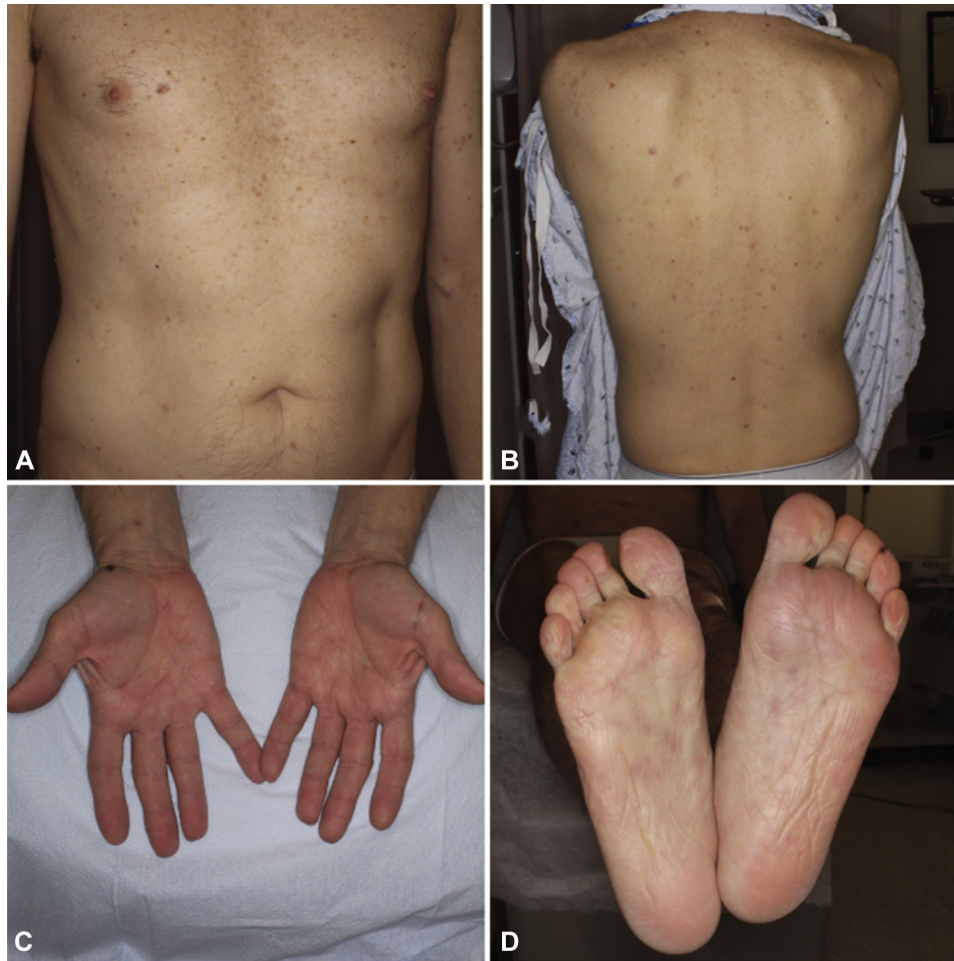


Fig 3. Resolution of erythematous macules and papules on the chest (A), back (B), bilateral palms (C), and soles (D) following treatment with penicillin.

violaceous papules, plaques, or nodules on the trunk or extremities.³ Pathology reveals diffuse infiltrates of atypical marginal zone B cells in the dermis and subcutis with CD20, B-cell lymphoma 2, and CD79a positivity and B-cell monoclonality.³ The patient's biopsy displayed similar findings with no evidence of spirochetes. These histopathologic findings in addition to the presence of so-called "B symptoms" and lymphadenopathy led to the diagnosis of MZL. However, the clinical presentation of diffuse papular rash involving the entire body, including the palms and soles, did not match the typical clinical manifestations of MZL.

Although the patient's biopsy was representative of MZL, it is well known that histologic findings associated with secondary syphilis are highly variable and nonspecific. Syphilis specimens have been mistaken for mycosis fungoides, psoriasis, lichen planus, reticulohistiocytomas, and pityriasis rosea.⁴ Similarly, syphilis has previously been reported to histologically mimic lymphoid neoplasms.⁵⁻⁸ Most recently, a study analyzed the histopathologic features distinguishing secondary syphilis from its

mimickers, but imitators of B-cell lymphomas were lacking.²

While detection of a dominant B-cell clone can indicate the presence of a B-cell malignancy, prominent B-cell clones may emerge in response to antigen stimulation. Clonal B-cell proliferation may ensue during the later stages of adaptive B-cell immunity, and particularly when a restricted number of epitopes are present on the eliciting antigens. Indeed, monoclonal immunoglobulin heavy chain gene rearrangements have been detected in cases of exposure to both pathogenic or autoreactive antigens including *Borrelia*-associated infections, morphea, and Jessner lymphocytic infiltrate among others.⁹

The B-cell clonality assay used in this case utilized the BIOMED-2 protocol.¹⁰ This protocol has the analytical sensitivity to detect 5% clonal cells in a polyclonal background. In detecting B-cell lymphomas compared with benign lymphoid hyperplasia, its sensitivity ranges from 85% to 99%, and its specificity ranges from 75% to 96%.¹⁰ It should be noted that sensitivity and specificity calculations for

this assay were limited by sample size and by diversity of the benign conditions used as controls. The limitations of clonality assays must be considered when interpreting the results. Most importantly, a clinicopathologic interpretation is necessary to determine whether clonal lymphocytes are malignant or reactive. In our case, the clonal B-cells detected were likely reactive to an antigenic epitope on the pathogenic spirochetes.

This case highlights the importance of collaboration between clinicians and pathologists to accurately diagnose syphilis. Estimates of the prevalence and incidence of syphilis provided by the World Health Organization demonstrate that syphilis remains an urgent public health issue.¹ Clinicians and pathologists alike should keep the possibility of this disease in mind to achieve an accurate diagnosis due to the clinical and histologic variations of the disease.

Conflicts of interest

None disclosed.

REFERENCES

1. Çakmak SK, Tamer E, Karadağ AS, Waugh M. Syphilis: a great imitator. *Clin Dermatol*. 2019;37(3):182-191. <https://doi.org/10.1016/j.clindermatol.2019.01.007>
2. Flamm A, Alcocer VM, Kazlouskaya V, Kwon EJ, Elston D. Histopathologic features distinguishing secondary syphilis from its mimickers. *J Am Acad Dermatol*. 2020;82(1):156-160. <https://doi.org/10.1016/j.jaad.2019.07.011>
3. National Comprehensive Cancer Network. NCCN Guidelines for Patients with Primary Cutaneous Lymphomas. 2021. Accessed December 28, 2021. <https://www.nccn.org/patients/guidelines/content/PDF/pcl-patient.pdf>
4. Jeerapaet P, Ackerman AB. Histologic patterns of secondary syphilis. *Arch Dermatol*. 1973;107(3):373-377.
5. Moon HS, Park K, Lee JH, Son SJ. A nodular syphilitic presenting as a pseudolymphoma: mimicking a cutaneous marginal zone B-cell lymphoma. *Am J Dermatopathol*. 2009;31(8):846-848. <https://doi.org/10.1097/DAD.0b013e3181ad4f22>
6. Goffinet DR, Hoyt C, Eltringham JR. Secondary syphilis misdiagnosed as lymphoma. *Ariz Med*. 1970;27(5):22-23.
7. Erfurt C, Lueftl M, Simon M Jr, Schuler G, Schultz ES. Late syphilis mimicking a pseudolymphoma of the skin. *Eur J Dermatol*. 2006;16(4):431-434.
8. Hodak E, David M, Rothem A, Bialowance M, Sandbank M. Nodular secondary syphilis mimicking cutaneous lymphoreticular process. *J Am Acad Dermatol*. 1987;17(5 Pt 2):914-917. [https://doi.org/10.1016/s0190-9622\(87\)70280-1](https://doi.org/10.1016/s0190-9622(87)70280-1)
9. Sproul AM, Goodlad JR. Clonality testing of cutaneous lymphoid infiltrates: practicalities, pitfalls and potential uses. *J Hematopathol*. 2012;(5):69-82. <https://doi.org/10.1007/s12308-012-0145-9>
10. Raess PW, Bagg A. The role of molecular pathology in the diagnosis of cutaneous lymphomas. *Patholog Res Int*. 2012; 2012:913523. <https://doi.org/10.1155/2012/913523>