

FORUM

Ultrasound evaluation of hemophilic arthropathy: a proposal of definitions in a changing landscape

¹Angelo Bianchi Bonomi Hemophilia and Thrombosis Center, Fondazione Istituto di Ricovero e Cura a Carattere Scientifico (IRCCS) Ca' Granda Ospedale Maggiore Policlinico, Milan, Italy

²Department of Pathophysiology and Transplantation, Università degli Studi di Milano, Milan, Italy

³Division of Orthopaedic Surgery and Traumatology, Fondazione Istituto di Ricovero e Cura a Carattere Scientifico (IRCCS) Ca' Granda Ospedale Maggiore Policlinico, Milan, Italy

Correspondence

Flora Peyvandi, Angelo Bianchi Bonomi Hemophilia and Thrombosis Center, Fondazione Istituto di Ricovero e Cura a Carattere Scientifico Ca' Granda Ospedale Maggiore Policlinico, Via Pace 9, Milan 20122, Italy.

Email: flora.peyvandi@unimi.it

Abstract

The advent of novel effective treatments and the identification of the need to achieve a higher trough level for persons with hemophilia A and B have changed the landscape of management of these patients, allowing to change the target from survival and prevention of life-threatening complications to prevention of musculoskeletal complications and improvement of quality of life. Point-of-care musculoskeletal ultrasound imaging has also improved the early recognition of joint bleeding and the differential diagnosis of acute joint pain. In addition, joint ultrasound allows the evaluation of the severity of hemophilic arthropathy in terms of synovitis and cartilage and bone damage. However, a lack of standardization in the definition of ultrasound elementary lesions of hemophilic arthropathy may lead to confusion and an incorrect evaluation of the presence and progression of joint damage. Here, we propose to start a standardization and validation process for ultrasound definitions of hemophilic arthropathy that has been planned to become a project within the Factor VIII/IX Standardization Subcommittee of the International Society on Thrombosis and Haemostasis Scientific and Standardization Committee.

KEYWORDS

cartilage, hemophilia, joints, synovitis, ultrasonography

Essentials

- Ultrasound examination is a valid tool for joint health monitoring in hemophilia.
- Ultrasound examination allows personalization of management in persons with hemophilia.
- Standardized ultrasound definitions of elementary lesions in hemophilic arthropathy are lacking.
- We advocate a validation process within the International Society on Thrombosis and Haemostasis.

1 | INTRODUCTION

Over the last decade, the improved quality of care and increased availability of drugs for prophylaxis have led to a shift in the objectives of prophylactic treatment from prevention of life-threatening bleeding to joint health and quality of life. However, persons with hemophilia

remain at risk of breakthrough bleeding. The majority of persons with severe hemophilia are trained to self-administer factor replacement in the case of a painful joint, even if bleeding is only suspected. However, data from the literature suggest that patient perception of bleeding and physical examination are inaccurate in identifying bleeding as less than half of self-reported episodes are actually bleeding when

musculoskeletal ultrasound is performed by an expert physician [1]. To date, point-of-care ultrasound imaging can be performed by expert clinicians at hemophilia treatment/comprehensive Centers to confirm the presence of hemorrhagic effusion [2]. Two ultrasound scores are available: the hemophilia early arthropathy detection with ultrasound (HEAD-US) [3] and the joint tissue activity and damage examination (JADE) [4]. The former is a scoring system based on an additive scale that evaluates the presence of synovitis and osteochondral damage, while the latter quantitatively measures soft tissue and cartilage thickness together with osteochondral damage at sentinel areas of the joints by defined transducer positions.

Unfortunately, a standardized ultrasound definition of acute joint bleeding is lacking, and there is no consensus on the clinical significance of the presence of a power Doppler (PD) signal.

Therefore, we suggest possible ultrasound definitions of hemophilic arthropathy elementary lesions while proposing a call to action to standardize and validate them in the context of the Factor VIII, Factor IX, and Rare Coagulation Disorders Subcommittee of the International Society on Thrombosis and Haemostasis Scientific and Standardization Committee.

2 | INTRA-ARTICULAR BLEEDING (HEMARTHOSIS)

2.1 | Definition

Prompt diagnosis and treatment of intra-articular bleeding are pivotal, as even a single episode can lead to irreversible cartilage damage and synovial hyperplasia [5]. Traditionally, joint bleeding has been defined as an episode characterized by a combination of swelling or warmth of the joint, increasing pain, or progressive functional impairment, even in the absence of imaging [6]. Thanks to the availability of replacement and nonreplacement drugs for prophylaxis, the protection of persons with hemophilia increased significantly. However, intra-articular bleeding could still occur even in the absence of overt joint swelling [7]. In the presence of joint pain without acute swelling, intra-articular bleeding must be distinguished from pain due to acute synovitis and mechanical joint pain due to late-stage hemophilic arthropathy [8].

Ultrasound performed by adequately trained specialists can be used to distinguish simple effusion (serous synovial fluid) from complex effusion (joint bleeding) or synovial hypertrophy [1,2].

2.2 | Ultrasound features

In the first hours from the start of a bleeding event, complex joint effusion appears as joint capsule distension due to isoechoic or hypoechoic compressible joint effusion with speckles (Figure) floating inside the joint during dynamic maneuvers [1,9] with a characteristic pattern resembling a shaken snow globe ("snow globe sign") [10]. In contrast, synovial

hypertrophy is not compressible, and no swirling movements can be detected inside the joint.

Later on, the effusion becomes more hypoechoic due to the so-called "hematocrit effect," ie, separation of the heavier cellular component from the fluid component [11].

In addition, it is important that ultrasound images are collected with a standardized procedure: 30° flexion of the knee for the suprapatellar recess, 90° flexion of the elbow for the olecranon recess, and maximum plantar flexion of the ankle for the tibiotarsal joint.

Another important feature that may help differentiate isoechoic capsule distension is the presence of a PD signal (Figure): superimposition of PD on grayscale images can be performed simultaneously during the same examination and can distinguish hyperemic vascularized synovial tissue from intra-articular hemorrhagic effusion, which has no PD signal [1].

3 | SYNOVITIS

3.1 | Definition

The term synovitis indicates the inflammation of the synovial membrane [12]. Synovial hypertrophy is characterized by the formation of villi and proliferation of vascularization in the subsynovial layer, which is greater in persons with hemophilia than in those with rheumatoid arthritis [13]. Vascularization of the synovial membrane in hemophilic arthropathy is prominent, but the inflammatory state observed in hemophilia is lower than that in rheumatoid arthritis [14]. Similar to what is observed in osteoarthritis, lymphocyte infiltrates can be found in the synovial membrane of persons with hemophilia, although actual follicles such as those observed in rheumatoid arthritis are rarely present [15].

In the early stage of the disease, an inadequate prophylaxis regimen or a low treatment adherence leads to repeated joint bleeding and the development of synovitis, which further predisposes to recurrent joint bleeding. On the other hand, late-stage synovitis may not lead to recurrent intra-articular bleeding because it is mainly fibrotic [10].

The differential diagnosis of acute joint pain is important because intra-articular bleeding requires immediate factor replacement treatment, whereas acute synovitis may respond to treatment with anti-inflammatory drugs.

3.2 | Ultrasound features

In 2017, the European Alliance of Associations for Rheumatology - Outcome Measures in Rheumatology (EULAR-OMERACT) Ultrasound Taskforce defined synovitis as the presence of a hypoechoic synovial hypertrophy, ie, poorly compressible and nondisplaceable hypoechoic tissue lining the joint capsule, regardless of the presence of effusion or any grade of PD signal [16]. According to this definition, the presence of a hypoechoic synovial hypertrophy is mandatory for defining the

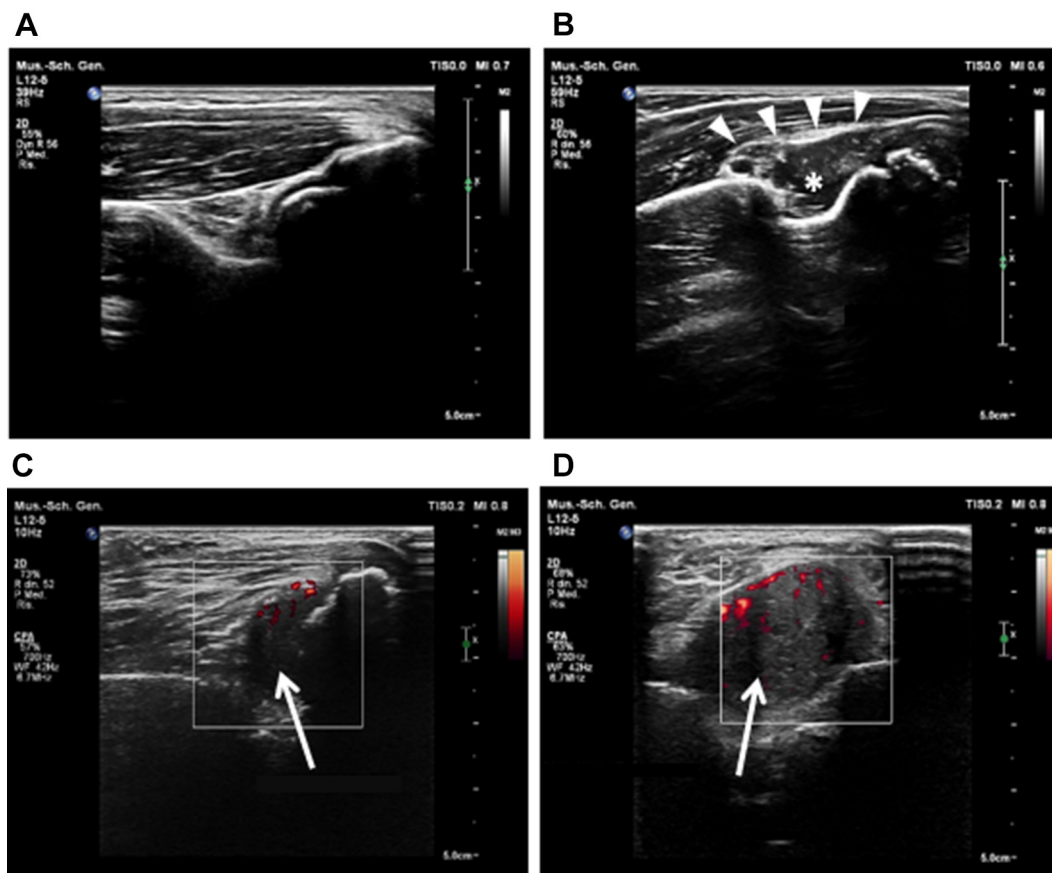


FIGURE Longitudinal scan of the posterior recess of the elbow. (A) A normal elbow. (B) Joint bleeding in the posterior recess of the elbow of an adult person with severe hemophilia and hemophilic arthropathy: the joint capsule is distended (arrowheads) by an inhomogeneous isoechoic corpusculated fluid (asterisk) with speckles that swirl at dynamic maneuvers. (C) Synovial hyperplasia (arrow) with power Doppler signal in the posterior recess of the elbow of a different adult patient with hemophilic arthropathy in a longitudinal scan and (D) in a transversal scan. The presence of a Doppler signal in (C and D) suggests that the capsule distension is due to solid and vascularized synovial tissue and, therefore, allows for the exclusion of joint bleeding.

presence of synovitis and for grading PD activity, while the presence of synovial effusion is not necessary.

A scoring system was proposed, where grayscale synovitis color/PD signal grade 0 corresponds to absence of synovial thickening and absence of flow signal; grade 1 corresponds to mild synovial thickening, ie, filling the angle between the periarticular bones, with no bulging of the joint capsule and up to 3 isolated vessel signals or up to 1 confluent spot and 2 single spots or up to 2 confluent PD spots; grade 2 corresponds to moderate synovial thickening with a flat joint capsule and confluent vessel signals, with an extent $\leq 50\%$ of the total grayscale background; and grade 3 corresponds to severe synovial thickening, bulging over the line linking tops of the periarticular bones and confluent vessel signals involving $>50\%$ of the total grayscale background [17].

In hemophilic arthropathy, unlike rheumatoid arthritis or other inflammatory arthritides, a PD signal is not always present [18]. On the other hand, the presence of a PD signal excludes that the isoechoic tissue is actually synovial effusion (Figure) [19].

The clinical significance of a PD signal in hemophilic synovitis is unclear and will be the objective of future studies.

4 | OSTEOCHONDRAL DAMAGE

4.1 | Definition

The repeated extravasation of blood into the joint cavity is the culprit of both synovial and cartilage changes, eventually leading to articular cartilage damage [20]. In patients with hemophilia, osteochondral damage may be typically detected with ultrasound at the anterior aspect of the distal humeral epiphysis of the elbow, at the femoral trochlea in the knee, and at the anterior aspect of the talar dome of the ankle [3].

4.2 | Ultrasound features

Ultrasound is not capable of investigating deeper sites of osteochondral damage, although the diffuse osteochondral damage in persons with hemophilia may warrant the policy of considering one surface representative of the overall status of the joint without significantly reducing the sensitivity of the method [3]. Normally, the articular cartilage appears as an anechoic band of uniform thickness

over the subchondral bone, which appears as a hyperechogenic smooth regular surface (grade 0 of the HEAD-US score). A partial thickness defect involving <25% of the articular cartilage is described as grade 1, and a defect involving 25% to 50% of the articular cartilage is a grade 2 damage. If the damage involves >50% of the surface it is grade 3, whereas grade 4 cartilage damage corresponds to complete cartilage destruction or no visualization of the articular cartilage on the target subchondral bone surface. Bone damage in the HEAD-US score is defined as grade 1 when the subchondral bone appears cobble and irregular with or without osteophytes and as grade 2 in the presence of deranged subchondral bone with or without erosions and with prominent osteophytes around the joint [3].

Although these distinctions may be helpful in the follow-up of joint damage progression, they correlate with irreversible damage. Instead, early stages of synovitis could still be reversible and should be considered the focus of prophylaxis fine-tuning and treatment personalization.

5 | CONCLUSIONS

In an era of improved management of patients with hemophilia, we are now able to aim for zero joint bleeding. This objective could be achieved by detecting even minimal joint bleeding episodes. Ultrasound is a valid tool for point-of-care evaluation of joints in hemophilia, and the advent of telemedicine will further improve early diagnosis of joint bleeding and prevention of complications. However, there is a proper need for standardization of the definitions of lesions on ultrasound. We advocate a validation process to be planned within the International Society on Thrombosis and Haemostasis Scientific and Standardization Committee in the context of the Factor VIII, Factor IX, and Rare Coagulation Disorders Subcommittee.

APPENDIX

The Ultrasound in hemophilic arthropathy study group is composed of Andrea Giachi, Sara Arcudi, Alessandro Ciavarella, and Simona Maria Siboni, Milan, Lombardy, Italy.

KEYWORDS

cartilage, hemophilia, joints, synovitis, ultrasonography

ACKNOWLEDGMENTS

We thank the patients who gave their consent for anonymous publication of their ultrasound images.

FUNDING

Part of this research was supported by the Multilayered Urban Sustainability Action – MUSA project, funded by the European Union – Next-GenerationEU, under the National Recovery and Resilience Plan (NRRP) Mission 4 Component 2 Investment Line 1.5: Strengthening of research

structures and creation of R&D “innovation ecosystems”, set up of “territorial leaders in R&D”; by the Personalised hEmophilia Therapy based on intelligent Remote monitoring of joint health - PETRA, funded by the Italian taxes 5 × 1000—2020 devolved to Fondazione Istituto di Ricovero e Cura a Carattere Scientifico (IRCCS) Ca' Granda Ospedale Maggiore Policlinico; and by the Italian Ministry of Health—Bando Ricerca Corrente 2023. The Fondazione Istituto di Ricovero e Cura a Carattere Scientifico (IRCCS) Ca' Granda Ospedale Maggiore Policlinico is a member of the European Reference Network EuroBloodNet.

AUTHOR CONTRIBUTIONS

R.G. performed the literature research and wrote the first draft together with the Ultrasound in hemophilia study group; R.G. performed the musculoskeletal ultrasound and collected and reviewed the images together with the other members of the Ultrasound in hemophilia study group. L.P.S. and F.P. evaluated joint health, supervised the study group activities, and revised the final draft.

RELATIONSHIP DISCLOSURE

R.G. is a member of the advisory boards of BioMarin, Pfizer, Bayer, and Takeda and has participated in educational seminars sponsored by Pfizer, Sobi, and Roche. F.P. is a member of the advisory boards of BioMarin, Sanofi, Sobi, CSL Behring, and Roche and has participated in educational seminars sponsored by Takeda and Spark. L.P.S. has no disclosure to make.

Roberta Gualtierotti^{1,2} 

Luigi Piero Solimeno³

Flora Peyvandi^{1,2} 

on behalf of the Ultrasound in hemophilic arthropathy study group

¹Angelo Bianchi Bonomi Hemophilia and Thrombosis Center, Fondazione Istituto di Ricovero e Cura a Carattere Scientifico (IRCCS) Ca' Granda Ospedale Maggiore Policlinico, Milan, Italy

²Department of Pathophysiology and Transplantation, Università degli Studi di Milano, Milan, Italy

³Division of Orthopaedic Surgery and Traumatology, Fondazione Istituto di Ricovero e Cura a Carattere Scientifico (IRCCS) Ca' Granda Ospedale Maggiore Policlinico, Milan, Italy

Handling Editor: Dr Michael Makris

Correspondence

Flora Peyvandi, Angelo Bianchi Bonomi Hemophilia and Thrombosis Center, Fondazione Istituto di Ricovero e Cura a Carattere Scientifico Ca' Granda Ospedale Maggiore Policlinico, Via Pace 9, Milan 20122, Italy.

Email: flora.peyvandi@unimi.it

TWITTER

Roberta Gualtierotti  @RobertaGualtie6

Flora Peyvandi  @flora_peyvandi

REFERENCES

- [1] Ceponis A, Wong-Sefidan I, Glass CS, von Drygalski A. Rapid musculoskeletal ultrasound for painful episodes in adult haemophilia patients. *Haemophilia*. 2013;19:790–8.
- [2] Baker N, Dover S, Babyn P, Feldman BM, von Drygalski A, Doria AS, et al. Musculoskeletal ultrasound in hemophilia: results and recommendations from a global survey and consensus meeting. *Res Pract Thromb Haemost*. 2021;5:e12531. <https://doi.org/10.1002/rth2.12531>
- [3] Martinoli C, Della Casa Alberighi O, Di Minno G, Graziano E, Molinari AC, Pasta G, et al. Development and definition of a simplified scanning procedure and scoring method for Haemophilia Early Arthropathy Detection with Ultrasound (HEAD-US). *Thromb Haemost*. 2013;109:1170–9.
- [4] Volland LM, Zhou JY, Barnes RFW, Kruse-Jarres R, Steiner B, Quon DV, et al. Development and reliability of the joint tissue activity and damage examination for quantitation of structural abnormalities by musculoskeletal ultrasound in hemophilic joints. *J Ultrasound Med*. 2019;38:1569–81.
- [5] Roosendaal G, Lafeber FP. Blood-induced joint damage in hemophilia. *Semin Thromb Hemost*. 2003;29:37–42.
- [6] Blanchette VS, Key NS, Ljung LR, Manco-Johnson MJ, van den Berg HM, Srivastava A. Subcommittee on Factor VIII, Factor IX and Rare Coagulation Disorders of the Scientific and Standardization Committee of the International Society on Thrombosis and Hemostasis. Definitions in hemophilia: communication from the SSC of the ISTH. *J Thromb Haemost*. 2014;12:1935–9.
- [7] Manco-Johnson MJ, Abshire TC, Shapiro AD, Riske B, Hacker MR, Kilcoyne R, et al. Prophylaxis versus episodic treatment to prevent joint disease in boys with severe hemophilia. *N Engl J Med*. 2007;357:535–44.
- [8] Kidder W, Nguyen S, Larios J, Bergstrom J, Ceponis A, von Drygalski A. Point-of-care musculoskeletal ultrasound is critical for the diagnosis of hemarthroses, inflammation and soft tissue abnormalities in adult patients with painful haemophilic arthropathy. *Haemophilia*. 2015;21:530–7.
- [9] Bonnefoy O, Diris B, Moinard M, Aunoble S, Diard F, Hauger O. Acute knee trauma: role of ultrasound. *Eur Radiol*. 2006;16:2542–8.
- [10] Gualtierotti R, Solimeno LP, Peyvandi F. Hemophilic arthropathy: current knowledge and future perspectives. *J Thromb Haemost*. 2021;19:2112–21.
- [11] Soni NJ, Franco R, Velez MI, Schnobrich D, Dancel R, Restrepo MI, et al. Ultrasound in the diagnosis and management of pleural effusions. *J Hosp Med*. 2015;10:811–6.
- [12] Smolen JS, Aletaha D, Barton A, Burmester GR, Emery P, Firestein GS, et al. Rheumatoid arthritis. *Nat Rev Dis Primers*. 2018;4:18001. <https://doi.org/10.1038/nrdp.2018.1>
- [13] Jiang J, Leong NL, Khalique U, Phan TM, Lyons KM, Luck Jr JV. Connective tissue growth factor (CTGF/CCN2) in haemophilic arthropathy and arthrofibrosis: a histological analysis. *Haemophilia*. 2016;22:e527–36.
- [14] Hoots WK. Pathogenesis of hemophilic arthropathy. *Semin Hematol*. 2006;43(Suppl 1):S18–22.
- [15] Haraoui B, Pelletier JP, Cloutier JM, Faure MP, Martel-Pelletier J. Synovial membrane histology and immunopathology in rheumatoid arthritis and osteoarthritis. In vivo effects of antirheumatic drugs. *Arthritis Rheum*. 1991;34:153–63.
- [16] Bruyn GA, Iagnocco A, Naredo E, Balint PV, Gutierrez M, Hammer HB, et al. OMERACT definitions for ultrasonographic pathologies and elementary lesions of rheumatic disorders 15 years on. *J Rheumatol*. 2019;46:1388–93.
- [17] Terslev L, Naredo E, Aegerter P, Wakefield RJ, Backhaus M, Balint P, et al. Scoring ultrasound synovitis in rheumatoid arthritis: a EULAR-OMERACT ultrasound taskforce-Part 2: reliability and application to multiple joints of a standardised consensus-based scoring system. *RMD Open*. 2017;3:e000427. <https://doi.org/10.1136/rmdopen-2016-000427>
- [18] Di Minno MND, Pasta G, Airdi S, Zaottini F, Storino A, Cimino E, et al. Ultrasound for early detection of joint disease in patients with hemophilic arthropathy. *J Clin Med*. 2017;6:77. <https://doi.org/10.3390/jcm6080077>
- [19] Acharya SS, Schloss R, Dyke JP, Mintz DN, Christos P, DiMichele DM, et al. Power Doppler sonography in the diagnosis of hemophilic synovitis—a promising tool. *J Thromb Haemost*. 2008;6:2055–61.
- [20] Valentino LA, Hakobyan N, Enockson C. Blood-induced joint disease: the confluence of dysregulated oncogenes, inflammatory signals, and angiogenic cues. *Semin Hematol*. 2008;45(Suppl 1):S50–7.