



A benign cause of hyperandrogenism in a postmenopausal woman

João José Nunes Roque¹, Irina Borisovna Samokhvalova Alves²,
Ana Maria de Almeida Paiva Fernandes Rodrigues³ and Maria João Bugalho^{1,4}

¹Department of Endocrinology, Hospital de Santa Maria, Lisboa, Portugal, ²Department of Pathology, Hospital de Santa Maria, Lisboa, Portugal, ³Department of Obstetrics & Gynecology, Hospital de Santa Maria, Lisboa, Portugal, and ⁴Faculdade de Medicina da Universidade de Lisboa, Lisboa, Portugal

Correspondence
should be addressed
to M J Bugalho

Email
[maria.bugalho@chln.
min-saude.pt](mailto:maria.bugalho@chln.min-saude.pt)

Summary

Menopause is a relative hyperandrogenic state but the development of hirsutism or virilizing features should not be regarded as normal. We report the case of a 62-year-old woman with a 9-month history of progressive frontotemporal hair loss and hirsutism, particularly on her back, arms and forearms. Blood tests showed increased total testosterone of 5.20 nmol/L that remained elevated after an overnight dexamethasone suppression test. Free Androgen Index was 13.1 and DHEAS was repeatedly normal. Imaging examinations to study adrenals and ovaries were negative. The biochemical profile and the absence of imaging in favor of an adrenal tumor made us consider the ovarian origin as the most likely hypothesis. After informed consent, bilateral salpingectomy-oophorectomy and total hysterectomy were performed. Gross pathology revealed ovaries of increased volume and histology showed bilateral ovarian stromal hyperplasia. Testosterone levels normalized after surgery and hirsutism had completely subsided 8 months later.

Learning points:

- Menopause is a relative hyperandrogenic state
- Hirsutism and/or virilizing features, in a postmenopausal woman, should raise the hypothesis of a malignant cause
- In the absence of an identifiable ovarian or adrenal tumor, the ovarian origin remains the most likely
- Peripheral aromatization of excess androgen may conduct to high levels of estrogen increasing the risk of endometrial cancer
- Bilateral oophorectomy results in significant clinical improvement.

Background

In healthy women, ovarian androgen production declines progressively with age, while estrogen synthesis declines abruptly after menopause. A rise in gonadotropin levels and a decrease in SHBG concentration are also noted in postmenopausal women. Thus, mild signs of hyperandrogenism may be part of the aging process (1).

However, the development of hirsutism accompanied by virilizing features like maletype alopecia, acne, voice deepening and clitoromegaly must prompt adequate investigation, since those could be manifestations of a malignant androgen-secreting tumor, the

commonest cause of recent onset clinically exuberant hyperandrogenism in postmenopausal women (2).

The present case documents a benign but rare cause of hyperandrogenism in a postmenopausal woman whose final diagnosis was established by histology.

Case presentation

A 62-year-old woman presented in the Endocrine Clinic with a 9-month history of new-onset and progressive hair loss, scalp hair thinning, hirsutism and no other



virilizing signs or symptoms (Fig. 1). Her menarche was at 13 years, she had regular menses until reaching menopause at 51 years and there was no pre or post-menopausal metrorrhagia history. She reported one uneventful pregnancy with term vaginal delivery, one 7-month in utero death for no clearly understood reason and one voluntary termination of pregnancy. She was diagnosed with essential hypertension and dyslipidemia at the age of 50 years and had progressive weight gain over the years. At the age of 56 years, she was diagnosed with type 2 diabetes. No previous surgeries were reported and family history was unremarkable. Her regular medication was metformin (2000 mg/day), losartan (50 mg/day) and spironolactone (25 mg/day). She was not taking any drug with androgenic effects. On physical examination, she had obesity (abdominal perimeter 109 cm, BMI 37 kg/m², class II of WHO classification) and had evident frontotemporal alopecia and increased terminal hair growth, particularly on her back, arms and forearms.

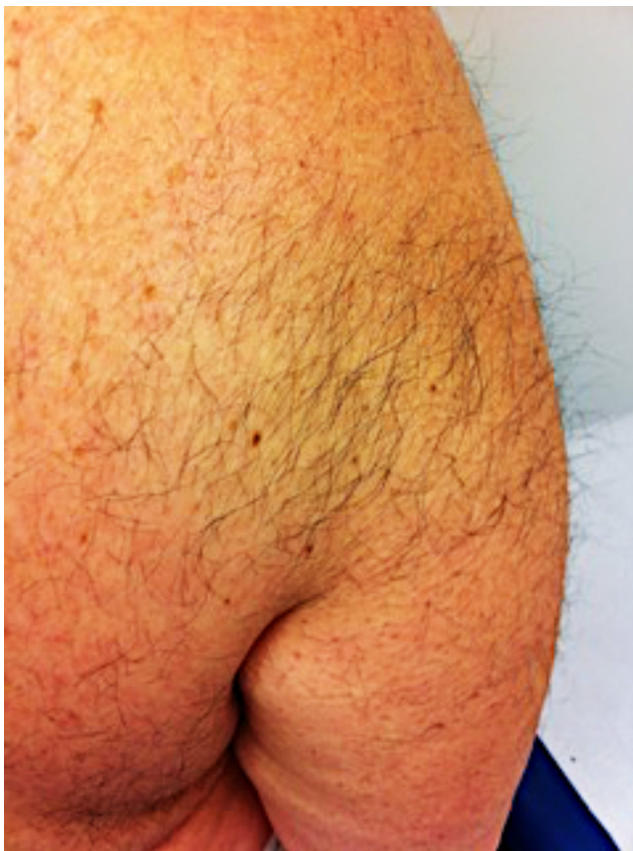

Figure 1
Marked skin redness and hirsutism on the back and right upper limb. Captioned on first consultation.

There were no other virilizing signs like acne or voice deepening. Skin hyperpigmentation, reddish striae and *acanthosis nigricans* were absent. Blood pressure and heart rate were normal.

Investigation

Initial diagnostic tests, under the usual medication, documented increased total testosterone (5.20 nmol/L); androstenedione of 8.73 nmol/L; gonadotropins in the menopause range - LH: 23.9 mIU/mL; FSH: 22.8 mIU/mL; SHBG: 32.3 nmol/L; and Free Androgen Index: 13.1. The other hormonal parameters particularly DHEAS, 17-hydroxyprogesterone, IGF1, prolactin and ACTH were normal. Lipid profile exhibited mixed dyslipidemia (total cholesterol of 6.54 mmol/L, triglycerides of 2.47 mmol/L, HDL: 1.32 mmol/L, LDL: 4.09 mmol/L).

After an overnight dexamethasone suppression test, cortisol was suppressed (30.34 nmol/L), but total testosterone persisted elevated (4.23 nmol/L).

The patient underwent abdominal and pelvic CT scan which failed to reveal any adrenal or ovarian lesion. Transvaginal ultrasound report mentioned 2 small leiomyomas without reference to other alterations, particularly of the ovaries.

The high levels of testosterone favored a malignant etiology. Furthermore, normal values of DHEAS and the absence of imaging evidence of an adrenal tumor suggested the ovarian origin of hyperandrogenism as the most likely hypothesis.

Treatment

Bilateral salpingectomy-oophorectomy and total hysterectomy, via laparotomy, were performed, after discussion by a multidisciplinary team and taking into account the patient's perspective and preferences. Gross pathology revealed slightly enlarged ovaries (right ovary: 3.5 × 2 × 1.7 cm; left ovary: 3 × 2 × 1.7 cm) and normal endometrium. Histology identified bilateral ovarian stromal hyperplasia (Figs 2 and 3).

Outcome and follow-up

Surgical intervention proved to be remarkably effective, as the patient is still on remission. Total testosterone levels became normal 1 month after surgery and clinical improvement was first noted 8 months later (Fig. 4).

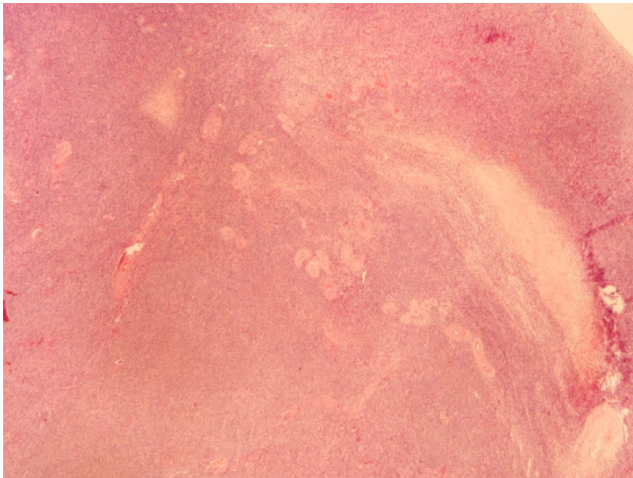


Figure 2
Ovarian stromal hyperplasia. Ovarian cortical and medullary expansion due to stromal fusiform cell hyperplasia with diffuse growth (hematoxylin–eosin staining, original magnification $\times 20$).

Discussion

This clinical case illustrates some of the diagnostic challenges of postmenopausal hyperandrogenism. A careful clinical history and physical examination are crucial for a correct diagnosis, just as the adequate prescription and interpretation of complementary exams. Our patient had a relatively fast and exuberant clinical course, which initially pointed toward a malignant etiology and prompted rapid investigation. Persistence of elevated serum testosterone levels after dexamethasone-suppression test reinforced the clinical hypothesis. Noteworthy, the patient was under Spironolactone

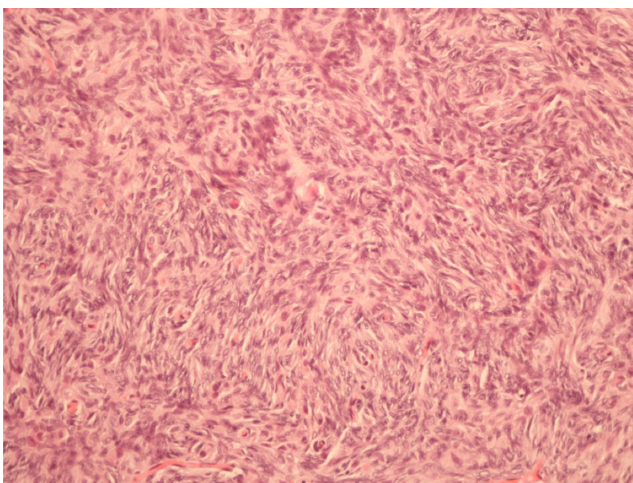


Figure 3
Ovarian Stromal Hyperplasia. Dense proliferation of uniform, oval to spindle-shaped stromal cells. No cellular atypia, mitosis or luteinized theca cells (hematoxylin–eosin staining, original magnification $\times 200$).

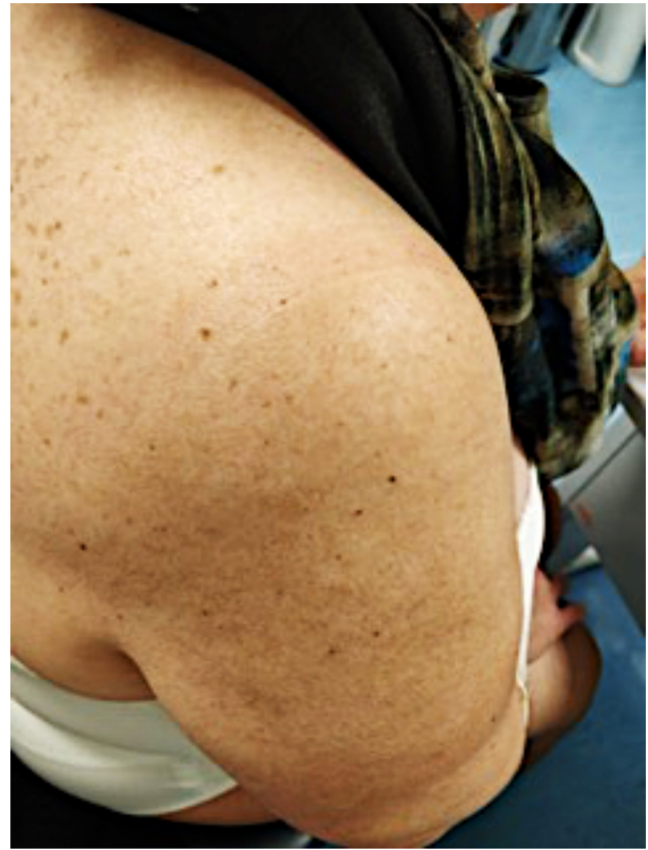

Figure 4
Complete resolution of presenting signs 8 months after surgery.

treatment that is an inhibitor of aldosterone and also a weak competitive inhibitor of androgen binding to the androgen receptor and a weak inhibitor of testosterone synthesis. The biochemical profile, as well as a CT scan negative for adrenal tumors, did not favor the adrenal etiology. On the contrary, ovarian tumors are easily missed by imaging making an ovarian androgen origin more likely. Accordingly, we decided to perform a bilateral salpingo-oophorectomy with hysterectomy, which afterward proved to be curative (Fig. 4). Histological diagnosis was bilateral ovarian stromal hyperplasia (Figs 2 and 3). This is a benign entity usually referred in close association with the presence of nests of luteinized theca cells in the ovarian stroma (termed as Ovarian Hyperthecosis), which curiously were not identified on our histological examination (Figs 2 and 3). Its etiology is still not well understood. It is most frequently seen in postmenopausal women and is characterized by severe clinical and biochemical hyperandrogenism and insulin resistance, generally more exuberant than observed in other benign etiologies (3). Definitive diagnosis is established by histology. Due to increased androgen secretion, these



patients can also have increased plasma androstenedione and, as a consequence of peripheral aromatization, high levels of estrogens. Thus, the risk of endometrial hyperplasia and endometrial carcinoma is increased (3, 4). Biochemical testing typically shows high serum total testosterone (over 5.20nmol/L), normal or suppressed LH and FSH, hyperglycemia, variable serum androstenedione, normal DHEAS, 17-hydroxyprogesterone, prolactin and IGF1. Ultrasonography usually shows bilateral ovarian volume increase, which was not reported in our case, although observed by the pathologist (5). Magnetic resonance can identify homogenous T2-hypointensity and mild enhancement of the ovaries (6). Ovarian and/or adrenal venous sampling can also be used when imaging tests are negative. However, this should only be performed in premenopausal women contemplating pregnancy, since it requires a very experienced radiologist and there is still no consensus of whether it can localize the androgen source. Treatment of suspected ovarian stromal hyperplasia/ovarian hyperthecosis is bilateral oophorectomy when fertility is not a concern. Long-term gonadotropin-releasing hormone agonist treatment is an alternative in younger women aiming to preserve fertility (7).

Until now, less than 30 cases of postmenopausal hyperandrogenism caused by ovarian stromal hyperplasia were reported; in all, hyperplasia coexisted with ovarian hyperthecosis (luteinized theca cells) which reinforces the singularity of the present case.

Patient's perspective

The problem was bothersome and with a negative impact on her self-image. It started suddenly and unexpectedly. Furthermore, she had never met a woman who had had a similar situation. After surgery, physical features improved fast. At 8-month follow-up visit, she was very satisfied and grateful to her medical team.

Declaration of interest

The authors declare that there is no conflict of interest that could be perceived as prejudicing the impartiality of the research reported.

Funding

This work did not receive any specific grant from any funding agency in the public, commercial or not-for-profit sector.

Patient consent

Written informed consent for publication of the submitted article and accompanying images was obtained from the patient.

Author contribution statement

João José Nunes Roque was responsible for writing this article. Irina Borisovna Samokhvalova Alves was responsible for the pathological exam. Ana Maria de Almeida Paiva Fernandes Rodrigues was responsible for surgery. Maria João Bugalho was the endocrinologist in charge of the patient and was also responsible for the article's review.

References

- 1 Alpañés M, González-Casbas JM, Sánchez J, Pián H & Escobar-Morreale HF. Management of postmenopausal virilization. *Journal of Clinical Endocrinology and Metabolism* 2012 **97** 2584–2588. (<https://doi.org/10.1210/jc.2012-1683>)
- 2 Gandrapu B, Sundar P & Phillips B. Hyperandrogenism in a postmenopausal woman secondary to testosterone secreting ovarian stromal tumor with acoustic schwannoma. *Case Reports in Endocrinology* 2018 **2018** Article ID 8154513. (<https://doi.org/10.1155/2018/8154513>)
- 3 Czyzyk A, Latacz J, Filipowicz D, Podfigurna A, Moszysky R, Jasinski P, Sajdak S, Gaca M, Genazzani AR & Meczekalski B. Severe hyperandrogenemia in postmenopausal woman as a presentation of ovarian hyperthecosis. Case report and mini review of the literature. *Gynecological Endocrinology* 2017 **33** 836–839. (<https://doi.org/10.1080/09513590.2017.1337094>)
- 4 Zhang C, Sung CJ, Quddus MR, Simon RA, Jazaerly T & Lawrence WD. Association of ovarian hyperthecosis with endometrial polyp, endometrial hyperplasia, and endometrioid adenocarcinoma in postmenopausal women: a clinicopathological study of 238 cases. *Human Pathology* 2017 **59** 120–124. (<https://doi.org/10.1016/j.humpath.2016.09.021>)
- 5 Rousset P, Gompel A, Christin-Maitre S, Pugeat M, Hugol D, Ghossain MA & Buy J-N. Ovarian hyperthecosis on grayscale and color Doppler ultrasound. *Ultrasound in Obstetrics and Gynecology* 2008 **32** 694–699. (<https://doi.org/10.1002/uog.6131>)
- 6 Rosenkrantz AB, Popiolek D, Bennett GL & Hecht EM. Magnetic resonance imaging appearance of ovarian stromal hyperplasia and ovarian hyperthecosis. *Journal of Computer Assisted Tomography* 2009 **33** 912–916. (<https://doi.org/10.1097/RCT.0b013e3181a2ec0c>)
- 7 Pascale MM, Pugeat M, Roberts M, Rousset H, Déchaud H, Dutrieux-Berger N & Tourniaire J. Androgen suppressive effect of GnRH agonist in ovarian hyperthecosis and virilizing tumors. *Clinical Endocrinology* 1994 **41** 571–576. (<https://doi.org/10.1111/j.1365-2265.1994.tb01820.x>)

Received in final form 17 July 2020

Accepted 14 January 2021