

REVIEW

Surgical anatomy of the vaginal introitus

Bernard T. Haylen MB, BS, MD, FRANZCOG, FRCOG, CU¹  |**Dzung Vu MB, BS, MD, FRANCO²** |**Audris Wong MB, BCh, BAO, FRANZCOG, FRCOG, MRCPI³**

¹Department of Gynecology, University of New South Wales, Sydney, New South Wales, Australia

²Department of Anatomy, University of Notre Dame, Sydney, New South Wales, Australia

³Department of Obstetrics & Gynecology, Gold Coast University Hospital, Southport, Queensland, Australia

Correspondence

Bernard T. Haylen, University of New South Wales, Suite 904, St Vincent's Clinic, 438 Victoria St, Darlinghurst, Sydney, NSW 2010, Australia.
Email: bernard@haylen.co

Abstract

Aim: The vaginal introitus is the entrance to the vagina, encompassing the anterior and posterior vestibules and the perineum. The surgical anatomy of the vaginal introitus, the lowest level of the vagina, has not been subject to a recent comprehensive examination and description. Vaginal introital surgery (perineorrhaphy) should be a key part of surgery for a majority of pelvic organ prolapse.

Methods: Cadaver studies were performed on the anterior and posterior vestibules and the perineum. Histological studies were performed on the excised perineal specimens of a cohort of 50 women undergoing perineorrhaphy. Included are pre- and postoperative studies which were performed on 50 women to determine the anatomical and histological changes achieved with a simple (anterior) perineorrhaphy.

Results: The vaginal introitus is equivalent to the Level III section of the vagina, measured posteriorly from the clitoris to the anterior perineum then down the perineum to the anal verge. The anterior and posterior vestibules, with nonkeratinizing epithelium, extend laterally to the keratinized epithelium of the labia minora (Hart's line). The anterior vestibule has six anatomical layers while the posterior vestibule has three. The perineum has an inverse trapezoid shape. Perineorrhaphy specimens were a mean 2.9 cm wide and 1.6 cm deep. They show squamous epithelium with loose underlying connective tissue. There were no important structures seen histologically, for example, ligaments or muscles. Microscopically, only 6 (12%) were completely normal with 44 (88%) showing minor changes including inflammation and scarring. Considerable anatomical benefits were achieved with such a perineorrhaphy including a 27.6% increase in the perineal length and a 30.8% reduction in the genital hiatus.

Conclusion: An understanding of the anatomy and histology of the vaginal introitus can assist with performing a simple and effective perineorrhaphy, the main surgical intervention at the vaginal introitus.

KEYWORDS

anterior vestibule, perineorrhaphy, perineum, posterior vestibule, prolapse, vaginal introitus

1 | INTRODUCTION

Vagina comes from the Latin for “sheath,” an organ of copulation that receives the penis during sexual intercourse.¹ The introitus is the entrance (Latin: “intro”—into; “ire”—to go—to go into); here, the vagina as a hollow organ. It represents Level III of the vagina,² that is, those areas distal to the hymen (Figure 1), anterior, lateral and posterior. It incorporates the (i) anterior vestibule: anterior and lateral areas distal to the hymen. Laterally, it extends as far as Hart's line where the labia minora commence; (ii) posterior vestibule: posterior and posterolateral areas distal to the hymen out to Hart's line; (iii) the perineum² (predominantly anterior aspects), from distal margin of posterior vestibule down to anal verge. The emphasis on the word “introitus” acknowledges the areas that might affect vaginal entry.

The word “vestibule” comes from the Latin “vestibulum” meaning “a small cavity or a space at the entrance of a canal.”^{1,3} The vaginal vestibule is the space posterior to the glans clitoridis (clitoris) and between the labia minora,^{1,3} extending posteriorly to the anterior perineum (Figure 2). It can be divided into anterior and posterior vestibule by a horizontal line at the posterior aspect of the hymen.³ The area posterior and inferior to the posterior vestibule and extending to the anal verge (within the yellow line) is defined as the “perineum.” It should be noted that this is the more commonly used clinical definition of perineum which is at variance with the definition used in anatomical texts.^{3–5}

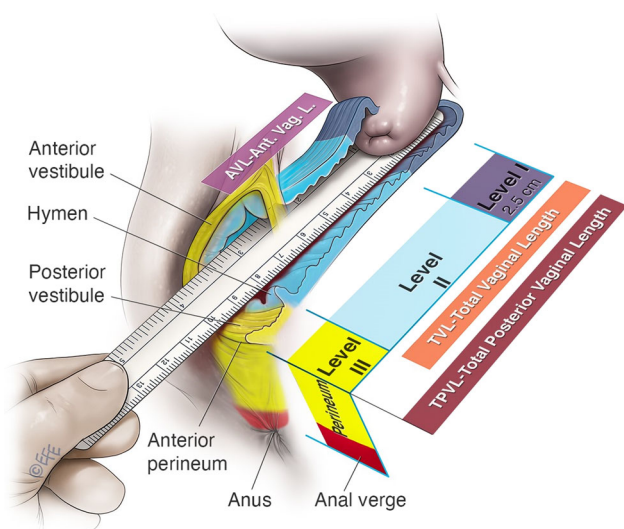


FIGURE 1 Vaginal introitus is Level III of the vagina² incorporating anterior and posterior vestibules³ and the perineum down to the anal verge.

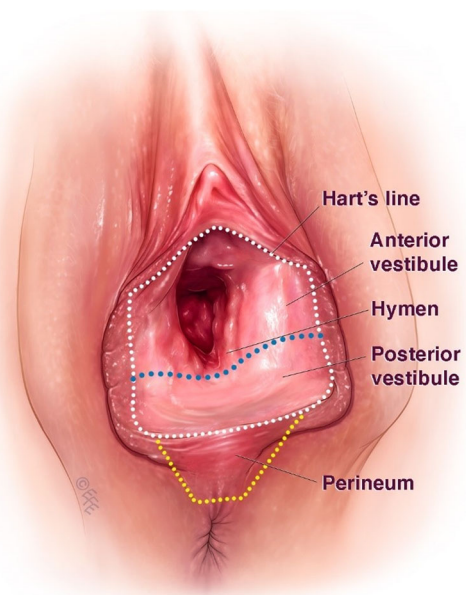


FIGURE 2 Vaginal introitus: anterior and posterior vestibule (as outlined by Hart's line),³ and the perineum (within the yellow line extension to Hart's line to the anal verge).

2 | ANTERIOR VESTIBULE

The anterior vestibule extends posteriorly from the glans clitoridis to the posterior aspects of the hymenal ring and laterally to the start of the labia minora.³ The lateral junction, Hart's line, is where the smoother and shinier transitional appearance of the nonkeratinized stratified squamous epithelium, similar to the vagina, changes to keratinized skin.³ It contains the openings of the vagina, urethra, and the ducts of the greater vestibular glands.³

The overall anatomy and the layers of the anterior vestibule differ significantly from those of the posterior vestibule.³ The anterior vestibule is more fixed anatomically overall and contains the pyriform-shaped erectile bodies known as the vestibular bulbs.³ These do not extend as far posteriorly as the posterior vestibule. The fixity of the anterior vestibule is further enhanced by the insertion of the external urethral orifice and connections with the clitoral complex.³

Anatomical dissection of the *anterior* vestibule (Figure 3) will reveal the following six layers (vs. only three layers posterior to the bulb of the anterior vestibule): (i) skin, (ii) subcutaneous tissue (ScT), (iii) superficial perineal fascia, (iv) bulbospongiosus muscle, (v) bulb, and (vi) perineal membrane.

Although the histology of the vulva is the same as skin on other parts of the body, the anterior vestibule differs in that it is nonkeratinizing epithelium. It contains sebaceous glands which can be numerous. There are,

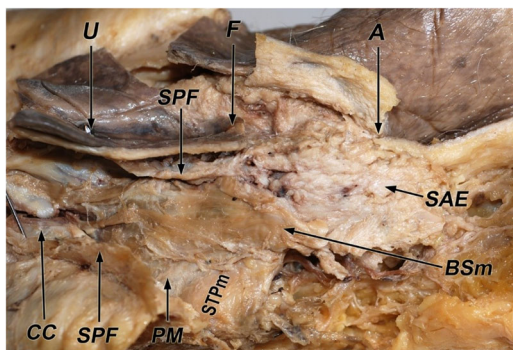


FIGURE 3 Superficial dissection of the anterior and posterior vestibules³: urethra marked by probe (U), crus of the clitoris (CC), superficial perineal fascia (SPF), perineal membrane (PM), superficial transversus perinei muscle (STPm), fourchette (F), bulbospongiosus muscle (BSm), sphincter ani externus (SAE), anus (A). Fuller description in Haylen et al.³

however, generally no eccrine sweat glands or hair follicles. Minor vestibular glands, comprised of acini lined by mucinous columnar epithelium, may also be present. The ducts of the greater vestibular (Bartholin's) glands open into the vestibule at the 4 and 8 o'clock positions. These glands contain acini lined by mucinous columnar epithelium as well as ducts lined by a transitional epithelium with a change to squamous epithelium at the ostia.

Pigmentation of the basal layer is variable and commoner in darker skinned individuals. It may also occur on a background of chronic inflammatory vulval conditions such as lichen sclerosis, lichen simplex chronicus, and psoriasis.

Surgical intervention to the anterior vestibule is uncommon. Bartholin's gland issues an exception

3 | POSTERIOR VESTIBULE

The posterior vaginal vestibule extends posteriorly from the hymen to the anterior perineum and laterally to the junction with the labia minora (Hart's line).³ In women at posterior repair, its mean superoinferior length is 1.8 cm.⁶ There are no clear figures reported for its width.³ There is one anteroposterior measurement, the genital hiatus (GH), which is measured from the middle of the external urethral meatus to the posterior aspect of the hymen.² This will change considerably with a perineal repair (Table 1). GH has been noted to be sensitive to pelvic organ prolapse (POP) changes⁷: it measures around 2.7 cm in women with no significant prolapse or post-POP repair⁷; it measures up to 4.2 cm (mean) in those with Stages III and IV POP⁷ or before a POP repair.

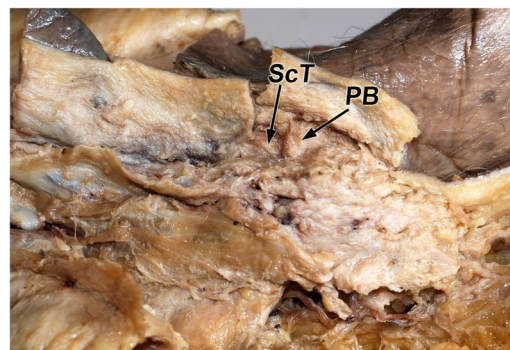


FIGURE 4 Dissection of the posterior vestibule³: subcutaneous tissue (ScT); perineal body (PB). Fuller description in Haylen et al.³

The perineal body (PB), a part posterior vestibule—part perineal measurement, is measured from the posterior margin of the hymen, out to the anterior perineum then down to the midanal opening.^{2,7} It is thus a difficult measurement over two planes at right angles to one another. Its sensitivity to POP changes has been noted to be poor.⁷

The posterior vestibule, like its anterior equivalent is lined by nonkeratinized stratified squamous epithelium similar to the vagina.³ It further highlights the point that the posterior vestibule should be named “vaginal” rather than “vulval.”³ There is no difference between the normal histology of the anterior and posterior vestibules.³

Posterior to the bulb at the end of the anterior vestibule, the *posterior* vestibule (Figure 4) contains only three layers, that is, skin, ScT, and superficial perineal fascia.³ The depth of the skin and ScT in the posterior vestibule is around 1.5 cm.³ This contributes to the elasticity required, particularly for obstetric and sexual function.³

4 | PERINEUM

The area posterior and inferior to the posterior vestibule and extending to the anal verge is defined as the “perineum.” The perineum can be described as an inverse trapezoid shape (Figure 5). It is bounded anteriorly by the distal limit of the posterior vestibule, which measures around 2.0–2.5 cm, or even more in those with obstetric damage. An extension of Hart's line descends posteromedially on each side to the anterolateral aspects of the anal verge. Its posterior boundary is a line passing through the anterior aspect of the anal verge, measuring around 1.0–1.5 cm.

The perineum is more likely to be subjected to obstetric and surgical trauma.³ Such trauma would tend

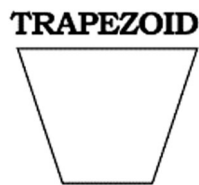

FIGURE 5 Inverse trapezoid

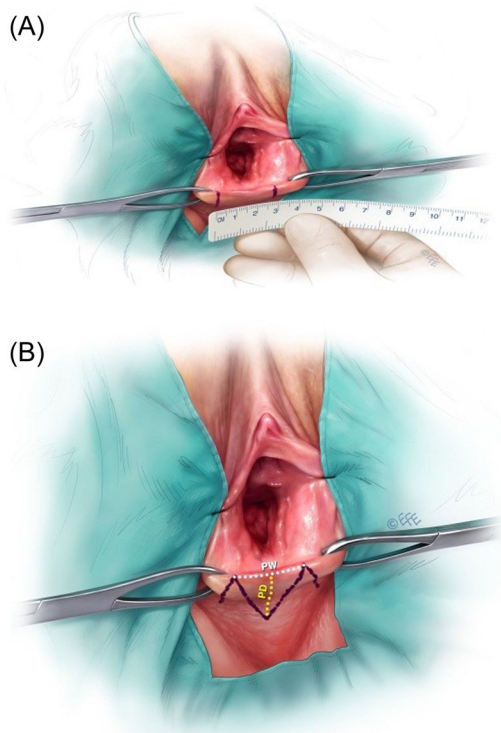


FIGURE 6 (A) Perineal gap (PG): thinned out medial area (cm) between Moynihan forceps placed bilaterally where the labia minora meet the perineum.^{2,3,6,8} (B) Perineorrhaphy width (PW)⁶ and perineorrhaphy depth (PD).

to create defects, particularly at its anterior perineal margin.³ Restoration of the equivalent of the nulliparous state would generally require commencing any repair of the area at its anterior margin (anterior perineum). Deciding to embark on such a restoration would involve (i) an appreciation of available and relevant measurements of perineal defects; (ii) whether the restoration can be simply achieved; (iii) whether the restoration is effective; (iv) whether the restoration is safe histologically.

There are number of available and relevant measurements of perineal defects^{2,8}: (i) *perineal gap (PG)* (Figure 6A): thinned out medial area (cm) between Moynihan forceps placed bilaterally where the labia minora meet the perineum.^{2,3,6,8} This represents more commonly the area of obstetric damage. The excision of

this area and its resuture, we will propose, represents an effective perineorrhaphy. (ii) The area excised, *perineorrhaphy width (PW)* and *depth (PD)* (Figure 6B),⁶ can be measured; (iii) *perineal length (PL)* (Figure 7): distance from the posterior margin of vestibule to the anterior anal verge^{2,6}; (iv) *mid-perineal thickness (MPT)* (Figure 8): thickness of the mid-perineum in the midline^{2,6}; (v) *GH* (Figure 9^{2,6,7}): as noted in the posterior vestibule section.

5 | PERINEORRHAPHY

Perineorrhaphy, generally the final part of a POP repair, is the main surgical intervention involving the perineum. An understanding of the anatomical and histological aspects can assist surgeons in performing a simple and effective perineorrhaphy. For a vaginal POP surgery, its important to include a Level III repair (perineorrhaphy) to reduce the incidence of POP recurrence. It provides or augments posterior support to simultaneous anterior vaginal and vaginal vault repairs.

Level III provides the second greatest posterior vaginal defect (PG: mean 2.9 cm) in the posterior compartment, after Level I (mean 6.0 cm).⁸ Figure 10A shows that the end result, after multiple vaginal deliveries would be the posterior vestibule/anterior perineum no longer looking like the intact state.³ There is thinning anterior and medial to more normal thickness tissue posteriorly, laterally, and inferiorly.³

We propose that a simple and effective perineorrhaphy is performed by simply excising the PG (Figure 10B) and reconstituting it, to obtain a consistent preobstetric appearance (Figure 10C). This perineorrhaphy has been subject to the following anatomical⁶ and histological testing.

The first troche of perineorrhaphy testing is anatomical. At 50 consecutive posterior repairs,⁶ measurements were taken pre- and postoperatively of (i) *PW*⁶ equals *PG*²; (ii) *PD*⁶; (iii) *PL*^{2,6}; (iv) *MPT*^{2,6}; (v) *GH*^{2,6,7}; (vi) total posterior vaginal length (*TPVL*)^{2,8}; (vii) total vaginal length (*TVL*)^{2,8}; and (viii) posterior vestibule length (*PVL—new*).

The perineorrhaphy anatomical results are in Table 1.⁶ The excised perineums, eliminating the 100% of the *PG*, had a mean width 2.9 cm and depth 1.6 cm.⁸ The latter measurement means that, on average, the anterior 55% of the perineum was involved. Other anatomical advantages were a 27.6% mean increase in *PL* (from mean 2.9 cm to mean 3.7 cm); a 30.8% reduction in the *GH* (from mean 3.9 cm to mean 2.7 cm); a 57.1% increase in *MPT* (from mean 0.7 cm to mean 1.1 cm).⁸ There was no reduction in the *PVL*.

Marker	Pre-OP (cm)	Post-OP (cm)	Change
Perineorrhaphy width (PW)	2.9 (1.5–5.5)	0.0	100% ↓
Perineorrhaphy depth (PD)	1.6 (0.8–2.0)	0.0	100% ↓
Perineal length (PL)	2.9 (1.5–4.5)	3.7 (2.0–5.5)	27.6% ↑
Mid-perineal thickness (MPT)	0.7 (0.4–1.1)	1.1 (1.0–1.6)	57.1% ↑
Genital hiatus (GH)	3.9 (2.3–6.5)	2.7 (2.0–4.5)	30.8% ↓
Total posterior vaginal length (TPVL)	9.2 (6.0–12.5)	8.9 (5.7–11.5)	3.3% ↓
Total vaginal length (TVL)	7.5 (3.5–11.5)	7.2 (4.0–9.5)	4.0% ↓
Posterior vestibule length (PVL)	1.7	1.7	0.0%

TABLE 1 Changes in perineal anatomical markers before and after perineorrhaphy⁶

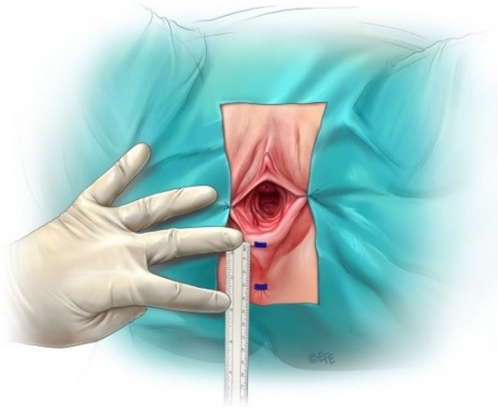


FIGURE 7 Perineal length (PL): distance from posterior margin of vestibule to anterior anal verge.^{2,6}

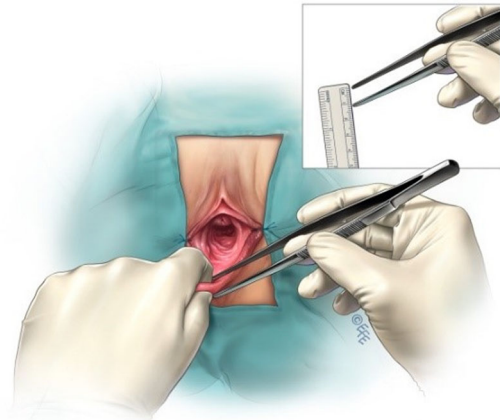


FIGURE 8 Mid-perineal thickness (MPT): thickness (cm) of the mid-perineum in the midline.^{2,6}

The second troche of perineorrhaphy testing is histological. This analysis (unpublished) was performed by specialist gynecological pathologists on a second cohort of 50 consecutive women (mean age 63, mean parity 2.6, mean weight 71 kg) undergoing posterior repairs (a subgroup of the 300 women in Haylen et al.⁸). The excised perineorrhaphy specimens (mean PW 2.7 cm, mean PD 1.5 cm) consisted of squamous epithelium with loose underlying connective tissue. No important structures, for example, ligaments or muscle, were seen histologically. Macroscopically, no significant abnormality was observed.

Microscopically, only 6 (12%) were completely normal with 44 (88%) showing minor changes: (i) mild keratosis in 24 (48%); (ii) scarring in the underlying connective tissue in 17 (34%); (iii) inflammation in 24 (48%) with lichen sclerosus in 6 (12%). Anterior perineal excision appears histologically safe and appropriate with no important structures contained in the excised tissue and 88% showing microscopic histological change, the excision of which might well be beneficial.

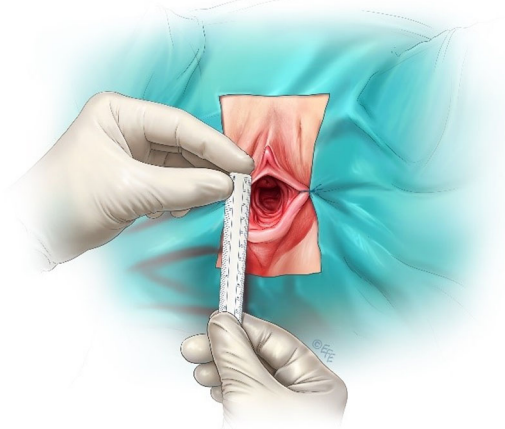


FIGURE 9 Genital hiatus: middle of the external urethral meatus to the posterior aspect of the hymen.^{2,6,7}

While clear descriptions of perineal anatomy are not abundant in the literature, muscle and ligaments are stated as being involved in the area.^{9–13} It has been stated that the anterior perineum contains the PB and muscles including

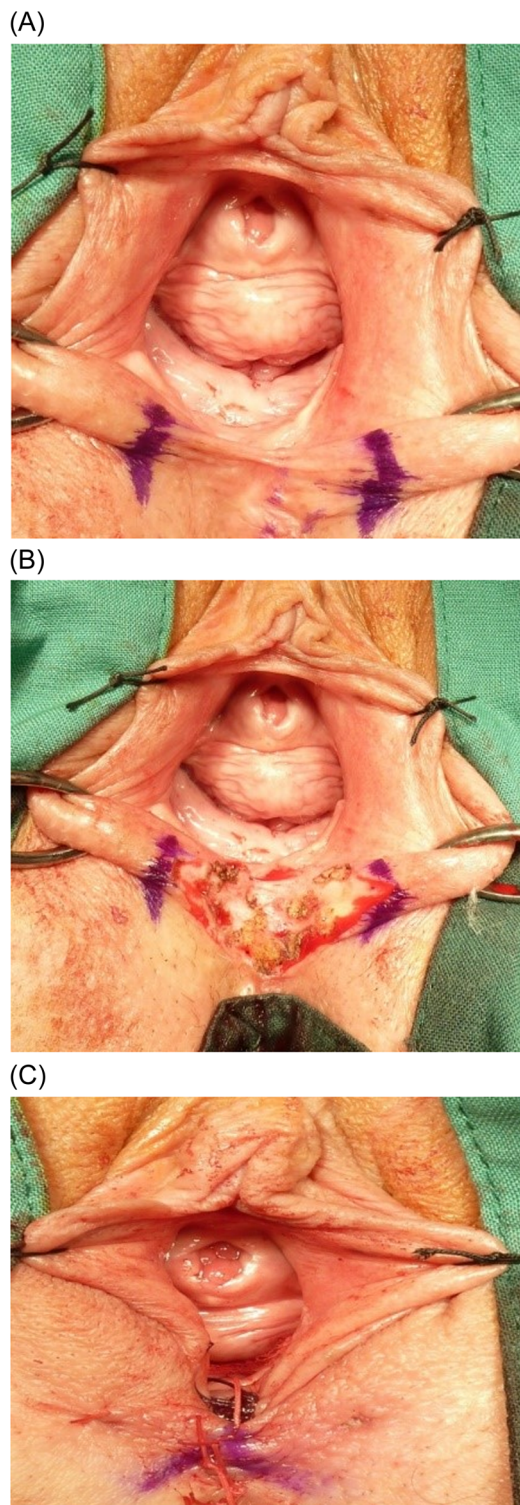


FIGURE 10 (A) Perineal gap (before excision); (B) perineal gap (after excision); (C) reconstituted perineum.

the superficial and deep transverse perineal muscles.¹⁰ Our experience did not support this latter finding though we were excising macroscopically “thinned-out” tissue, medial and anterior to more normal perineum. It is possible that this more macroscopically normal tissue laterally and

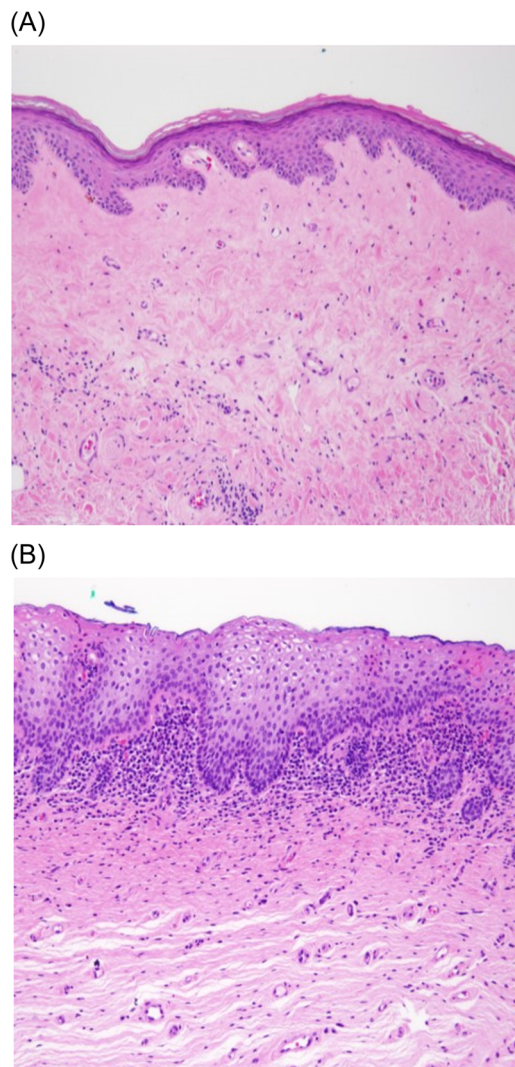


FIGURE 11 Excised perineum showing (A) lichen sclerosis; (B) inflammation and scarring.

inferiorly to that excised, could have contained these more important structures (Figure 11).

Of the 88% with microscopic histologic changes, epithelial and connective tissue involvement occurred in 70% and 64% cases, respectively. Sixty percent had multiple changes with 43% having both epithelial and connective tissue abnormalities. Many of these changes including scarring will represent PB disruption, episiotomy sequelae, and other childbirth perineal trauma.^{6,14,15} Other changes such as atrophy and inflammation might be more likely to occur after menopause. These types of histological findings were not totally unexpected in this group of women in this clinical setting. The only slightly unexpected finding was the 12% incidence of lichen sclerosis, potentially premalignant.

Current surgical practice shows considerable uncertainty regarding the issue of perineorrhaphy. In one survey,¹⁶ GH size and concomitant prolapse procedures ranked highest in surgeons' decision to perform a

perineorrhaphy.¹⁶ Significant heterogeneity exists in the indications for and in the recommended technique such as where, in relation to the hymen it should be performed and whether muscle should be included.¹⁶

We hope to have demonstrated that a simple perineorrhaphy, as described above, is histologically safe and anatomically effective. Perineorrhaphy specimens showed squamous epithelium with loose underlying connective tissue with no important structures. Considerable anatomical benefits can be achieved by such a perineorrhaphy with the increase in PL and reduction in GH.

6 | CONCLUSIONS

The vaginal introitus is equivalent to the Level III section of the vagina, measured posteriorly from the clitoris, through anterior and posterior vestibules to the anterior perineum, then down the perineum to the anal verge. It differs from the original (1992) description of Level III,¹⁷ though it is consistent with a more recent (2016)² outline (Figure 1). It acknowledges those areas that might affect vaginal entry. The anterior and posterior vestibule with nonkeratinizing epithelium extend laterally to the keratinized epithelium of the labia minora (Hart's line). The anterior vestibule has six anatomical layers while the posterior vestibule has three. The perineum is an inverse trapezoid shape with its superficial 1.5 cm comprising skin and Sct.

Perineorrhaphy, generally the final part of a posterior POP repair, is the main surgical intervention involving the perineum. A simple perineorrhaphy is histologically safe and anatomically effective. Its use can augment posterior vaginal vault support to anterior vaginal and vaginal vault repairs and prevent the incidence of recurrent POP.

Perineorrhaphy specimens (excision of PG) show squamous epithelium with loose underlying connective tissue. There were no important structures, for example, ligaments or muscle seen histologically. Microscopically, only 6 (12%) were completely normal with 44 (88%) showing minor changes including inflammation and scarring. Considerable anatomical benefits can be achieved by such a perineorrhaphy including a 27.6% increase in the PL and a 30.8% reduction in the GH.

AUTHOR CONTRIBUTIONS

Bernard T. Haylen, Dzung Vu, and Audris Wong contributed to the development concept, writing, and review of the paper.

ACKNOWLEDGMENTS

The authors acknowledge the fine diagrams of Levent Efe (Levent@leventefe.com.au) and the gynecological histopathologists from Douglas Hanly Moir, North Ryde,

Sydney, Australia: Professor Annabelle Farnsworth, Dr Jennifer Roberts, Dr Clare Biro, Dr Suzanne Hyne and Dr Debra Jensen. The histopathological photographic images of selected cases were kindly provided by Professor Peter Russell, also at Douglas Hanly Moir. Open access publishing facilitated by University of New South Wales, as part of the Wiley - University of New South Wales agreement via the Council of Australian University Librarians.

CONFLICTS OF INTEREST

The authors declare no conflicts of interest.

DATA AVAILABILITY STATEMENT

The data that support the findings of this study are available from the corresponding author upon reasonable request.

ORCID

Bernard T. Haylen  <https://orcid.org/0000-0001-5436-2435>

REFERENCES

1. Stedman T. *Stedman's Medical Dictionary*. 28th ed. Lippincott Williams & Wilkins; 2006.
2. Haylen BT, Maher CF, Barber MD, et al. An International Urogynecological Association (IUGA)/International Continence Society (ICS) joint report on the terminology for pelvic organ prolapse. *NeuroUrol Urodyn*. 2016;35(2):137-168; *Int Urogynecol J*. 27(2):165-194. Dual publication.
3. Haylen BT, Fischer G, Vu D, Tse K. The vaginal vestibule. Assessing the case for an anterior and posterior division. *NeuroUrol Urodyn*. 2017;36(4):979-983. doi:10.1002/nau.23064
4. Federative Committee on Anatomical Terminology. *Terminologia Anatomica: International Anatomical Terminology*. Thieme; 1998.
5. Standring S, ed. *Gray's Anatomy: The Anatomical Basis of Clinical Practice*. 40th ed. Churchill Livingstone Elsevier; 2008.
6. Haylen BT, Younis M, Naidoo S, Birrell W. Perineorrhaphy quantitative assessment (Pe-QA). *Int Urogynecol J*. 2015;26:539-544.
7. Dunivan GC, Lyons KE, Jeppson PC, et al. Pelvic organ prolapse stage and relationship to genital hiatus and perineal body measurements. *Fem Pelvic Med Reconstruct Surg*. 2016;22(6):497-450.
8. Haylen BT, Naidoo S, Kerr SJ, Chiu HJ, Birrell W. Posterior vaginal compartment repairs: where are the main anatomical defects? *Int Urogynecol J*. 2016;27:741-745.
9. Stein TA, DeLancey JOL. Structure of the perineal membrane in females: gross and microscopic anatomy. *Obstet Gynecol*. 2008;111(3):686-693.
10. Kato M, Matsubara A, Murakami G, et al. Female perineal membrane: a study using pelvic floor semi-serial sections 324 from elderly nulliparous and multiparous women. *Int Urogynecol J*. 2008;19(12):1663-1670.
11. Soga H, Nagata I, Murakami G, et al. A histo-topographic study of the perineal body in elderly women: the 327 surgical applicability of novel histological findings. *Int Urogynecol J*. 2007;18(12):1423-1430.

12. Hudson CN, Sohaib SA, Shulver HM, Reznek RH. The anatomy of the perineal membrane: its relationship to injury in childbirth and episiotomy. *Aust N Z J Obstet Gynaecol.* 2002;42(2):193-196.
13. Woodman PJ, Graney DO. Anatomy and physiology of the female perineal body with relevance to obstetrical injury and repair. *Clin Anat.* 2002;15(5):321-334.
14. Wagenlehner FME, Del Amo E, Santoro GA, Petros P. Live anatomy of the perineal body in patients with third-degree rectocele. *Colorectal Dis.* 2013;15(11):1416-1422.
15. Kalis V, Chaloupka P, Turek J, Rokyta Z. The perineal body length and injury at delivery. *Ceska Gynecol.* 2005;70(5):355-361.
16. Kanter G, Jeppson PC, McGuire BL, Rogers RG. Perineorrhaphy: commonly performed but poorly understood. A survey of surgeons. *Int Urogynecol J.* 2015;12:1797-1801.
17. DeLancey JOL. Anatomical aspects of vaginal eversion after hysterectomy. *Am J Obst Gynecol.* 1992;166:117-124.

How to cite this article: Haylen BT, Vu D, Wong A. Surgical anatomy of the vaginal introitus. *NeuroUrol Urodyn.* 2022;41:1240-1247.
[doi:10.1002/nau.24961](https://doi.org/10.1002/nau.24961)