

CASE REPORT



## Case report: giant cell arteritis in a patient with carotid atherosclerosis – a diagnostic dilemma

Beenish Fayyaz 

Internal Medicine, Greater Baltimore Medical Center, Towson, MD, USA

### ABSTRACT

Carotid atherosclerosis and giant cell arteritis (GCA) are two distinct medical conditions with an overlapping clinical spectrum of vascular symptoms such as vision loss and ischemic stroke. This is because both diseases cause arterial ischemia with a predilection for carotid vasculature. In addition, high-vascular risk individuals who are diagnosed with GCA are usually elderly with age >55 years with high-vascular risk and thus can have underlying atherosclerosis. All these factors can pose a diagnostic dilemma for the physicians as GCA is a medical emergency which if left untreated can result in significant morbidity and mortality. Thus, it is important to avoid attributing occlusive arterial disease in elderly patients to atherosclerosis alone because some may have GCA. We present a case report in which presence of diffuse atherosclerosis was a major pitfall while making a timely diagnosis of GCA.

### ARTICLE HISTORY

Received 3 January 2018  
Accepted 26 March 2018

### KEYWORDS

Carotid stenosis; atherosclerosis; giant cell arteritis; jaw claudication; polymyalgia rheumatic; anterior ischemic optic neuropathy; Color-duplex ultrasound

## 1. Introduction

Diagnosing giant cell arteritis (GCA) in a patient with established atherosclerotic carotid disease can be challenging as both entities can cause carotid stenosis with similar presenting symptoms. This fact is supported by a literature review on previously reported cases [1]. Therefore, GCA should be presumed as a possibility in all elderly patients more than 50 years of age who present with a new-onset headache and vision changes [2]. A high clinical suspicion should be maintained in such individuals while understanding the subtle clinical differences in GCA and carotid atherosclerosis such as vascular distribution and ophthalmological findings. Criteria established by American College of Rheumatology (ACR) [3] can further aid in the diagnosis according to which a patient is deemed as having GCA if three of the following are present: 1) age over 50 years; 2) new-onset localized headache; 3) temporal artery tenderness or reduced pulse; 4) erythrocyte sedimentation rate of 50 mm/hr or higher; and 5) temporal artery biopsy demonstrating mononuclear infiltration or granulomatous inflammation.

Here, we present the case of an 81-year-old gentleman whose symptoms of vision loss and headache were attributed to carotid stenosis secondary to atherosclerosis but later was found to have GCA.

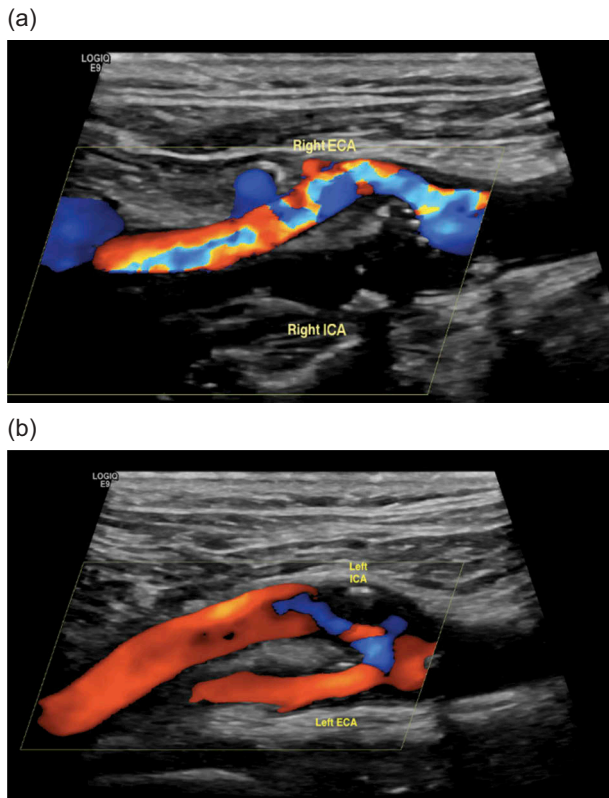
## 2. Case

An 81-year-old gentleman with past medical history of diabetes, hypertension, and peripheral vascular disease

presented to the emergency department with acute onset right-sided vision loss. The patient had been in his usual state of health 4 weeks prior when he experienced transient visual loss in his right eye and later started having left-sided headache along with difficulty in chewing food. He underwent a color-duplex ultrasound as outpatient for the evaluation of his symptoms which showed undetectable blood flow indicative of complete occlusion in right internal carotid artery and critical stenosis of more than 70% in left internal carotid artery (ICA). Bilateral common (CCA) and external carotid arteries (ECA) were patent though diffusely atherosclerotic with an estimated plaque burden more than 50% (Figures 1(a,b)).

Based on the carotid duplex findings, he was diagnosed to have symptomatic carotid stenosis secondary to wide-spread atherosclerosis. His right ICA was not considered amenable to surgery and after a discussion with vascular surgery, he underwent a left carotid endarterectomy with no immediate complications. However, he continued to have persistent symptoms with progressive deterioration. He also noticed weight loss, anorexia and morning stiffness in his shoulders. On the morning of presentation, he lost complete vision in his right eye while experiencing blurry vision in his left eye. He was examined by his ophthalmologist who detected ischemic optic changes highly suggestive of GCA and thus referred him to the emergency department with recommendations to be immediately started on high dose IV corticosteroids.

His vitals, on presentation, were as follows: BP 126/72 mm Hg, Pulse 92/min and afebrile. Detailed



**Figure 1.** (a) Occluded right ICA with absent flow seen on color-duplex. Right ECA has adequate flow although severe atherosclerosis is evident based on turbulent color flow images. (b) Color-duplex images of left carotid system with >70 % critical stenosis in proximal left ICA and a patent left ECA.

examination revealed cachexia along with left temporal and shoulder girdle tenderness. Pulses were diminished in all extremities except left dorsalis pedis which was absent. Bilateral carotid bruits were also appreciated. Visual acuity was noted to be 0/20 and 2/20 in the right and left eyes respectively. Pupillary reflex was absent on right side while sluggish on left side. Rest of the neurological system was grossly intact. Initial blood workup showed ESR of 90 mm/hr and CRP of 9.06 while complete blood cell count and metabolic profile was normal. CT head didn't show any acute abnormality apart from mild cortical atrophy. He was started on IV pulse corticosteroids after a discussion with rheumatology and neuro-ophthalmology teams which led to remarkable improvement in his vision and headache within 24 h of treatment. His blood glucose levels were found to be elevated likely due to steroids but were managed aggressively with insulin therapy with good response. He completed 3-day course of IV pulse steroids after which he was put

on once daily oral prednisone at a dose of 1mg/kg body weight. Plan was made to keep him on a slow steroid taper after stabilization with future immunosuppressive therapy.

To confirm the diagnosis, bilateral temporal biopsy was scheduled. Carotid ultrasound was repeated to assess the vasculature in view of the recent carotid endarterectomy. It showed left common and ICA dissection which was confirmed on CT angiogram and MRA of the neck. At this point, it was decided to delay the biopsy and heparin infusion was administered. Subsequently, left carotid angioplasty and stenting were performed with no immediate complications. The patient continued to improve in terms of headache, jaw claudication and left-sided vision changes. However, he was unable to regain vision in his right eye due to irreversible optic ischemia. After the patient's condition had stabilized, he was discharged with advice to follow closely with rheumatology, vascular surgery, and ophthalmology as outpatient. He was also placed on short term dual antiplatelet therapy along with a statin. He underwent a bilateral temporal artery biopsy as outpatient which confirmed active GCA.

### 3. Discussion

Carotid artery disease is most commonly caused by atherosclerosis in which there is formation of an atheromatous plaque on the arterial wall of common carotid, ICA or ECA. Such patients develop symptoms (Table 1) either due to thromboembolization secondary to plaque rupture or progression of the plaque with resultant critical stenosis/occlusion.

However, non-atherosclerotic carotid disease can have similar symptoms with rather uncommon causes such as giant cell arteritis (GCA) [2,4].

GCA is a rheumatological disorder causing inflammation of medium- and large-sized vessels such as the aorta and its branches. It is also called Temporal arteritis as it commonly involves superficial temporal and maxillary artery leading to classical symptoms of headache and jaw claudication respectively. Other manifestations are given in Table 2.

GCA causes arterial wall inflammation with subsequent carotid stenosis/occlusion induced ischemia leading to similar symptoms as atherosclerotic carotid disease. This makes the diagnostic process challenging especially if GCA occurs in an individual with high-vascular risk. Yet appropriate and prompt diagnosis is critical to enable timely intervention and

**Table 1.** Symptoms of Carotid artery disease based on territory involved.

Branches involved	Symptoms
Common carotid artery	Any of the symptoms given below depending on the branches involved and presence of collaterals
External carotid artery	
Internal carotid artery	
	Headache, neck pain, jaw pain/clauidication
	Transient ischemic attack/stroke presenting as visual changes, motor/sensory loss, aphasia

**Table 2.** Clinical manifestations of GCA [2,5].

Clinical manifestations	Incidence
<b>Vascular:</b>	
New onset headache	60–90%
Scalp tenderness (temples or occiput)	40–70%
Jaw/tongue claudication	30–50%
Limb claudication	5–15%
Mesenteric ischemia	10–20%
Aortic dilatation/dissection	20–30%
<b>Ophthalmological:</b>	
Vision loss (Transient or permanent)	15–20%
Diplopia	10%
<b>Neurological:</b>	
Stroke	3–7%
Neuropathy (Cranial or peripheral)	1–2%
Spinal myelopathy	Rare
Dementia	Rare
Systemic symptoms (Fever, anorexia, weight loss)	20–50%

prevent significant morbidity. Our case report is a perfect example of this clinical dilemma when a delayed diagnosis resulted in dire consequences.

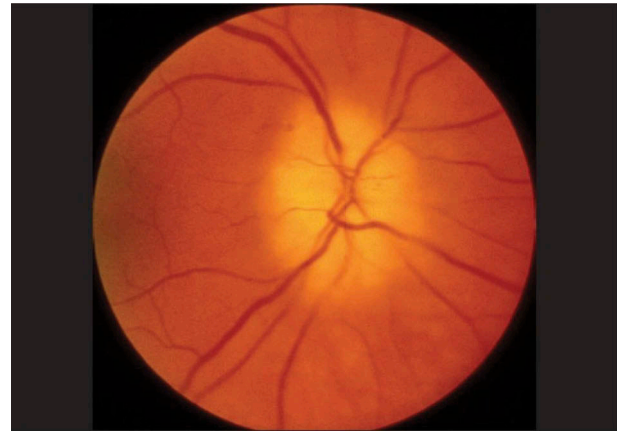
In retrospect, the clinical course of our patient had many important highlights suggestive of GCA which can help us understand the diagnostic approach in individuals with vasculopathies.

Our patient developed complete vision loss in his right eye and partial loss in his left eye. A detailed ophthalmological examination suggested Anterior Ischemic Optic Neuropathy (AION), a condition that occurs due to optic nerve arterial ischemia [6]. GCA causes arteritic form of AION (A-AION) (Figure 2(a)) in which the optic disc develops a characteristic chalky white appearance with subsequent diffuse edema. Non-arteritic form of AION (NA-AION) (Figure 2(b)) causes similar symptoms but the optic disc is more hyperemic and develops sectorial edema [7].

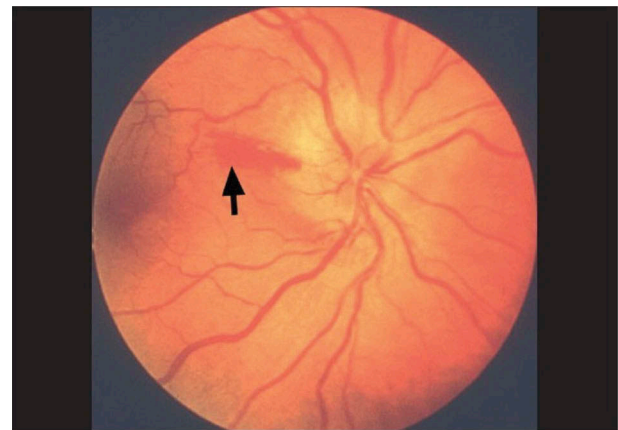
Amaurosis fugax is an important early visual symptom in GCA which can be seen in up to 30% of patients as reported by Hayreh et al. [7,8]. Similar visual manifestations were observed in our patient in whom an ophthalmological exam, if done earlier, might have helped in making the right diagnosis.

Superficial temporal and maxillary arteries arise from ECA and stenosis of these vessels due to any cause such as GCA, atherosclerosis, thromboembolism result in ischemia of facial and masticatory muscles leading to headache, jaw pain, or claudication [9]. Our patient was thought to have these symptoms due to carotid atherosclerosis. However, as mentioned above, color-duplex ultrasound showed diffuse atherosclerosis and critical stenosis of left ICA but no significant disease of left ECA. This fact indicated further investigation for an alternate diagnosis such as GCA which can cause ‘skip’ lesions of arteries [10] and can be missed on a limited ultrasonography study. Recent data has shown promising results regarding use of color-duplex ultrasonography in diagnosis of GCA but only if done in detail on all the large arteries including temporal artery. This imaging modality can pick up signs such as ‘halo’

(a)

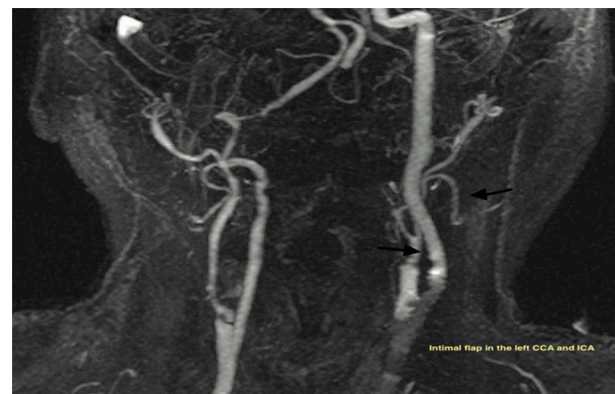


(b)



**Figure 2.** (a) Fundus photograph of right eye with A-AION, showing chalky white optic disc and generalized edema [6]. (b) Right fundus photograph with NA-AION showing upper temporal optic disc edema and hyperemia, with a splinter hemorrhage (arrow)[6].

sign due to inflammatory edema of the arterial wall with sensitivity and specificity as high as 85% and 92%, respectively [11]. Alternatively, high resolution MRI can be done which has shown similar results [12]. Our patient did not get a temporal artery ultra-



**Figure 3.** Magnetic Resonance Arteriogram of the neck vessels depicting intimal flap seen in left common and internal carotid arteries. Segments of left ICA and ECA with luminal irregularities also seen (arrows).



sound but was found to have segmental irregular beaded appearance of left ICA and ECA secondary to arteritis on MRA neck (Figure 3).

Furthermore, the complaints of shoulder achiness and stiffness were highly suggestive of polymyalgia rheumatica (PMR) which is another rheumatic condition associated with GCA. 40–60% of patients with GCA can have PMR on initial presentation while 16–21% of patients with PMR develop GCA during their lifetime. [13]

The treatment of GCA is high dose corticosteroids with most patients showing rapid clinical improvement [14] as was the case with our patient in whom we were able to salvage the left eye function. Although, it can be argued that left carotid dissection as a complication of carotid endarterectomy could present with similar symptoms, it is prudent to note that patient improved with corticosteroids while angioplasty with stenting were performed later.

This case also highlights the role of temporal artery biopsy in establishing the diagnosis of GCA especially in patients with concomitant atherosclerotic disease. This test is considered to be the gold standard technique with a negative predictive value of more than 90%. However, the sensitivity is only 87% while false negative rates have been reported to be as high as 30 to 44 percent in patients who fulfill the ACR criteria. This is due to the fact that GCA produces 'skip' lesions due to segmental arterial wall inflammation [10]. Considering these limitations, biopsy can be avoided especially if patient already fulfills ACR criteria. However if unavoidable, a bilateral temporal artery biopsy should be performed while acquiring a longer biopsy specimen. In addition, biopsy should preferably be combined with an imaging technique such as ultrasonography which can help identify the proper arterial segment.

#### 4. Conclusion

Carotid stenosis secondary to atherosclerosis is a common medical condition. However, there can be unique cases of carotid stenosis due to an uncommon cause such as GCA thus necessitating a high clinical suspicion. Our patient's history of diabetes, hypertension and peripheral vascular disease led to a presumptive diagnosis of carotid stenosis secondary to diffuse atherosclerosis. This diagnosis was then revised to GCA on a detailed ophthalmological examination. We believe that he did have severe atherosclerotic carotid disease but the acute onset symptoms were likely due to superimposed GCA. Such complicated patients need to have a more

aggressive diagnostic approach in form of detailed imaging and temporal artery biopsy so as to improve the clinical outcomes.

#### Disclosure statement

No potential conflict of interest was reported by the author.

#### ORCID

Beenish Fayyaz  <http://orcid.org/0000-0002-7837-6580>

#### References

- [1] Vahdani K, Giasin O, Makrygiannis G. Jaw claudication secondary to carotid occlusive disease [Letter to Editor]. *BMJ*. 2015 [Cited on 2018 29 Mar]. Available from: <https://www.bmj.com/content/350/bmj.h1154/rr-0>.
- [2] Smith JH, Swanson JW. Giant cell arteritis. *Headache*. 2014;54:1273–1289.
- [3] Hunder GG, Bloch DA, Michel BA, et al. The American College of Rheumatology 1990 criteria for the classification of giant cell arteritis. *Arthritis Rheum*. 1990;33(8):1122–1128.
- [4] Brott TG, Halperin JL, Abbara S, et al. 2011 ASA/ACCF/AHA/AANN/AANS/ACR/ASNR/CNS/SAIP/SCAI/SIR/SNIS/SVM/SVS guideline on the management of patients with extracranial carotid and vertebral artery disease: executive summary. *Stroke*. 2011;42(8):e420–463.
- [5] Paraskevas KI, Boumpas DT, Vrentzos GE, et al. Oral and ocular/orbital manifestations of temporal arteritis: a disease with deceptive clinical symptoms and devastating consequences. *Clin Rheumatol*. 2007;26(7):1044–1048.
- [6] Hayreh SS. Anterior ischemic optic neuropathy. *Clin Neurosci*. 1997;4(5):251–263.
- [7] Hayreh SS. Management of ischemic optic neuropathies. *Indian J Ophthalmol*. 2011;59(2):123–136.
- [8] Hayreh SS, Podhajsky PA, Zimmerman B. Ocular manifestations of giant cell arteritis. *Am J Ophthalmol*. 1998;125:509–520.
- [9] Janssens MA, Van Thielen TH, Van Veer HG. Jaw claudication as a result of carotid artery disease. *Acta Chir Belg*. 2008;108(4):438–440.
- [10] Banz Y, Stone JH. Why do temporal arteries go wrong? Principles and pearls from a clinician and a pathologist. *Rheumatology*. 2018;57(suppl. 2):3–10.
- [11] LeSar CJ, Meier GH, DeMasi RJ, et al. The utility of color duplex ultrasonography in the diagnosis of temporal arteritis. *J Vasc Surg*. 2002;36(6):1154–1160.
- [12] Bley TA, Reinhard M, Hauenstein C, et al. Comparison of duplex sonography and high-resolution magnetic resonance imaging in the diagnosis of giant cell (temporal) arteritis. *Arthritis Rheum*. 2008;58:2574–2578.
- [13] Kermani TA, Warrington KJ. Polymyalgia rheumatica. *Lancet*. 2013;381(9860):63–72.
- [14] Weyand CM, Goronzy JJ. Giant-cell arteritis and polymyalgia rheumatica. *N Engl J Med*. 2014;371:50–57.