



## Bladder diverticulectomy using a pre-peritoneal, *trans-vesicle* approach with the SP platform: A novel approach

Michael Tonzi, MD<sup>\*</sup>, Mathew J. Watson, Amar Singh

UT Erlanger Urology, Erlanger Medical Mall, 979 E 3rd St, Chattanooga, TN, 37403, United States

### ARTICLE INFO

#### Keywords:

Robotic  
Partial cystectomy  
Single-port  
Bladder cancer  
Pre-peritoneal

### ABSTRACT

A 64-year-old male with a history of urothelial carcinoma was found to have recurrence of his disease inside of a narrow neck bladder diverticulum on surveillance cystoscopy. The da Vinci Single Port robotic system was used to perform an extraperitoneal, *trans-vesicle* partial cystectomy with en-bloc resection. To our knowledge, this is the initial case report of a *trans-vesicle* resection using the da Vinci Single Port robotic system, and provides an alternative to traditional minimally invasive approaches.

### Introduction

Partial cystectomy has long been utilized for a variety of benign and malignant conditions. This technique is especially useful for bladder cancer that is localized to a diverticulum. Previous reports have demonstrated decreased hospital time and decreased morbidity in robotic assisted partial cystectomy compared to traditional open partial cystectomy. Herein, we present the first ever case of a robotic assisted laparoscopic partial cystectomy using the da Vinci Single Port robotic system via an entirely pre-peritoneal approach.

### Case presentation

A 64-year-old male was referred for recurrence of his BCG refractory non-muscle invasive urothelial carcinoma. The patient demonstrated recurrence on routine cystoscopy within a narrow neck bladder diverticulum that was not amenable to TUR. Radical cystectomy was offered, however the patient was adamant that his bladder be spared. Thorough investigation including random biopsy of the bladder and cross-sectional imaging revealed no further evidence of disease or metastasis. We performed an pre-peritoneal, *trans-vesicle* robotic assisted laparoscopic partial cystectomy including en-bloc excision of the bladder diverticulum.

The procedure began with cystoscopy, which confirmed the presence of a papillary lesion within the bladder diverticula immediately posterior to the right ureteral orifice (Fig. 1). A 5-Fr catheter was placed into the right ureter to aid in intra-operative ureteral identification. A

urethral catheter was placed and clamped.

A 3 cm midline infra-umbilical incision was made, and the space of Retzius was developed. A small cystotomy was made at the bladder dome far from the diverticulum in order to gain access to the bladder. Stay sutures were used to advance the bladder to the level of the skin in order to minimize tumor spillage. A gel port was placed into the bladder through this midline cystotomy. The robot port was placed into the gel port. An 8 mm assistant Airseal trocar was placed through the abdominal wall lateral to the midline incision, and advanced into the bladder through a separate cystotomy. Care was taken to ensure this trocar did not violate the peritoneum. The bladder was insufflated, and the robot was docked.

The bladder diverticulum was closed using 3-0 V-lock suture. This was done to not only prevent potential tumor spillage, but also to provide a suture tail to facilitate counter traction (Fig. 2A–C). The diverticulum was carefully dissected from within the bladder. After the entire diverticulum was removed en-bloc, the defect was closed with running 3-0 V-lock suture (Fig. 2D–F). The specimen was removed and the robot was undocked. The entry cystotomy was closed in two layers. Fascia and skin were closed. The 5-french pollack catheter was removed, leaving a urethral catheter to drainage. Please refer to the accompanying video supplement for further detail (Video 1).

The patient tolerated the procedure without complications. Total operative time was 112 minutes. Estimated blood loss was 50mL. The patient was kept overnight for observation and discharged on post-operative day 1 with a urethral catheter in place. He was seen on postoperative day 14 with a cystogram, which showed no evidence of

<sup>\*</sup> Corresponding author.

E-mail address: [michael.tonzi@erlangers.org](mailto:michael.tonzi@erlangers.org) (M. Tonzi).

<https://doi.org/10.1016/j.eucr.2021.101753>

Received 21 May 2021; Received in revised form 7 June 2021; Accepted 9 June 2021

Available online 11 June 2021

2214-4420/© 2021 Published by Elsevier Inc. This is an open access article under the CC BY-NC-ND license (<http://creativecommons.org/licenses/by-nc-nd/4.0/>).

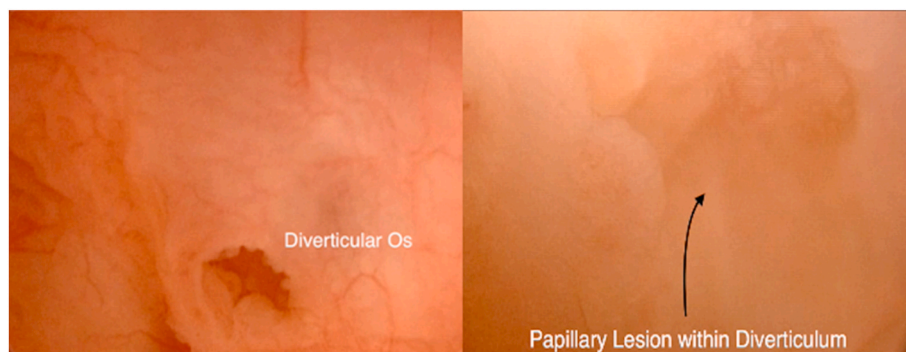


Fig. 1. Cystoscopy demonstrating diverticular ostium with papillary lesion demonstrated internally.

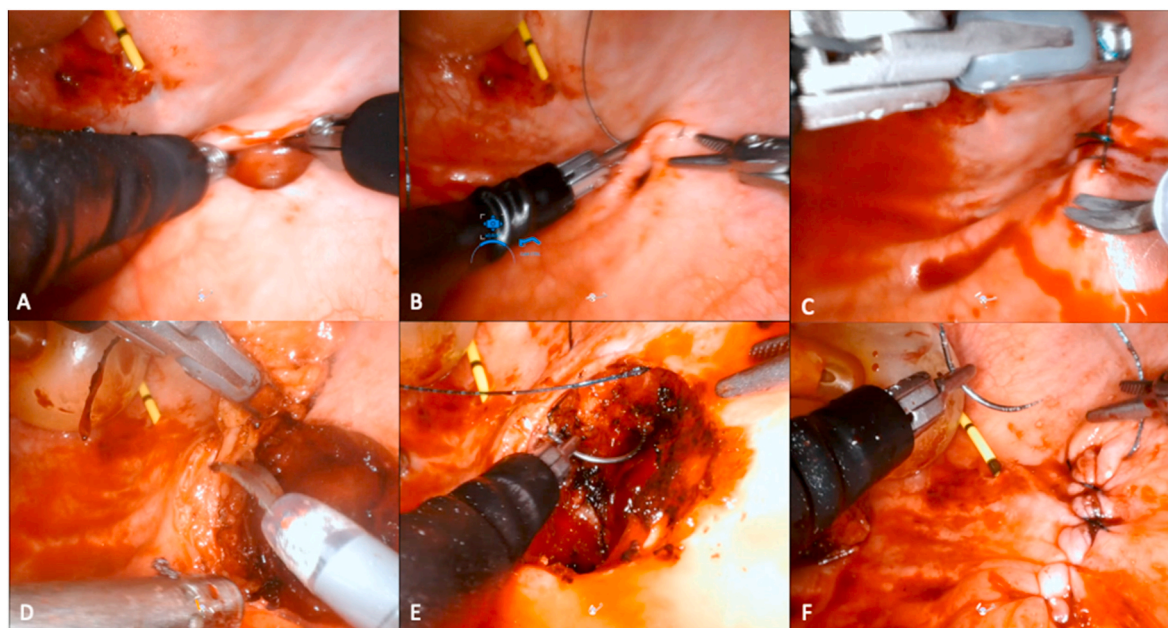


Fig. 2. (A–C) Diverticulum identified and ostium closed with V-lock suture. (D) Excision of diverticulum with enclosed lesion. (E–F) Cystorrhaphy.

contrast extravasation. His urethral catheter was removed, and he passed a trial of void.

Final pathology resulted as high-grade T1 papillary urothelial carcinoma with micropapillary features. Surgical margins were negative. Patient was offered an additional course of BCG, however he elected to undergo surveillance. At six months he has not had any complications or recurrence on office cystoscopy.

## Discussion

Robotic assisted partial cystectomy with en-bloc resection of a diverticulum has been previously described. This approach has often been utilized in patients with benign conditions such as refractory LUTS, recurrent UTIs or bladder stone formation. There have been few reports of this approach in patients with urothelial carcinoma confined to a bladder diverticulum.<sup>1</sup> The majority of reported cases where a MIS platform was used have employed a *trans*-peritoneal approach.<sup>2,3</sup> To our knowledge, the case presented is the first to utilize the single port robotic system to perform a partial cystectomy for focal, non-invasive urothelial carcinoma within a bladder diverticulum. From an oncological perspective, the pre-peritoneal approach avoided the risk of seeding the peritoneal cavity. Maintaining the peritoneal integrity also wards against ileus, or damage to other peritoneal structures. En-bloc resection allowed for a bladder-sparing approach that would not otherwise be

feasible by traditional TUR given the location of the tumor within a diverticulum.

While still in its clinical infancy, the da-Vinci single-port robotic system has been successfully applied to a variety of surgical scenarios.<sup>4</sup> Currently there are no reports of applying the single-port robotic system to a diverticulectomy or partial cystectomy.

Using traditional platforms, there have been several series reporting robotic bladder diverticulectomy/partial cystectomy. The largest reported 29 patients who underwent robotic assisted partial cystectomy for definitive management of primary bladder malignancy. 11 of these patients had tumor arising within a bladder diverticulum, while the majority had tumors located in the dome. The authors site a historical concern for recurrence following partial cystectomy, ranging between 38% and 78% in pilot studies.<sup>5</sup> Our approach minimizes this risk by internally isolating the tumor within the diverticulum in order to avoid tumor spillage.

This case is not without its limitations. Though this technique relies on three separate cystotomies, given the entirely pre-peritoneal approach and multi-layer closure of the larger two cystotomies, urethral catheter drainage obviated the need for a postoperative drain.

Micropapillary UC is an aggressive variant, and had this been a component of the patient's original pathology (which included random bladder biopsies), we may have chosen a more aggressive surgical approach and performed a concomitant lymph node dissection. This

procedure was performed within the context of presumed non-muscle invasive bladder cancer located in a posterior, narrow neck diverticulum. Such a location was non-resectable via TUR.

### Conclusion

Robotic assisted partial cystectomy has been demonstrated to be safe and feasible for a spectrum of benign and malignant bladder pathologies. This is the initial report of a *trans-vesicle* robotic assisted partial cystectomy for urothelial carcinoma using the da Vinci single-port robotic system. Further experience is necessary to develop this approach as an alternative to traditional methods of partial cystectomy.

### Appendix A. Supplementary data

Supplementary data to this article can be found online at <https://doi.org/10.1016/j.eucr.2021.101753>.

### References

1. Bailey GC, Frank I, Tollefson MK, Gettman MT, Knoedler JJ. Perioperative outcomes of robot-assisted laparoscopic partial cystectomy. *J Robot Surg*. 2018;12(2):223–228. <https://doi.org/10.1007/s11701-017-0717-x>.
2. Rao R, Nayyar R, Panda S, Hemal AK. Surgical techniques: robotic bladder diverticulectomy with the da Vinci-S surgical system. *J Robot Surg*. 2007;1(3):217–220. <https://doi.org/10.1007/s11701-007-0030-1>.
3. Altunrende F, Autorino R, Patel NS, et al. Robotic bladder diverticulectomy: technique and surgical outcomes. *Int J Urol*. 2011;18(4):265–271. <https://doi.org/10.1111/j.1442-2042.2010.02716.x>.
4. Kaouk J, Aminsharifi A, Sawczyn G, et al. Single-port robotic urological surgery using purpose-built single-port surgical system: single-institutional experience with the first 100 cases. *Urology*. 2020;140:77–84. <https://doi.org/10.1016/j.urology.2019.11.086>.
5. Golombos DM, O'Malley P, Lewicki P, Stone BV, Scherr DS. Robot-assisted partial cystectomy: perioperative outcomes and early oncological efficacy. *BJU Int*. 2017;119(1):128–134. <https://doi.org/10.1111/bju.13535>.