

Evaluation of retinal nerve fiber layer, ganglion cell layer, and optic nerve head morphological parameters in patients with obstructive sleep apnea and comparison with normal population

Vandhana Sundaram, Sujithra Haridas¹, Meenakshi Dhar², Harikrishnan CP³

Purpose: To compare the retinal nerve fiber layer (RNFL), ganglion cell layer (GCL), and optic nerve head (ONH) morphological parameters between obstructive sleep apnea (OSA) patients and age-matched controls using spectral domain optical coherence tomography (SD-OCT). **Methods:** This case control study was conducted in a multi-specialty tertiary care hospital from 2014 to 2016. Patients diagnosed to have OSA by overnight polysomnography were included in the study. Fifty eyes of 25 OSA patients with clinically normal optic disc were compared with 50 eyes of age-matched controls. The study population underwent detailed ophthalmological evaluation including SD-OCT. **Results:** There was significant thinning of the superior, inferior, and average RNFL in the OSA group when compared to controls. GCL analysis also showed a significant thinning of the six sectors as well as average and minimum ganglion cell layer + inner plexiform layer in OSA patients. The optic nerve head rim area was significantly decreased in OSA patients when compared to controls. **Conclusion:** OSA patients even with clinically normal optic disc showed significant decrease in the RNFL thickness, GCL thickness, and rim area when compared to age-matched controls. Hence, these patients constitute a high-risk population who need to be regularly screened and followed up for ocular co-morbidities.

Key words: Ganglion cell layer, glaucoma, obstructive sleep apnea, retinal nerve fiber layer

Obstruction Sleep Apnea (OSA) is characterized by repetitive episodes of complete or partial collapse of the upper airway during sleep resulting in complete cessation (apnea) or reduction (hypopnea) of airflow leading to arousal and hypoxia.^[1] In Indian studies, the prevalence of obstructive sleep apnea varied from 4.4% to 13.7%.^[2] The most prevalent ocular associations are primary open angle glaucoma and normal tension glaucoma.^[3] This is attributed to impaired optic nerve head blood flow autoregulation due to repetitive apnea and optic nerve vascular dysregulation secondary to arteriosclerosis and arterial blood pressure variations.^[4] Hence, there is a greater need to screen for early optic nerve axonal damage in this high-risk population.

Methods

This case control study was conducted in a multi-specialty tertiary care hospital in South India from 2014 to 2016. Patients diagnosed to have OSA by overnight polysomnography in Pulmonology department were referred to the Ophthalmology department for a detailed evaluation. There patients were categorized into mild, moderate, and severe OSA according to the apnea-hypopnea index (AHI)

- Mild Sleep Apnea: AHI 5–15 events per hour
- Moderate Sleep Apnea: AHI 15–30 events per hour
- Severe Sleep Apnea: AHI >30 events per hour^[2]

Greater the AHI, greater is the severity of obstructive sleep apnea. Full sleep study monitoring was performed during usual sleep hours with 6 hours of recording optimally needed to establish the diagnosis.

Patients with media opacity preventing acquisition of good OCT images, refractive error (>2.00 diopter spherical error, >1 diopter cylindrical error), history of uveitis, any retinal pathology such as diabetic retinopathy, hypertensive retinopathy, age-related macular degeneration, family history of glaucoma, history of chronic steroid use, heavy smoking, alcohol abuse and co-existing neurological diseases that might affect visual field were excluded from the study.

Controls consisted of age and sex matched healthy subjects who were recruited from those attending the out-patient department for conditions such as refractive errors and presbyopic correction. Epworth Sleepiness Scale (ESS) was employed to measure daytime sleepiness and rule out OSA

Department of Cornea, Sankara Eye Hospital, Coimbatore, Tamil Nadu, ¹Department of Ophthalmology, Amrita Institute of Medical Sciences, Kochi, Kerala, ²Department of Glaucoma, Centre for Sight, New Delhi, ³Cataract Services, Chaitanya Eye Hospital, Kochi, Kerala, India
Past Affiliation: The Study was Carried Out at Department of Ophthalmology, Amrita Institute of Medical Sciences, Kochi, Kerala, India

Correspondence to: Dr. Vandhana Sundaram, Sankara Eye Hospital, Coimbatore, Tamil Nadu, India. E-mail: vandhana.2011@gmail.com

Received: 25-Apr-2021

Revision: 17-Aug-2021

Accepted: 13-Oct-2021

Published: 27-Jan-2022

Access this article online

Website:

www.ijo.in

DOI:

10.4103/ijo.IJO_985_21

Quick Response Code:



This is an open access journal, and articles are distributed under the terms of the Creative Commons Attribution-NonCommercial-ShareAlike 4.0 License, which allows others to remix, tweak, and build upon the work non-commercially, as long as appropriate credit is given and the new creations are licensed under the identical terms.

For reprints contact: WKHLRPMedknow_reprints@wolterskluwer.com

Cite this article as: Sundaram V, Haridas S, Dhar M, Harikrishnan CP. Evaluation of retinal nerve fiber layer, ganglion cell layer, and optic nerve head morphological parameters in patients with obstructive sleep apnea and comparison with normal population. Indian J Ophthalmol 2022;70:453-7.

while choosing control population. A scale of zero–four was chosen by the patient for eight different situations.^[5]

Patients with scores ≥ 10 and experiencing sleepiness during work or driving were regarded as having OSA. The questionnaire is filled up both by the patients and their partners and in this case, the higher of two scores was accepted.

Patients with no systemic co-morbidities, no significant refractive error (>2.00 diopter spherical error, >1 diopter cylindrical error were excluded), no history of snoring, a score of < 10 on ESS, no evidence of glaucomatous optic nerve appearance and a cup disc ratio less than 0.5, open angles on gonioscopy, no previous history of chronic steroid use, ocular trauma, ocular surgery or laser treatment, and no history of heavy smoking or chronic alcohol intake were included as controls.

All subjects had a detailed ophthalmological examination, which included visual acuity by snellen chart, intraocular pressure measurement by goldmann's applanation tonometry corrected with central corneal thickness measured by ultrasound pachymetry, gonioscopy, slit lamp examination including biomicroscopy (90 D), and fundus examination using indirect ophthalmoscope.

In addition, the subjects underwent automated perimetry using Humphrey's visual field analysis. The visual fields that satisfied Anderson's criteria were labeled as glaucomatous visual field defects. Patients underwent a minimum of three fields to demonstrate a reproducible field defect. Spectral domain Optical coherence tomography (SD-OCT) using ZEISS Cirrus HD-OCT Model 400 was also done to assess the retinal nerve fiber thickness, ganglion cell layer thickness – 6 sector analysis, average ganglion cell layer + inner plexiform layer thickness, minimum ganglion cell + inner plexiform layer thickness, optic nerve head morphological parameters such as average cup disc ratio, cup volume, rim area and disc area, and total retinal thickness as shown in Figs. 1 and 2.

All SD-OCT images were taken after pupillary dilatation. Only good quality scans, defined as scans with signal strength ≥ 6 , without RNFL discontinuity or misalignment, involuntary saccade or blinking artifacts, and absence of RNFL algorithm segmentation failure, were used for analysis. All the OCT's were taken by the same observer. At presentation, three OCTs were taken for each patient and the best OCT was selected for analysis.

After evaluation, the study population was classified into two groups. Cases included 50 eyes of 25 OSA patients with open angles, normal optic disc and normal visual fields, and control group included 50 eyes of 25 age and sex-matched controls.

An informed consent was taken from all the patients as per the ethical committee guidelines.

Sample size calculation

Based on the results observed on the most important parameter, retinal nerve fiber layer^[6] with 95% confidence interval and 80% power, minimal sample size came to less than five. We assessed 45 OSA patients for ocular co-morbidities and then included 25 OSA patients (50 eyes) and 25 controls (50 eyes) for comparison analysis.

Statistical analysis was done using IBM SPSS20. (SPSS Inc, Chicago, USA). For all the continuous variable, the

results are either given in Mean \pm SD and for categorical variable as percentage. To compare the mean difference of numerical variable between groups, independent two sample "t" test was applied. To obtain the relationship between two variables, Pearson correlation was applied. A *P* value < 0.05 was considered statistically significant. Bonferroni test was used to get the corrected *P* value of $P < 0.002$.

Results

The mean age was 51.12 ± 15.61 and 45.96 ± 8.90 years in cases and controls, respectively. The difference of mean age between cases and controls was not statistically significant with a *P* value of 0.158. Cases and control group had 20 males and five females each. The mean body mass index was 32.166 ± 5.476 and 22.896 ± 1.4076 kg/m² in cases and controls, respectively and their difference was statistically significant with a *P* value of < 0.001 . In the OSA group, four patients had Mild OSA, nine patients had Moderate OSA, and 12 patients had Severe OSA. The Mean intraocular pressure was 15.82 ± 1.945 and 14.90 ± 2.341 mmhg in cases and controls, respectively and the difference was not statistically significant. On comparison of parameters between OSA patients and controls, the central corneal thickness was not statistically different between the two groups ($P > 0.05$). Analysis of visual field parameters such as mean deviation and pattern standard deviation between cases and controls was not statistically significant as shown in Table 1.

Retinal nerve fiber layer

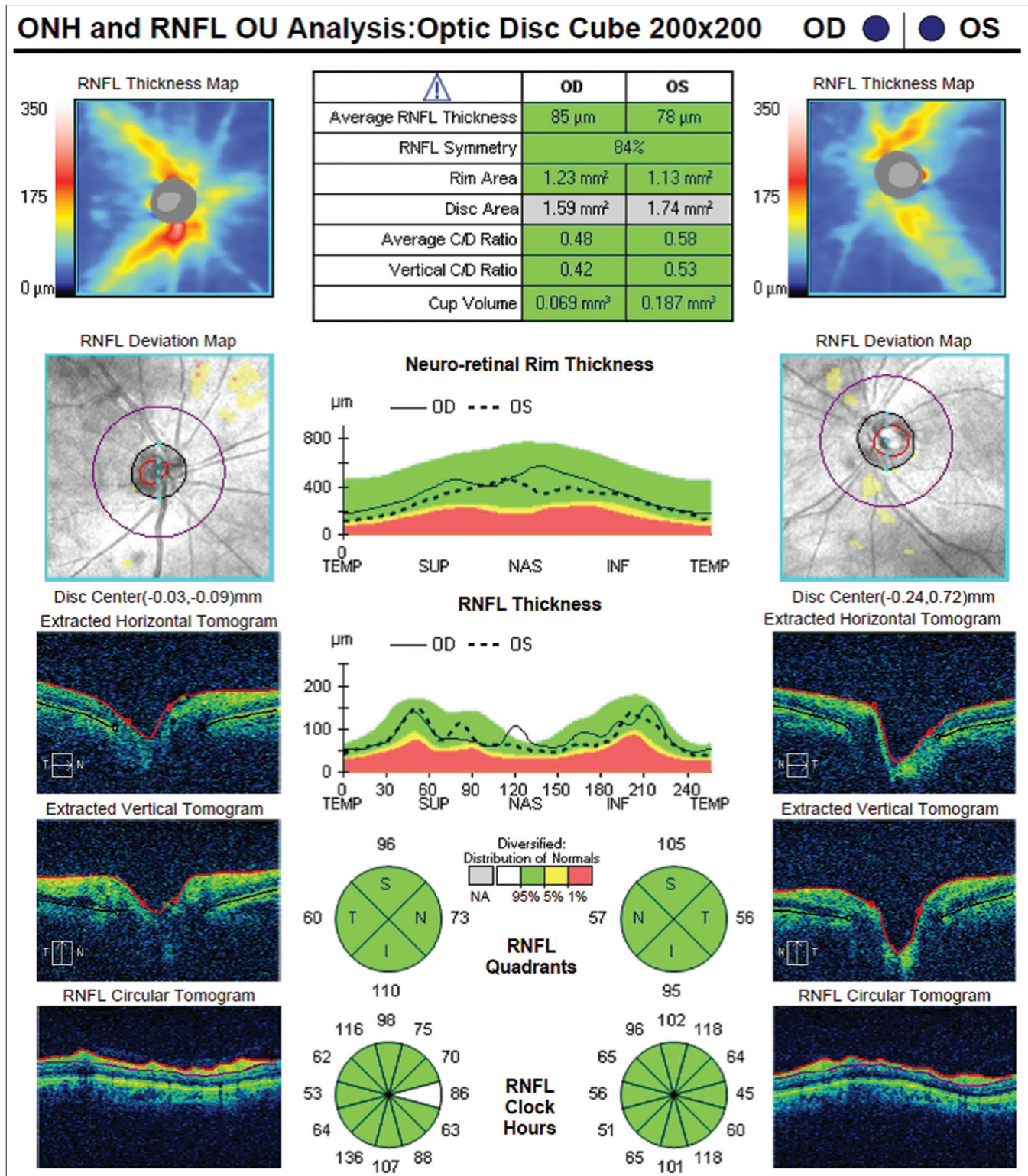
RNFL analysis in OSA patients showed statistically significant decrease of the mean Superior RNFL, Inferior RNFL, and Average RNFL with a *P* value of 0.018, < 0.001 , and < 0.001 , respectively. The difference in mean temporal RNFL was not statistically significant between the two groups ($P = 0.244$) and the values are presented in Table 2. On mean RNFL clock hour analysis, RNFL clock hour 1,4,5,6 was decreased in OSA patients and the difference was statistically significant with a *P* value of 0.003, 0.012, < 0.001 , and 0.004, respectively.

Ganglion cell layer

Ganglion cell analysis also showed a decrease in all six sectors of ganglion cell layer, average, and minimal ganglion cell layer-inner plexiform layer thickness in OSA patients when compared to controls; the difference was statistically significant ($P < 0.05$) and the values presented in Table 3. Measurement of mean average and central subfield retinal pigment epithelium + inner plexiform layer thickness was not significant between the two groups ($P = 0.060$ and $P = 0.266$, respectively)

Table 1: Comparison of visual field parameters between cases and controls (n=50)

Parameters	Group	Mean \pm standard deviation	<i>P</i>
Mean Deviation	Cases	-1.8354 \pm 0.60706	0.027
	Controls	-1.7604 \pm 0.47809	
Pattern Standard Deviation	Cases	1.8676 \pm 0.49399	0.252
	Controls	1.7802 \pm 0.93798	



Optic nerve head parameters

Among the optic nerve head morphological parameters, the difference in average CD ratio, CD Volume and Disc area was not statistically significant between the two groups with a

P value of 0.133, 0.091, and 0.268, respectively. However, the rim area was significantly decreased in OSA patients when compared to controls ($P < 0.001$), and the values are presented in Table 4.

Discussion

In this study, we compared the retinal nerve fiber layer of patients with OSA with normal optic disc and age–sex matched controls using spectral domain optical coherence tomography.

OSA patients showed statistically significant thinning of superior RNFL, inferior RNFL, and average RNFL when compared to those values of age-matched controls. The maximum thinning was observed in the inferior RNFL and average RNFL and the least decrease was observed in the temporal RNFL. This is in agreement with a meta-analysis done by Zhao *et al.*^[7] who concluded that OSA patients had a significantly decreased average RNFL as well as four quadrant RNFL thickness compared to control groups with maximum thinning noticed in the inferior RNFL and least thinning in the temporal RNFL. A study done by Zengin *et al.*^[6] on OSA patients showed a significant thinning of superior, inferior, nasal, and average RNFL thickness. Another observational case control study by Casas *et al.*^[8] also showed decrease only in peripapillary nasal RNFL thickness and no statistically significant thinning of other RNFL parameters on Stratus OCT. A study by Lin *et al.*^[9] concluded that there was a reduction in average RNFL, superior

RNFL, and temporal RNFL in patients with moderate and severe OSA when compared with patients with mild or no OSA.

The AHI is a measure of the severity of OSA and hence the AHI was correlated to the average RNFL values. There was a negative correlation between AHI and average RNFL values indicating that as the severity of the OSA increases, there is a corresponding decrease in average RNFL thickness. Though there was negative correlation, this was not statistically significant probably due to small sample size. Zengin *et al.*^[6] also reported a similar result where there was a weak negative correlation between AHI and average RNFL thickness.

Table 2: Comparison of Retinal nerve fiber layer (RNFL) parameters between cases and controls (n=50)

Parameters	Group	Mean	Standard deviation	P
Superior RNFL	Cases	112.70	13.125	0.018
	Controls	117.90	7.718	
Inferior RNFL	Cases	114.90	13.455	<0.001
	Controls	127.52	7.484	
Temporal RNFL	Cases	60.94	9.224	0.244
	Controls	62.78	6.195	
Nasal RNFL	Cases	69.16	9.900	0.043
	Controls	72.96	8.588	
Average RNFL	Cases	89.42	7.489	<0.001
	Controls	95.12	4.935	

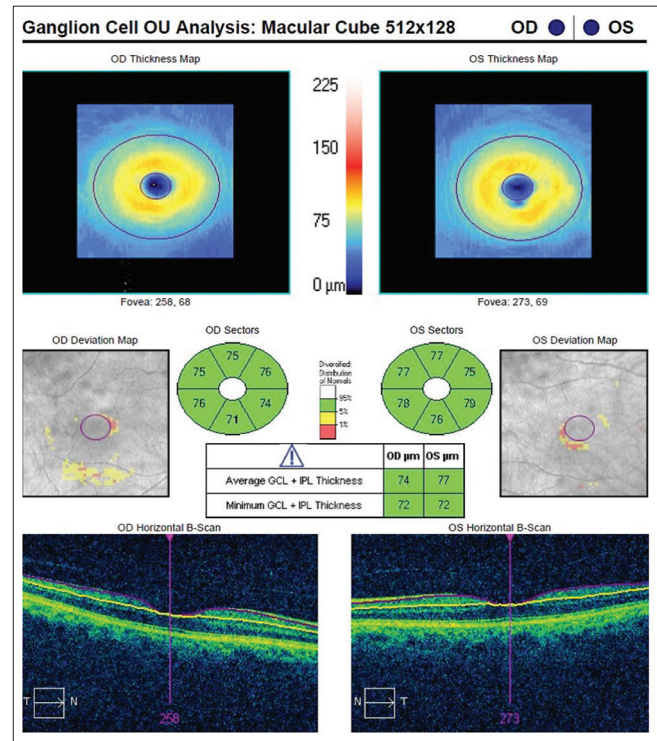


Figure 2: SD-OCT showing ganglion cell layer complex

Table 3: Comparison of ganglion cell layer (GCL) between cases and controls (n=50)

Parameters	Group	Mean	Standard deviation	P
GCL Superior quadrant	Cases	79.40	10.258	0.002
	Controls	84.24	3.566	
GCL Superonasal quadrant	Cases	82.14	10.357	0.018
	Controls	85.90	3.716	
GCL Inferonasal quadrant	Cases	79.64	10.299	0.002
	Controls	84.74	4.024	
GCL Inferior quadrant	Cases	78.18	7.711	<0.001
	Controls	82.78	4.171	
GCL Inferotemporal quadrant	Cases	79.60	7.887	0.001
	Controls	83.84	3.431	
GCL Superotemporal quadrant	Cases	77.38	9.704	0.001
	Controls	82.36	3.618	
Average GCL + Inner plexiform layer thickness	Cases	79.90	7.265	<0.001
	Controls	84.04	3.213	
Minimum GCL + Inner plexiform layer thickness	Cases	72.98	12.942	<0.001
	Controls	81.74	3.864	

Table 4: Comparison of optic nerve head parameters between cases and controls (n=50)

Parameters	Group	Mean±Standard deviation	P
Avg Cup disc ratio	Cases	0.49±0.81	0.133
	Controls	0.46±0.13	
Cup disc volume	Cases	0.2588±0.16587	0.091
	Controls	0.2081±0.12892	
Rim area	Cases	1.2726±0.23133	<0.001
	Controls	1.4478±0.23716	
Disc area	Cases	2.0378±0.29362	0.268
	Controls	1.9718±0.29931	

Further studies are required to evaluate if the duration of OSA could also be a risk factor in addition to severity of OSA causing prolonged hypoxic insult and RNFL loss.

On analysis of the ganglion cell layer thickness and comparing between the two groups, there was statistically significant thinning of the ganglion cell layer in all six sectors in OSA patients. Maximum statistical significance was noted for GCL in the inferior quadrant, which corresponds to the inferior RNFL thinning noticed in these patients. The average and minimum ganglion cell layer + inner plexiform layer (GCL + IPL) thickness was also reduced in OSA patients when compared to age-matched controls. This is similar to the results observed in a study by Semenova *et al.*^[10] where OSA patients had significant decrease in average RNFL and average macular ganglion cell complex thickness on Optivue OCT and scanning laser polarimetry.

On comparison of optic nerve head parameters there was no statistically significant difference in the average CD ratio, cup volume, and disc area between the two groups. However, there was statistically significant decrease in rim area in OSA patients due to corresponding RNFL thinning. Our observations on optic nerve head parameters are in contrary to other studies, which could be due to variation in disc size among the different studies. Casas *et al.*^[8] observed an increase in vertical integrated rim width, horizontal integrated rim area and disc area among patients with OSA using Stratus OCT. But ONH parameters are easier to measure with SD-OCT due to the high contrast between the nonreflective vitreous and inner limiting membrane and also its ability to delineate the end of bruch's membrane; hence optic nerve head parameters measured using SD-OCT could be more accurate and reproducible.^[11]

Analysis of the central subfield internal limiting membrane - retinal pigment epithelium (ILM-RPE) and average ILM-RPE thickness did not show any statistical significance between the two groups. Retinal layers affected by glaucoma constitute only a one-third of the total macular thickness. So, the total retinal thickness might not be as good a marker as retinal nerve fiber layer or ganglion cell layer.

Mwanza *et al.* reported that on SD-OCT, the best discriminates between glaucomatous eye and normal eyes are RNFL thickness at the inferior temporal clock hour 7, superotemporal RNFL, inferior quadrant RNFL, average RNFL thickness, rim area, CD ratio, cup to disc area ratio, and minimal GC-IPL thickness.^[12] Our study has shown statistical difference in most of the above parameters among OSA patients when compared to controls, hence indicating that these OSA patients even with normal looking discs could be at risk of developing glaucoma.^[12]

Long-term follow-up is necessary in these OSA patients with RNFL thinning to see if they develop glaucoma.^[13,14] Our study being a cross-sectional case control study, the above was not done. Both eyes of cases and controls were included and evaluated in this study; so clustering was not avoided.

Conclusion

OSA patients with clinically normal optic disc and normal visual fields showed significant decrease in the retinal nerve fiber layer thickness and ganglion cell layer thickness when compared to age-matched controls. Hence, it is important to identify the structural defects prior to the occurrence of functional loss to diagnose glaucoma in its early stages in this high-risk population.

Financial support and sponsorship

Nil.

Conflicts of interest

There are no conflicts of interest.

References

1. Sleep-related breathing disorders in adults: Recommendations for syndrome definition and measurement techniques in clinical research. The report of an American academy of sleep medicine task force. *Sleep* 1999;22:667-89.
2. Prasad CN. Obstructive sleep apnea hypopnea syndrome – Indian scenario. *Perspect Med Res* 2013;1:22-5.
3. De Groot V. Eye diseases in patients with sleep apnea syndrome: A review. *Bull Soc Belge Ophthalmol* 2009;43-51.
4. Shi Y, Liu P, Guan J, Lu Y, Su K. Association between glaucoma and obstructive sleep apnea syndrome: A meta-analysis and systematic review. *PLoS One* 2015;10:e0115625.
5. Johns MW. Daytime sleepiness, snoring, and obstructive sleep apnea: The Epworth sleepiness scale. *Chest* 1993;103:30-6.
6. Zengin MO, Tuncer I, Karahan E. Retinal nerve fiber layer thickness changes in obstructive sleep apnea syndrome: One year follow up results. *Int J Ophthalmol* 2014;7:704-8.
7. Zhao X-J, Yang C-C, Zhang J-C, Zheng H, Liu P-P, Li Q. Obstructive sleep apnea and retinal nerve fiber layer thickness: A meta analysis. *J Glaucoma* 2016;25:e413-8.
8. Casas P, Ascaso F, Adiego M, Jimenez B, Cabezon L, Tejero-Garcés G, *et al.* Retina and optic nerve evaluation by optical coherence tomography in adults with Obstructive sleep apnea-hypopnea syndrome (OSAHS). *Graefes Arch Clin Exp Ophthalmol* 2013;251:1625-34.
9. Lin PW, Friedman M, Lin HC, Chang HW, Pulver TM, Chin CH. Decreased retinal nerve fiber layer thickness in patients with obstructive sleep apnea/hypopnea syndrome. *Graefes Arch Clin Exp Ophthalmol* 2011;249:585-93.
10. Semenova N, Akopyan V. Retinal nerve fiber layer and Ganglion cell complex thickness assessment in patients with obstructive sleep apnea. *Invest Ophthalmol Vis Sci* 2012;53:799.
11. Kostanyan T, Wollstein G, Schuman JS. Evaluating glaucoma damage: Emerging imaging technologies. *Expert Rev Ophthalmol* 2015;10:183-95.
12. Mwanza JC, Chang RT, Budenz DL, Durbin MK, Gendy MG, Shi W, *et al.* Reproducibility of peripapillary retinal nerve fiber layer thickness and optic nerve head parameters measured with cirrus HD-OCT in glaucomatous eyes. *Invest Ophthalmol Vis Sci* 2010;15:5724-30.
13. Fan Y-Y, Su W-W, Liu C-H, Chen HS-H, Wu S-C, Chang SHL, *et al.* Correlation between structural progression in glaucoma and obstructive sleep apnea. *Eye* 2019;33:1459-65.
14. García-Sánchez A, Villalán I, Asencio M, García J, García-Río F. Sleep apnea and eye diseases: Evidence of association and potential pathogenic mechanisms. *J Clin Sleep Med* 2021. doi: 10.5664/jcsn.9552. Online ahead of print.