

# Laparoscopic Derotation and Cholecystectomy for Torsion Gallbladder

Prasanna Kumar Reddy, MD, M. Muralidharan, MD, R. Venkatasubramanian, MD, S. Yuvaraja, MD

## ABSTRACT

Torsion of the gallbladder is an unusual cause of gangrenous cholecystitis. Even with the advent of recent radiological imaging modalities, the preoperative diagnosis of this entity remains elusive. Herein, we present a case of gallbladder torsion in a 76-year-old lady who successfully underwent laparoscopic derotation and cholecystectomy.

**Key Words:** Gallbladder torsion, Laparoscopy, Derotation.

## INTRODUCTION

Gallbladder torsion, though first described by Wendel<sup>1</sup> in 1898 is an extremely rare cause of abdominal pain. Its incidence has been variously reported in different literature. The treatment of choice traditionally has been exploratory laparotomy with cholecystectomy. Herein, we present a case of gallbladder torsion diagnosed at emergency laparoscopy followed by derotation and laparoscopic cholecystectomy.

## CASE REPORT

The patient was a 76-year-old female physician, hypothyroid and hypertensive, admitted as an emergency patient with complaints of upper abdominal pain of 3-day duration. Pain was greater in the epigastrium and was radiating to the right hypochondrium. She had been examined earlier and diagnosed with acute cholecystitis at another center where she was managed conservatively with IV fluids, antibiotics, and analgesics with no relief.

At the time of admission, she was pyrexial with a temperature of 37.92°C. Her pulse was 98 beats per minute, and her blood pressure was 130/90 mm Hg. No icterus was present, and her hydration was good. Abdominal examination showed tenderness in the epigastrium and right hypochondrium with guarding.

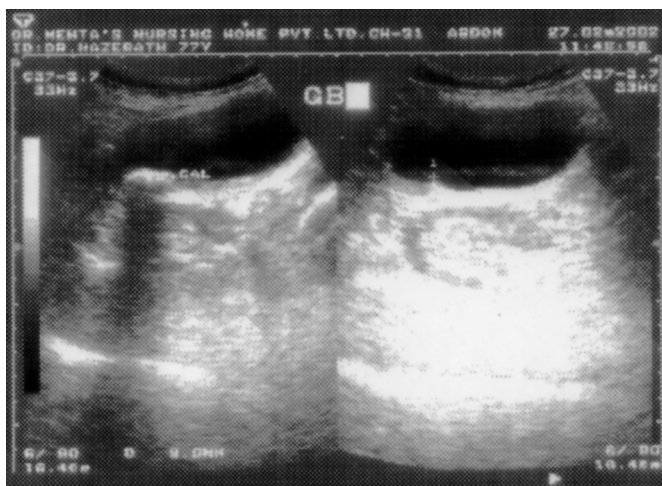
Laboratory investigations showed a grossly raised white cell count with neutrophil leucocytosis and elevated erythrocyte sedimentation rate (ESR). Her thyroid profile as well as liver function tests were normal. An ultrasound of the whole abdomen showed a distended horizontally placed gallbladder with irregular wall thickening containing multiple calculi. (**Figure 1**).

Since the patient's temperature and abdominal pain did not settle within the first 24 hours with antibiotics, an emergency laparoscopy was done. At laparoscopy, a grossly distended, gangrenous gallbladder was seen. To facilitate further progress, the gallbladder was decompressed by aspiration and lifted up (**Figure 2**). The Calot's triangle area was edematous. To our surprise, on dissection, we noticed that the gallbladder had undergone complete rotation along its long axis (**Figure 3**). It was dero-

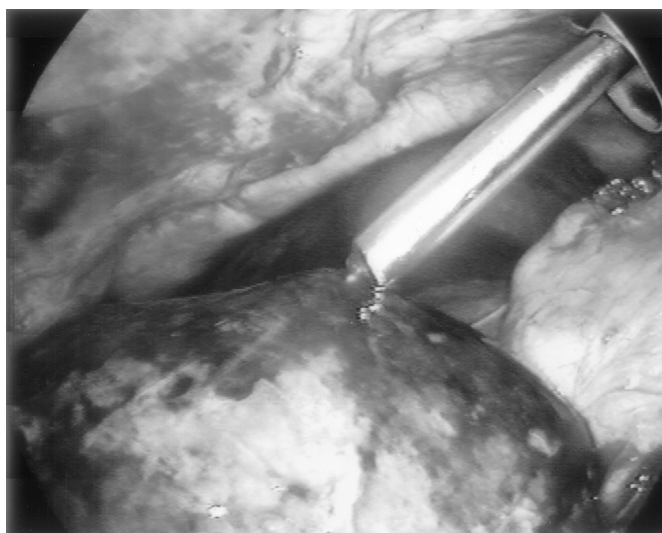
Department of Gastrointestinal Surgery, Apollo Hospitals, Chennai, India (all authors).

Address reprint requests to: Prasanna Kumar Reddy, MD, Consultant Surgical Gastroenterologist and Laparoscopic Surgeon, Apollo Hospitals, 21, Grems Lane, Chennai 600006, India. Telephone: 00 91 44 28290200, Fax: 00 91 44 28294429, E-mail: reddydk@eth.net.

© 2005 by JSLS, *Journal of the Society of Laparoendoscopic Surgeons*. Published by the Society of Laparoendoscopic Surgeons, Inc.



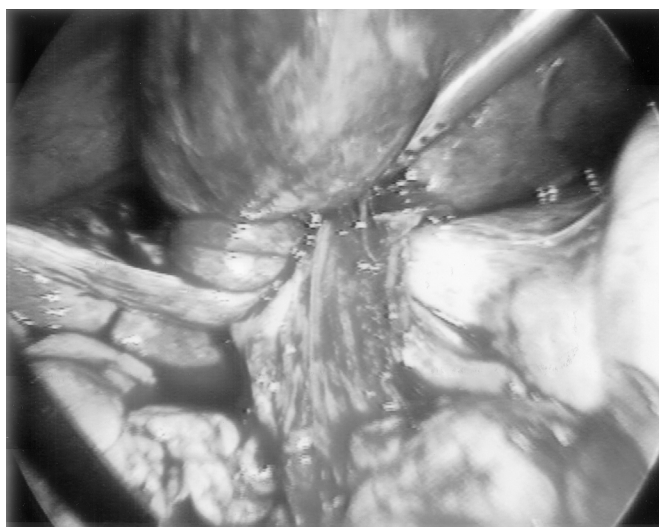
**Figure 1.** Ultrasound abdomen showing distended, horizontally placed gallbladder with calculi.



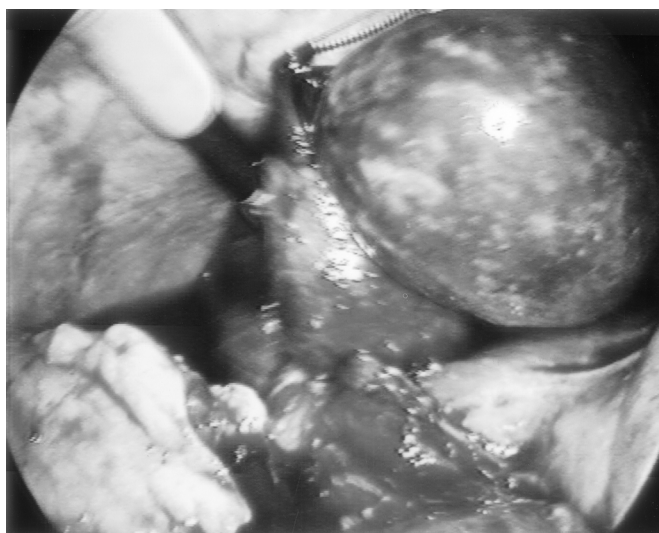
**Figure 2.** Distended gangrenous gallbladder being decompressed.

tated in a clockwise fashion (**Figure 4**). After untwisting, it was found that the anticlockwise twist had occurred above the impacted stone at the neck of the gallbladder. The mesentery attached to the gallbladder neck was dissected. The Calot's triangle was opened. The cystic artery was clipped and divided. The cystic duct stone was milked, and the duct was clipped and divided. The gallbladder was dissected off the liver surface with a diathermy hook, put in an endobag, and extracted through the epigastric port. A suction drain was placed in the right subhepatic space.

The postoperative period was uneventful. The patient was



**Figure 3.** Torsion of the neck of the gallbladder.



**Figure 4.** The gallbladder being untwisted in a clockwise fashion.

started on clear oral fluids on the second postoperative day, followed by a soft solid diet. She was discharged on the fourth postoperative day. The histopathology report of the specimen showed gangrenous necrotizing cholecystitis.

## DISCUSSION

Numerous cases of gallbladder torsion have been reported though the cause is still elusive. This case exemplifies the age and sex distribution of patients who are predisposed to torsion (Age –greatest in the eight and ninth decade with a female preponderance ratio of 3:1).<sup>2-4</sup>

The prerequisites for gallbladder torsion are (1) anomalies in peritoneal attachment of the gallbladder allowing greater mobility<sup>2,5</sup> and (2) an inciting event causing gallbladder rotation around a fixed point, usually the cystic duct.

Though the variation in peritoneal attachment of the gallbladder is congenital, the predisposing factor is more commonly acquired with age.

Wendel<sup>1</sup> coined the phrase “floating gallbladder” to describe a gallbladder that was pedunculated, hanging completely free from the liver, suspended only to a cystic duct mesentery. The gallbladder can also be connected to the liver by a mobile mesentery extending to various lengths towards the fundus.

The inciting events of torsion may be either mechanical or hormonal changes that affect the gallbladder. The mechanical events may be sudden shifts in body position, intense peristalsis of adjacent viscera, and blunt trauma. Increased cholecystokinin production leading to gallbladder peristalsis after a fatty meal has been proposed as the hormonal basis of gallbladder torsion. In this particular case, the free-lying gallbladder suspended by the cystic duct mesentery with stone impacted at the neck of the gallbladder formed the basis of torsion with the cystic duct as the axis point.

Gallbladder torsion may occur in a clockwise or counterclockwise fashion. Two types of gall bladder torsion have been described: (1) Incomplete torsion with <180 degree rotation, and (2) Complete torsion with >180-degree rotation.

Whatever may be the cause of torsion, the outcome is obstruction of bile or blood flow, or obstruction of both. Obstruction of bile and blood flow leads to empyema formation followed by necrosis of the wall of the gallbladder.

The clinical features of gallbladder torsion are nonspecific, making a preoperative diagnosis difficult on the basis of history and physical examination alone.<sup>2</sup> A low-frequency of fever and jaundice, poor response to antibiotic therapy, and acute onset of abdominal pain may be helpful in the differential diagnosis of acute cholecystitis.

Ultrasound and computed tomographic (CT) scan have complemented the diagnosis of gallbladder torsion. The presence of the gallbladder outside its fossa and inferior to the liver with an echogenic conical structure has been found specific to gallbladder torsion.

Kitagawa et al<sup>6</sup> formulated the following criteria for the diagnosis of gallbladder torsion:

(1) Fluid collection between the gallbladder and the liver bed indicating a “floating gall bladder”

(2) A gallbladder positioned horizontally along its long axis indicating a free-lying gallbladder, as was the case in our patient.

(3) The presence of a well-enhanced cystic duct located on the right side of the gallbladder that may also be visualized on CT scan

(4) Signs of inflammation, ischemia, or necrotic change in the gallbladder

Treatment is surgical derotation and cholecystectomy. In the past, open procedures were carried out. With experience in laparoscopic cholecystectomy, laparoscopic derotation and cholecystectomy will become the preferred approach. If treated laparoscopically, gallbladder decompression and detorsion prior to cholecystectomy are helpful techniques to avoid bile duct injury.

## CONCLUSION

Though improved diagnostic imaging techniques can aid in the diagnosis of this entity, definitive diagnosis is made only during surgery. Early laparoscopic intervention can result in rapid resolution thus preventing the potential complication of perforation of the viscus into the peritoneal cavity.

## References:

1. Wendel AV. Case of floating gallbladder and kidney complicated by cholelithiasis associated with perforation of gallbladder. *Ann Surg* 1898;27:199–202.
2. Desmaizieres FC, Montemagino S, de Lavernetter XB, Mafda-leinat P. Torsion of the gall bladder in an adult: a rare case of acute cholecystitis. *Int Surg*. 2002;87:87–89.
3. Vosswinkel JA, Colantoio AL. Torsion of the gallbladder: laparoscopic identification and treatment. *Surg Endosc*. 1999; 13(11):1154–1156.
4. Schroder DM, Cusumano DA 3rd. Laparoscopic cholecystec-tomy for gallbladder torsion. *Surg Laparosc Endosc*. 1995;5(4): 330–334.
5. Christoudias GC. Gall bladder volvulus with gangrene. Case report and review of the literature. *JSLS*. 1997;1(2):167–170.
6. Kitagawa H, Nakada K, Enami T, Yamaguchi T, Kawaguchi F, Nakada J. Two cases of torsion of the gallbladder diagnosed preoperatively. *Pediatr Surg*. 1997;32(11):1567–1569.