

Original Article

# Characteristic Histological Findings of Asymptomatic EBV-associated Lymphoproliferative Disorders in Tonsils

Tsengelmaa Jamiyan, Yoshimasa Nakazato, Hajime Kuroda, Masaru Kojima, Yasuo Imai

Recently, an in situ hybridization (ISH) and immunohistochemical study demonstrated that Epstein-Barr virus (EBV) infection may be involved in tonsillar hypertrophy and recurrent tonsillitis in children and young adolescents. The present study was based on 630 consecutive specimens from tonsillectomies performed at the Dokkyo University School of Medicine between 2002 and May 2017. Clinical findings were obtained from hospital records. Histologically, a “pale clear zone” was characterized by hyperplastic germinal centers with ill-defined borders and interfollicular expansion. Immunohistologically, the majority of immunoblasts were CD20-positive, whereas medium to large lymphoid cells usually expressed CD3. Among 14 lesions, numerous EBV-encoded small RNA (EBER)-positive cells were detected in 10. In 7 of these 10 lesions, EBER-positive cells were detected in germinal centers as well as in the interfollicular area. Based on our results, the “pale clear zone” suggests asymptomatic EBV infection of the tonsil. The present study demonstrated that “pale clear zones” should be taken into consideration when diagnosing asymptomatic EBV-associated LPDs in the tonsils of children and young adolescents as well as in middle-aged patients.

**Keywords:** Tonsils, Epstein-Barr virus, lymphoproliferative disorders, pale clear zones

## INTRODUCTION

Infectious mononucleosis (IM) is an acute lymphoproliferative disorder (LPD) that typically occurs in young patients and is usually caused by Epstein-Barr virus (EBV).<sup>1</sup> The diagnosis of IM is usually based on clinical and serological findings.<sup>2</sup> However, lymphoid tissue biopsy may be performed when malignant lymphoma is suspected in patients demonstrating atypical clinical features.<sup>3-7</sup> Atypical features include age over 30 years, generalized lymphadenopathy, isolated lymphadenopathy at an unusual site, a tonsillar mass, negative heterophil antibody titer, and absence of atypical lymphocytosis in the peripheral blood.

Recently, an in situ hybridization (ISH) and immunohistochemical study reported that EBV may be involved in tonsillar hypertrophy and recurrent tonsillitis in children and young adolescents.<sup>8,9</sup> These patients exhibited no characteristic signs on presentation or laboratory abnormalities indicating EBV infection.<sup>2,3</sup> The characteristic histological findings of such patients remain unknown. However, one report<sup>6</sup> noted that the lymphoid follicles were surrounded by a sheet-like proliferation of polymorphous infiltrations forming a marginal zone distribution pattern in one of the patients. We

termed these lesions a “pale clear zone”. To further clarify the histological and immunohistochemical findings of such lesions, 630 tonsillectomy specimens were analyzed.

## MATERIALS AND METHODS

This study was based on 630 consecutive specimens from tonsillectomies performed at the Dokkyo University School of Medicine between 2002 and May 2017. Clinical findings were obtained from hospital records.

Three-micrometer-thick sections were cut from formalin-fixed, paraffin-embedded tissues, and stained with hematoxylin-eosin (HE) and Unstain 3.

Immunohistochemistry of paraffin sections was performed using a Histofine Histostainer (Leica Biosystems, Bond III, Melbourne, Australia) according to the manufacturer's instructions. A panel of antibodies against human LN22 (bcl-6; Leica Biosystems), A0452 (CD3; Dako Omnis., Denmark, German), 1F6 (CD4; Leica Biosystems), 4B11 (CD8; Leica Biosystems), 56C6 (CD10; Leica Biosystems), L26 (CD20; Nichirei Bioscience Inc., Tokyo, Japan), 2G9 (CD21; Leica Biosystems), Ber-H2 (CD30; Dako Omnis., Denmark, German), 10D6 (CD163; Leica Biosystems),


Received: April 18, 2018. Revised: May 11, 2018. Accepted: May 30, 2018. J-STAGE Advance Published: July 14, 2018  
DOI:10.3960/jslrt.18017

Department of Diagnostic Pathology, Dokkyo Medical University School of Medicine, Mibu, Japan

**Corresponding author:** Masaru Kojima, M.D, Ph.D., Department of Diagnostic Pathology, Dokkyo Medical University School of Medicine, Mibu, Tochigi 321-0293, Japan.

E-mail: k-masaru@dokkyomed.ac.jp

Copyright © 2018 The Japanese Society for Lymphoreticular Tissue Research

 This work is licensed under a Creative Commons Attribution-NonCommercial-ShareAlike 4.0 International License.

GrB-7 (Granzyme B; Nichirei Bioscience Inc.), EAU-32 (MUM-1; Leica Biosystems), SP-142A6 (PD-1; Leica Biosystems), and 2G9 (TIA-1; Immunotech, Beckman Coulter, Inc., Marseille, France) was used.

ISH for Epstein-Barr virus (EBV)-encoded small RNA (EBER) oligonucleotides, and kappa and lambda light chains was performed using formalin-fixed, paraffin-embedded sections with a hybridization kit (Leica Biosystems, Bond III; PB0589., PB0645., PB0669).

## RESULTS

### *Incidence of pale clear zones and EBV-positive cells*

Pale clear zones were identified in the tonsils in 131 (21%) of the 630 specimens. Of these, EBV was detected in the tonsils in 14 (10.6%).

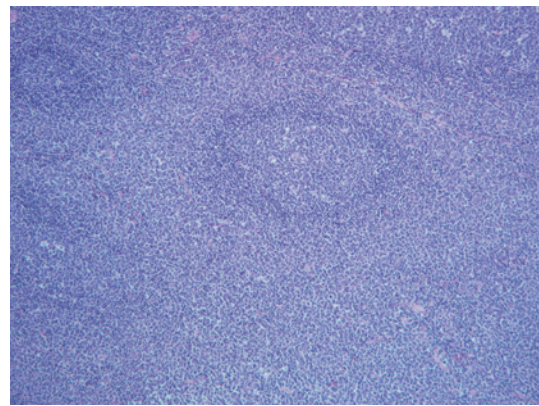
### *Clinical findings in 14 patients*

The main clinical findings in the 14 patients are summarized in Table 1. The 14 patients, 6 men and 8 women, ranged in age from 3 to 43 years, with a mean age of 21 and a median age of 13. Six patients (42.8% nos. 5,7,10,11,13, and 14) were older than 30. They presented with snoring (7/14), sore throat (4/14), fever (2/14) and tonsillar hypertrophy (1/14). Of 7 patients (nos.2,5,7,9,10,12, and 13) with habitual angina, six (nos.1,3,4,6,8, and 11) were diagnosed with sleep apnea, and one (no.14) with both sleep apnea and tonsillitis. All of the patients had bilateral tonsillar masses, with 2 (14.2%) cases of allergic rhinitis, 2 (14.2%) of bronchial asthma, and 1 (7.1%) of group A streptococcal infection. Neither atypical lymphocytosis in the peripheral blood

nor liver dysfunction was detected in any of the 14 patients. No serological examinations for EBV were performed. Follow-up data were available for all 14 patients for periods ranging from 8 to 61 months (mean: 29 months, median: 24 months). All 14 patients were alive and well during the follow-up period.

### *Histological, immunohistochemical, and ISH findings*

Histologically, the “pale clear zone” was characterized by hyperplastic germinal centers with ill-defined borders and interfollicular expansion (Fig. 1). On the high-power field, the pale zone was composed of numerous medium to large lymphocytes with clear cytoplasm, including variable numbers of immunoblasts and plasma cells (Fig. 2). The medium to large lymphocytes occasionally had twisted nuclei



**Fig. 1.** On a low-power field, the pale clear zone was characterized by the hyperplastic germinal centers with ill-defined borders and interfollicular expansion. HE. Case 3

**Table 1.** Summary of clinical information and EBV in 14 cases

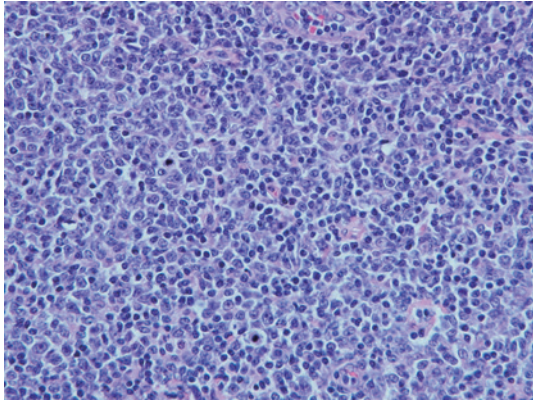
	Age	Sex	Site	Symptom	Clinical diagnosis	EBER
1	3	Female	Bil. Tonsil	Tonsillar Hypertrophy	Sleep Apnea Syndrome	Numerous
2	3	Male	Bil. Tonsil	Snoring	Sleep Apnea Syndrome	Numerous
3	5	Female	Bil. Tonsil	Snoring	Sleep Apnea Syndrome	Numerous
4	6	Female	Bil. Tonsil	Snoring	Sleep Apnea Syndrome	Numerous
5	7	Female	Bil. Tonsil	Snoring	Sleep Apnea Syndrome	Numerous
6	8	Female	Bil Tonsil	Snoring	Sleep Apnea Syndrome And Tonsillitis	Numerous
7	9	Female	Bil. Tonsil	Sore Throat	Habitual Angina	A Few
8	17	Female	Bil. Tonsil	Sore Throat	Habitual Angina	Numerous
9	30	Male	Bil. Tonsil	Sore Throat	Habitual Angina	A Few
10	39	Male	Bil. Tonsil	Snoring	Sleep Apnea Syndrome	A Few
11	41	Male	Bil. Tonsil	Sore Throat	Habitual Angina	Numerous
12	42	Female	Bil. Tonsil	Snoring	Habitual Angina	Numerous
13	42	Male	Bil. Tonsil	Sore Throat	Habitual Angina	Numerous
14	43	Male	Bil. Tonsil	Sore Throat	Habitual Angina	A Few

Abbreviations: Bil., bilateral; EBER, Epstein-Barr virus-encoded small RNA

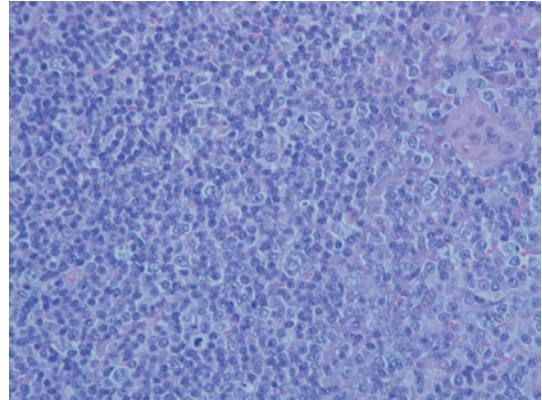
with small but conspicuous nucleoli. Histiocytes with or without epithelioid cell features were seen in all 14 lesions. In one lesion (No. 3), epithelioid cell clusters were found in the germinal center. In 4 lesions (nos. 2,7,9, and 14), the pale clear zone contained numerous eosinophils. A portion of immunoblasts with large vesicular nuclei and prominent nucleoli resembled binucleated-Reed-Sternberg-like cells

and mononuclear-Hodgkin-like cells featuring two large nuclei with prominent basophilic nucleoli in three lesions (nos. 2,6 and 10) (Fig. 3).

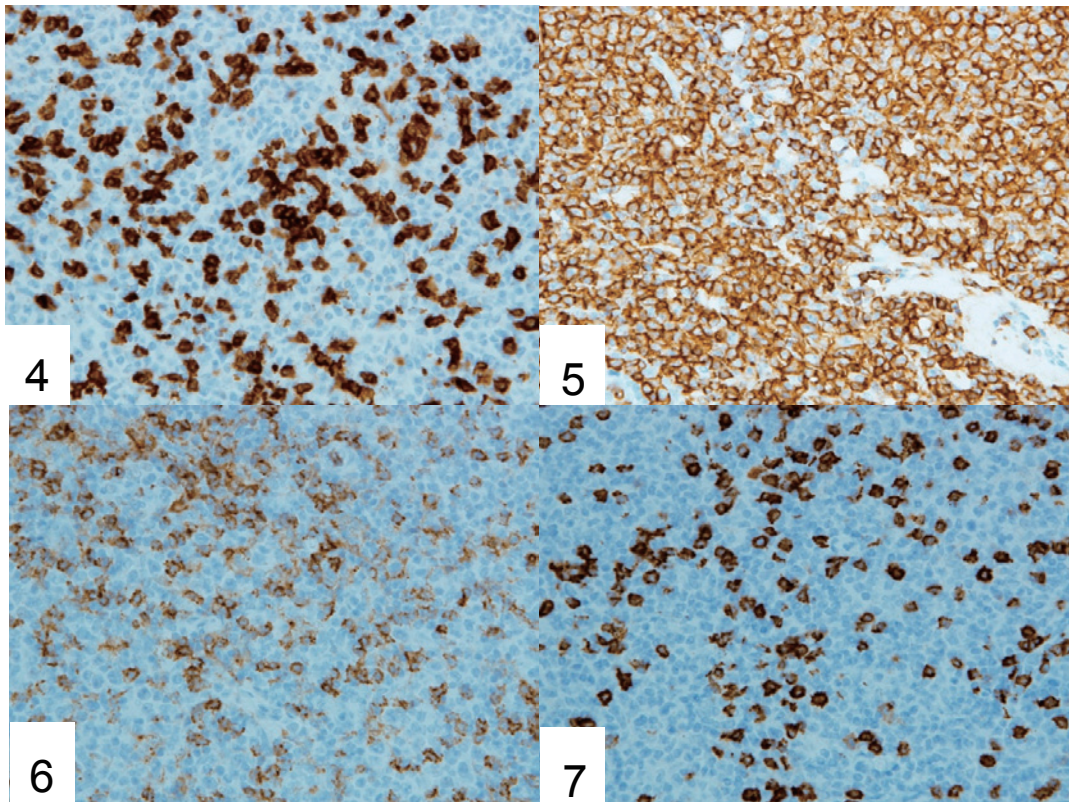
Immunohistologically, medium to large cells, including immunoblasts, were a mixture of T and B cells in the pale clear zone (Figs. 4 and 5). The T cells that expressed either CD4 (Fig. 6) or CD8 (Fig. 7) were approximately equal in



**Fig. 2.** On a high-power field, the pale zone composed of numerous medium to-large sized lymphocytes with clear cytoplasm, various number of immunoblasts, plasma cells and scattered neutrophils. The medium- to large sized lymphocytes occasionally had twisted nuclei with small but conspicuous nucleoli. HE. Case 2



**Fig. 3.** Note immunoblasts with large vesicular nuclei and prominent nucleoli resembled binucleated-Reed-Sternberg-like cells and mononuclear-Hodgkin-like cells that featuring two large nuclei with prominent basophilic nucleoli. HE. Case 9



**Fig. 4.** CD5-positive T-cells in the pale clear zone. Case 6  
**Fig. 5.** CD20-positive B-cells in the pale clear zone. Case 6  
**Fig. 6.** CD4-positive T-cells in the pale clear zone. Case 1  
**Fig. 7.** CD8-positive T-cells in the pale clear zone. Case 1

number. However, the majority of the large cells, including immunoblasts, were positive for CD8 (Fig. 7), TIA-1 (Fig. 8), and Granzyme B. There were no CD56-positive cells in the lesions. A portion of immunoblasts, including cells resembling Hodgkin's cells, were CD30-positive. There were no CD10-, bcl-6-, or PD-1-positive T cells in the pale clear zone. Scattered CD10- and bcl-6-negative and MUM-1-positive large B cells were present in the pale clear zone (Fig. 9). Staining with a monoclonal antibody against 2G9 highlighted the meshwork of follicular dendritic cells (FDCs). Although most of the FDC meshwork maintained a regular arrangement, a portion was broken into clusters. However, there was no FDC proliferation surrounding the blood vessels.

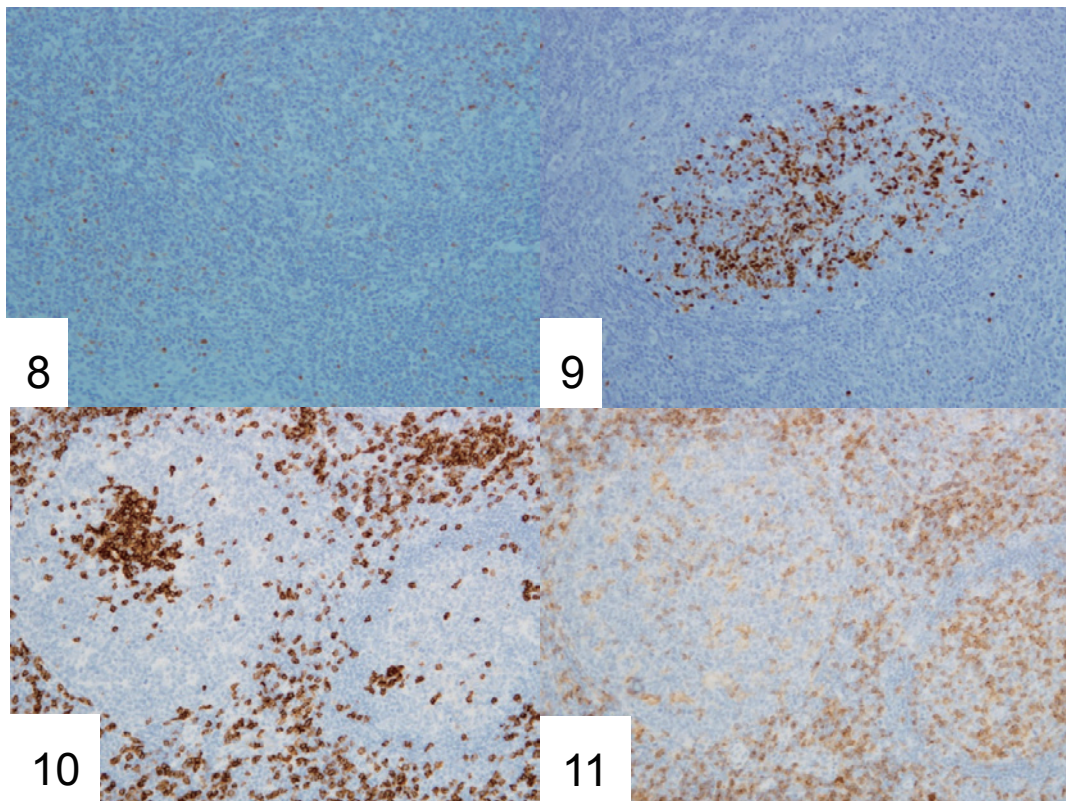
On ISH, EBER-positive cells were found in all 14 lesions. The number of EBER-positive cells exceeded 200 in 8 lesions (nos. 1-4, 6, 8, 11, and 12). In 2 lesions (nos. 5 and 13), approximately 50 EBER-positive cells were found. In 4 lesions (nos. 7, 9, 10, and 14), fewer than 10 EBER+ cells were found in the tonsils. EBER-positive cells were located in the germinal centers as well as in interfollicular areas in 8 lesions (nos. 2, 3, 6, 8, and 11-14) (Fig. 10), whereas EBER+ cells were located only in the interfollicular area in the remaining 6 (nos. 1, 4, 5, 7, 9, and 10).

In 4 lesions (nos. 2, 6, 8, and 11), there were numerous EBER-positive cells in the germinal centers. The majority

of the germinal center T cells were positive for CD8 (Fig. 11), TIA-1, and Granzyme B, with only a few CD4-positive T cells (Fig. 12).

## DISCUSSION

EBV-associated lymphoproliferative disorders (LPDs) may present marked histological diversity,<sup>1,3-7,10</sup> including (i) Hodgkin lymphoma like lesions, (ii) T-cell/histiocyte-rich large B cell lymphoma-like lesions, and (iii) marginal zone B cell lymphoma of mucosa-associated lymphoid tissue (MALT) like lesions. Some patients were asymptomatic and had no abnormal laboratory findings.<sup>6,11</sup> Hudnall *et al.*<sup>12</sup> examined 356 tonsillectomy specimens and reported the distribution pattern of EBV-infected cells using ISH. According to their study, nearly 60% of the EBER-positive cells were found within the T-cell-rich interfollicular regions, whereas 27% were present within the crypt epithelium, and 15% were present within the B-cell-rich germinal centers of secondary follicles. However, they did not describe the clinical or laboratory findings. Moreover, the morphological characteristics of EBV-infected cells in the interfollicular regions are unclear. In this report, we identified 14 (10.6%) of 131 specimens with a "pale clear zone" in the tonsils using ISH. To our knowledge, the "pale clear zone" has not been previously described in symptomatic IM in the tonsils.<sup>3, 5, 7, 13, 14</sup>



**Fig. 8.** Scattered MUM-1-positive large B-cells were present in the pale clear zone. Case 4

**Fig. 9.** Numerous EBER-positive cells were located in the germinal centers as well as interfollicular areas. ISH. Case 6

**Fig. 10.** Numerous germinal center T-cells were positive for CD8.

**Fig. 11.** Scattered germinal center T-cells were CD4-positive. Case 11

Kurth *et al.*<sup>15</sup> reported that the presence of numerous EBER+ cells in the germinal centers as well as in the interfollicular area may be characteristic of recent EBV infection or the reactivation of EBV (infectious mononucleosis pattern). Although double-staining of CD20 and EBER ISH was not performed, we also considered EBV positive cells to be B-cells. Numerous EBER-positive cells were located in the germinal centers as well as in interfollicular areas in 8 lesions. This suggests that a part of the “pale clear zone” may be a characteristic histological finding of EBV-associated LPDs in the interfollicular area of the tonsils. Some studies<sup>7,13,16</sup> found that CD8-positive cells were predominantly T cells in the paracortex of EBV-associated LPDs.

Louissaint<sup>7</sup> *et al.* demonstrated by immunohistochemistry for CD4 and CD8 a significantly low or inverted CD4:CD8 ratio in the tonsils (12/14). In our study there was an equal CD4:CD8 ratio (14/14). However, in reactive lymphoid hyperplasia, CD4-positive cells are the predominant T cells in the interfollicular area.<sup>17</sup> Furthermore, in our 14 lesions, the majority of the large T-lymphocytes, including T-immunoblasts, were CD8-, TIA-1-, and granzyme B-positive cytotoxic T cells.<sup>18</sup>

In 2 of our 14 lesions, numerous CD8-, TIA-1-, and granzyme B-positive cytotoxic T cells were present in the EBER-positive germinal centers. EBV infects CD10- and bcl-6-positive germinal center B cells. This observation indicated that cytotoxic T cells had removed the EBV-infected B cells.<sup>19</sup> However, in the remaining 12 lesions, this phenomenon was absent, suggesting that the EBV-infected B cells had already been removed by the cytotoxic T cells.<sup>7,13,17-19</sup>

As 8 of our patients were under 20 years of age, asymptomatic IM could not be ruled out. The other 6 patients were over 30 years old. These patients may have had EBV reactivation in their tonsils. However, during the follow-up period, they did not develop chronic active EBV infection or EBV-associated lymphoma.

EBV-associated LPDs may be misdiagnosed as malignant lymphomas. The differential diagnosis of a “pale clear zone” from angioimmunoblastic T-cell lymphoma (AITL) with tonsillar involvement may be difficult using a small biopsy specimen.<sup>13</sup> Lennert and Feller<sup>20</sup> reported that caution is needed when diagnosing AITL in childhood and young adolescence, as these cases are likely to be viral infections. A “pale clear zone” contains numerous medium to large T cells with irregular nuclei, pale clear cytoplasm, and varying numbers of B-immunoblasts, plasma cells, and neutrophils. AITL is characterized by: (i) a polymorphous infiltrate containing atypical medium-sized neoplastic cells with clear cytoplasm admixed with small lymphocytes, histiocytes, immunoblasts, eosinophils, and plasma cells, (ii) prominent arborizing blood vessels, (iii) FDC proliferation surrounding blood vessels, and (iv) the presence of EBV-transformed B cells.<sup>20-23</sup> Moreover, based on immunohistochemical studies, clear cells are CD4-, CD10-, bcl-6-, PD-1-, and CXCL3-positive follicular helper T cells. However, in our 14 lesions, immunohistochemical

study demonstrated mixed cells with clear cytoplasm, and CD4 and CD8 positivity. In the interfollicular area, there were no CD10-, bcl-6-, and PD-1-positive cells in any of our 14 lesions. Proliferation of FDCs was not detected by CD21 immunostaining. However, CD10- and bcl-6-negative, and MUM-1-positive large B-cells, one of the characteristic immunohistological findings of EBV-associated LPDs, were present in our 14 lesions.<sup>7</sup>

In summary, the present study demonstrated that a “pale clear zone” should be taken into consideration when assessing asymptomatic EBV-associated LPDs in the tonsils of children and young adolescents as well as in middle-aged patients. Differentiation between a “pale clear zone” and AITL may be difficult, particularly using small biopsy specimens. Detailed immunohistochemical studies, and analyses of clinical and laboratory findings are needed to avoid overdiagnosis and overtreatment. In middle-aged patients with habitual angina, numerous EBV+ tonsillectomy specimens suggest EBV reactivation.

## AUTHOR'S NOTE

Preliminary findings of this study were presented at the 14<sup>th</sup> Japanese-Korean Lymphoreticular Workshop-2018, January 26-27, 2018, Hakone.

## CONFLICT OF INTEREST

The author(s) declare no potential conflicts of interest with respect to research, authorship, and/or publication of this article.

## FUNDING

The author(s) received no financial support for research, authorship, and/or publication of this article.

## REFERENCES

- 1 Ioachim HL, Jeffrey LM. Ioachim's Lymph Node Pathology. 4<sup>th</sup> ed, Philadelphia, Lippincott Williams & Wilkins. 2008; pp. 493-494.
- 2 Henle W, Henle GE, Horwitz CA. Epstein-Barr virus specific diagnostic tests in infectious mononucleosis. *Hum Pathol.* 1974; 5 : 551-565.
- 3 Childs CC, Parham DM, Berard CW. Infectious mononucleosis. The spectrum of morphologic changes simulating lymphoma in lymph nodes and tonsils. *Am J Surg Pathol.* 1987; 11 : 122-132.
- 4 Shin SS, Berry GJ, Weiss LM. Infectious mononucleosis. Diagnosis by in situ hybridization in two cases with atypical features. *Am J Surg Pathol.* 1991; 15 : 625-631.
- 5 Strickler JG, Fedeli F, Horwitz CA, *et al.* Infectious mononucleosis in lymphoid tissue. Histopathology, in situ hybridization, and differential diagnosis. *Arch Pathol Lab Med.* 1993; 117 : 269-278.
- 6 Kojima M, Kashimura M, Itoh H, *et al.* Epstein-Barr virus-related reactive lymphoproliferative disorders in middle-aged or

- elderly patients presenting with atypical features. A clinicopathological study of six cases. *Pathol Res Pract.* 2007; 203 : 587-591.
- 7 Louissaint A, Ferry JA, Soupir CP, *et al.* Infectious mononucleosis mimicking lymphoma: distinguishing morphological and immunophenotypic features. *Mod Pathol.* 2012; 25 : 1149-1159.
  - 8 Ikeda T, Kobayashi R, Horiuchi M, *et al.* Detection of lymphocytes productively infected with Epstein–Barr virus in non-neoplastic tonsils. *J Gen Virol.* 2000; 81 : 1211-1216.
  - 9 Endo LH, Ferreira D, Montenegro MCS, *et al.* Detection of Epstein-Barr virus in tonsillar tissue of children and the relationship with recurrent tonsillitis. *Int J Pediatr Otorhinolaryngol.* 2001; 58 : 9-15.
  - 10 Eliane S, Dias P, Lage Da Rocha M, *et al.* Detection of Epstein-Barr virus in recurrent tonsillitis. *Braz J Otorhinolaryngol.* 2009; 75 : 30-34.
  - 11 Kaneko Y, Kojima M, Suzuki S, *et al.* Atypical interfollicular hyperplasia of tonsils resembling mucosa-associated lymphoid tissue lymphoma: a clinicopathological, immunohistochemical study and epstein-barr virus findings in 12 cases. *J Clin Exp Hematop.* 2014; 54 : 111-116.
  - 12 Hudnall SD, Ge Y, Wei L, *et al.* Distribution and phenotype of Epstein – Barr virus - infected cells in human pharyngeal tonsils. *Mod Pathol.* 2005; 18 : 519-527.
  - 13 Auerbach A, Aguilera NS. Epstein–Barr virus (EBV)-associated lymphoid lesions of the head and neck. *Semin Diagn Pathol.* 2015; 32 : 12-22.
  - 14 Wenig BM, Childers ELB, Richardson MS, *et al.* Atlas of Nontumor Pathology, First series, Fascicle 11. Non-Neoplastic Disease of the Head and Neck. Washington, DC, Armed Forces Institute of Pathology. 2017; pp. 230-234.
  - 15 Kurth J, Hansmann M-L, Rajewsky K, *et al.* Epstein-Barr virus-infected B cells expanding in germinal centers of infectious mononucleosis patients do not participate in the germinal center reaction. *Proc Natl Acad Sci U S A.* 2003; 100 : 4730-4735.
  - 16 Pittaluga S. Viral-associated lymphoid proliferations. *Semin Diagn Pathol.* 2013; 30 : 130-136.
  - 17 Jaffe ES, Arber DA, Campo E, Harris NL, Quintanilla-Martinez L. *Hematopathology.* 2<sup>nd</sup> ed, Philadelphia, PA, Elsevier. 2016; pp. 547-607.
  - 18 Klein E, Ernberg I, Masucci MG, *et al.* T-cell response to B-cells and Epstein-Barr virus antigens in infectious mononucleosis. *Cancer Res.* 1981; 41 : 4210-4215.
  - 19 Roughan JE, Torgbor C, Thorley-Lawson DA. Germinal center B cells latently infected with Epstein-Barr virus proliferate extensively but do not increase in number. *J Virol.* 2010; 84 : 1158-1168.
  - 20 Lennert K, Feller AC. *Histopathology of Non-Hodgkin's Lymphomas.* 2nd ed. Berlin, Springer-Verlag. 1992; pp. 196-210.
  - 21 Agostinelli C, Hartmann S, Klapper W, *et al.* Peripheral T cell lymphomas with follicular T helper phenotype: a new basket or a distinct entity? Revising Karl Lennert's personal archive. *Histopathology.* 2011; 59 : 679-691.
  - 22 Dogan A, Attygalle AD, Kyriakou C. Angioimmunoblastic T-cell lymphoma. *Br J Haematol.* 2003; 121 : 681-691.
  - 23 Dogan A, Gaulaud P, Jaffe ES, *et al.* Angioimmunoblastic T-cell lymphoma and other nodal lymphomas of T-follicular helper origin. In: Swerdlow SH, Campo E, Harris NL, Jaffe ES, Pileri S, Stein H, Thiele JV (eds). *WHO Classification of Tumor of Hematopoietic and Lymphoid Tissues.* Revised 4<sup>th</sup> edn. Lyon, IARC Press. 2017; pp. 407-412.