

Fistulectomy of the Parotid Fistula Secondary to Suppurative Parotitis: A Case Report

Anil Managutti¹, Saba Tiwari², Michael Prakasam³, Nagaraj Puthanakar⁴

Contributors:

¹Professor and Head, Vice Principal, Department of Oral and Maxillofacial Surgery, Narsinbhai Patel Dental College and Hospital, Visnagar, Gujarat, India; ²Senior Lecturer, Department of Oral and Maxillofacial Surgery, Modern Dental College and Research Centre, Indore, Madhya Pradesh, India; ³Reader, Department of Oral and Maxillofacial Surgery, Modern Dental College and Research Centre, Indore, Madhya Pradesh, India; ⁴Reader, Department of Prosthodontics, ACPM Dental College, Dhule, Maharashtra, India.

Correspondence:

Dr. Managutti A. Department of Oral and Maxillofacial Surgery, Narsinbhai Patel Dental College and Hospital, Visnagar, Gujarat, India. Phone: +91-9727756155. Email: dranilman12@rediffmail.com

How to cite the article:

Managutti A, Tiwari S, Prakasam M, Puthanakar N. Fistulectomy of the parotid fistula secondary to suppurative parotitis: A case report. *J Int Oral Health* 2015;7(1):59-62.

Abstract:

A parotid fistula is a communication between the skin and a parotid duct or gland through which saliva is discharged. The most common cause of the parotid fistula is trauma. The major causes of parotid trauma in a civilian practice are penetrating injury to the parotid gland from an assault weapon or injury due to shattered glass after a motor vehicle accident. Acute suppurative parotitis can rarely produce a parotid fistula, and it will be difficult to manage successfully. In this article we have described diagnosis by fistulography, meticulous dissection, and complete excision of the fistulous tract with layered closure of the parotid fascia followed by application of a post-operative pressure bandage, use of anticholinergic agents and antibiotics contribute significantly to the successful management of this difficult clinical condition.

Key Words: Fistulography, parotid fistula, suppurative parotitis

Introduction

A parotid fistula is an epithelialized tract between the skin or mucosa and a parotid duct or gland through which saliva is discharged. The opening site for fistula can be retroauricular region, skin over the facial cheek or oral mucosa. Most of the time these parotid fistulas result of facial trauma from penetrating injury to the parotid gland from sharp weapons, or injury due to shattered glass after a motor vehicle accident. The other causes can include malignancy, operative complications of parotid gland or rhytidectomy and infections of the parotid gland. They can also occur as a congenital malformation during fetal development leading to ectopic accessory parotid gland.¹ Acute infections of the parotid

gland can rarely produce a parotid fistula. These fistulas may occur due to a glandular or a ductal injury during incision and drainage/self-drainage of pus in infections. In glandular fistulas, discharge is less and tends to heal spontaneously with conservative treatment, whereas ductal fistulas continuously discharge the saliva, and spontaneous healing is very rare.² An internal parotid fistula commonly presents as a sialocele or an effusion, whereas communication with the skin leads to an external parotid fistula.³ Flow through the fistula increases during meals, particularly during mastication, this confirms the diagnosis.¹ Parotid fistula is distressing to the patient because of continuous dribble of saliva during mastication.⁴ Timely treatment is important since fistulae may result in wound dehiscence and infection of the buccal space. Early recognition and intervention are necessary to achieve successful treatment.⁵ Numerous methods of treatment have been described with varying success and morbidity. A rare case of the parotid fistula can be diagnosed by fistulography and treated by meticulous dissection and complete excision of the fistulous tract with layered closure of the parotid fascia. Post-operative pressure bandage application, use of anticholinergic agents and antibiotics has a synergetic effect in the management of this difficult clinical condition is described.

Case Report

A 25-year-old female patient reported with a complaint of watery discharge from her right cheek region since last 1 year. Patient gave history of fever and malaise associated with swelling in the right cheek region, which increased in size gradually and did not decrease for the next 15 days. Patient applied balm and hot fomentation over the swelling and the swelling started draining with purulent discharge over the cheek region. Patient consulted a local physician and was prescribed some medications for 5 days subsiding the swelling and pus discharge. Since then, watery discharge started from the same region. According to the patient, the discharge increased during meals. Patient received consultation from various places for the same but did not get any relief. Patient also consulted a local dentist for the same complain and underwent surgical extraction of the lower right third molar, which was impacted. Even 10 days after-the extraction, patient had no relief and then she was referred to our institution.

Patient gave no contributory medical history with a healthy familial background and no personal abusive habits. Extra-oral examination revealed a scar tissue on the right cheek on

anterosuperior region of the angle of mandible, oval in shape and approximately 1 cm × 1.5 cm in size. The surrounding skin appeared to be normal. A small pinpoint opening (Figure 1) was seen just above the scar from which watery fluid discharged spontaneously which increased on sucking lemon. On palpation, all inspectory findings were confirmed. The scar was completely healed and attached to the underlying deeper structures. The discharged fluid was watery, non-sticky, and thin in consistency. Right submandibular lymph nodes were palpable, enlarged, freely movable and non-tender, measuring approximately 1 cm in size. Intraoral examination revealed healing extraction socket with 48 with no tenderness present on the same region. The parotid papilla appeared to be normal. Mild salivary flow was seen from right parotid papilla along with more flow from fistula on milking of right parotid gland and rest of the oral cavity showing normal wet ability with saliva (Figure 2).

Ultrasonographic examination revealed normal echostructure of the right parotid gland with smooth margins, giving no evidence of any solid or cystic lesion. A small collection was seen in the anteroinferior margin of the right parotid, which measured 5 mm × 3 mm approximately. The contents were

anechoic, and a small 1.5 mm sinus tract was seen from the collection to the skin.

On radiographic examination with insertion of gutta percha point in the fistula revealed in the parotid region (Figure 3). Fistulography, as well as sialography, was performed using 70% urografin contrast media which revealed its relation with parotid duct. When the urografin solution was injected into the parotid duct intra-orally the solution came out from the fistulous tract extra-orally immediately without entering into the gland tissue. This was seen because of least resistance felt on this route. Hence, a false filling defect in radiograph was noted, and solution could not enter the gland because of direct communication of fistulous tract and duct (Figure 4). The final diagnosis was given as persistent parotid fistula with right parotid duct secondary to chronic suppurative parotitis.

Patient was taken under short general anesthesia; methylene blue ink was injected into the fistulous opening using a 26-gauge needle to identify the tract. An elliptical incision of 1 cm diameter was taken around the fistulous opening, which included the scar tissue. The skin island was then held with skin hooks and the subcutaneous tissue dissected until the fistulous tract containing dye was visible.

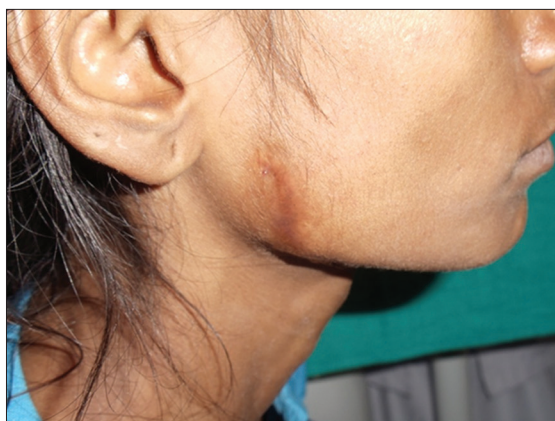

Figure 1: Pinpoint opening over scar tissue.

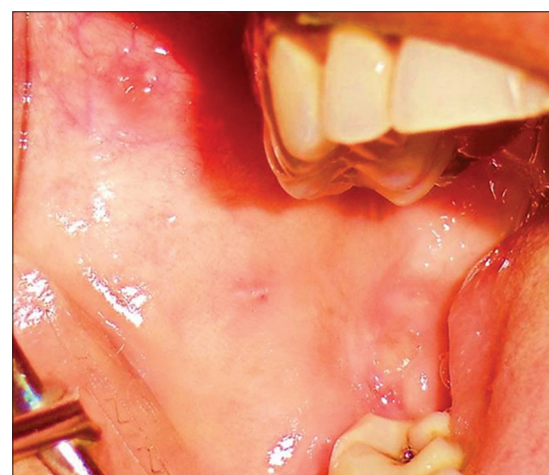

Figure 2: Salivary flow intra-orally.

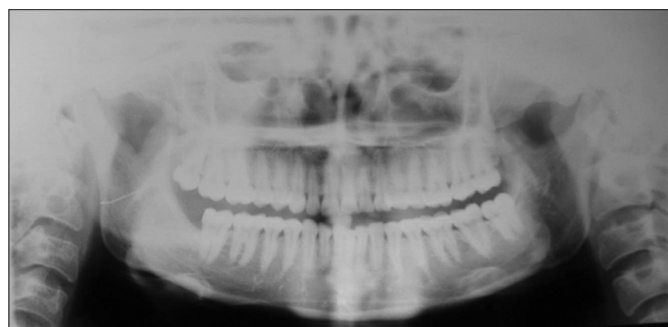


Figure 3: Gutta-percha in fistula.

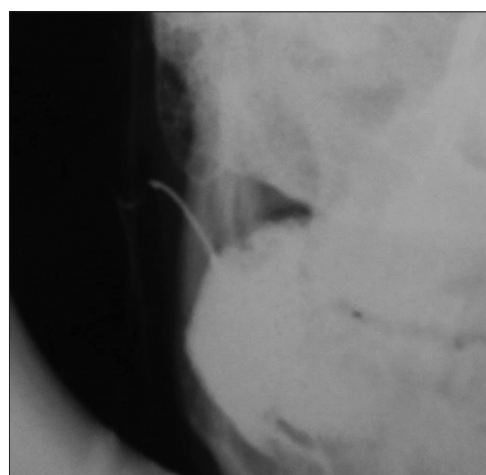


Figure 4: Fistulography.

The fistulous tract was then traced proximally until it entered the thick parotid fascia. The fascia was incised, and the tract was traced up to the superficial lobe of the parotid. Superficial lobe of the parotid was carefully dissected, and fistulectomy was done after ligating the attachment of the fistulous tract to the Stenson's duct (Figure 5). Closure was done in two layers using vicryl 3-0 and nylon 4-0 sutures (Figure 6) followed by tight pressure dressing. Patient was discharged with oral amoxicillin with cloxacillin, diclofenac sodium, and cetirizine on third post-operative day. Sutures were removed on the 7th day. Regular follow-up was done for 1 year, the fistulous tract healed satisfactory (Figure 7) and no complain of recurrence was encountered by the patient. The salivary flow was also adequate and was periodically checked by sucking lime.

Discussion

The most common cause of the parotid fistula is trauma, followed by malignancy, operative complications (parotidectomy), and infection.¹ Various other causes of parotid injuries are rupture of parotid abscess, inadvertent incision of parotid abscess and gunshot wounds.² Suppurative parotitis can rarely produce a parotid fistula as seen in our case.

Fistulas can be diagnosed by history and clinical examination of watery discharge from the fistula during meals or use of the lemon test as noted in our case. In the case of any doubt, serum amylase analysis of the fluid and sialo-fistulography can be done. The continuous dribbling of clear serous fluid from fistula was evident clinically on sighting food and while eating (Figure 1) and was further confirmed by the milking of the left parotid gland.⁶

Computed tomography or fistulography is helpful to look for the extent of the fistula. Fistulography is a radiographic procedure that demonstrates the origin and extent of fistulae (abnormal passages, usually between two internal organs). In this method, the tract is filled with a radiopaque contrast medium (70% urografin), usually under fluoroscopic control. Right angle and oblique projections are occasionally required to demonstrate the full extent of a sinus tract while digital sialography with fistulography demonstrates the precise anatomic location of a fistula.⁶ Sialography and fistulography were done in this case to locate the site of the fistula. Sonography was performed to know the condition of the gland and duct and revealed 1.5 mm sinus tract from parotid duct to the skin.

The parotid duct is 7 cm long and arises from the anterior border of the gland, crosses over the masseter and turns medially at its anterior border to pierce the buccinator. It travels for a while beneath the buccal mucosa and opens in the papilla opposite the second maxillary molar.

The course of the duct can be marked on the surface as the middle third of a straight line drawn from the anterior aspect of the tragus to the midpoint of the upper lip. The duct is accompanied by the buccal branch of the facial nerve and the transverse facial artery

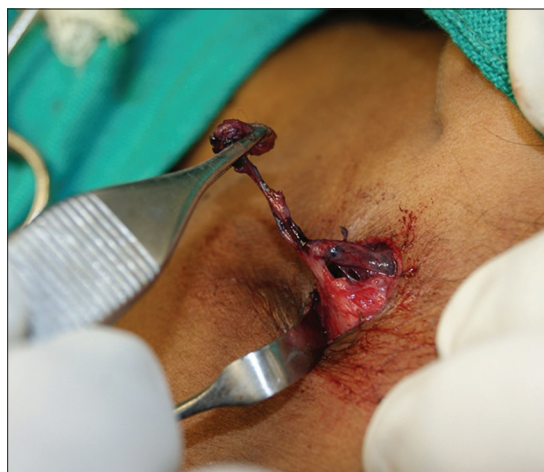

Figure 5: Relation of fistulous tract with Stenson's duct.

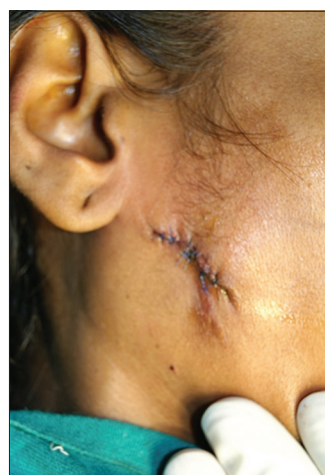

Figure 6: Suturing.

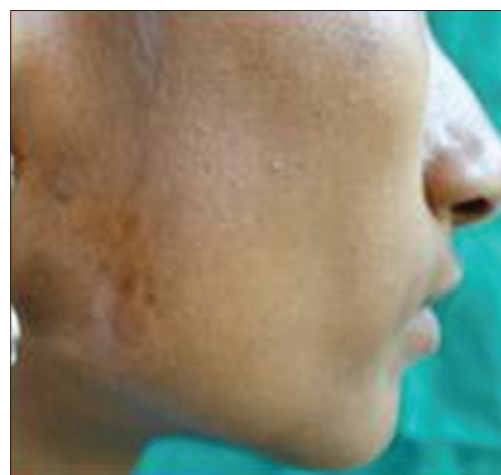

Figure 7: Follow-up after 1 year.

during its course, and these structures are at risk of injury during surgery for the duct fistula. Wounds across this line should be assessed meticulously for injury to these structures.¹

Classification of parotid duct site injuries according to Van Sickels.⁷

A = Glandular portion;
B = Duct over the masseter muscle;
C = Duct distal to the anterior border of the masseter muscle

The method of treatment for the parotid fistula chosen is based on the time, site, and mechanism of injury. Early fistulae are self-limiting and can be managed conservatively by reducing the salivary secretions with use of anti-cholinergics and/or use of pressure dressing. Regular aspiration of the content should be done prior to compression dressing. Anticholinergic agents are used to suppress glandular function; a commonly used agent is propantheline bromide (Pro-Banthine), which inhibits the action of acetylcholine at the postganglionic nerve endings of the parasympathetic nervous system (adult dose 15 mg half an hour prior to meals). These drugs have many side effects such as xerostomia, constipation, photophobia, tachycardia, and urinary retention.

Recently, botulinum toxin (Botox) has become popular for the treatment of salivary fistulas, sialorrhea, and Frey's syndrome. Botulinum toxin type A works locally at the presynaptic neurons to inhibit the secretion of acetylcholine. This characteristic makes this treatment approach a viable and conservative technique for the treatment of salivary fistulas after parotid duct injuries. The proposed technique for the use of Botox in the parotid gland, according to the cologne protocol, 18 requires the reconstitution of the toxin with 4 mL of preservative-free normal saline to obtain a 25 mU/0.1 mL concentration. Between 0.1 and 0.2 mL are injected at each point on the parotid gland. Depending on the size of the gland, 4-10 points are injected on the parotid. The injections are preferably performed under sonographic control with a 7.5 Hz linear transducer. In general, a significant decrease of the salivary production is seen within the first 2 weeks after the injections and the duration of the effect averages between 2 and 3 months. Minimal side effects are seen with this protocol. But as this is a very expensive treatment to the patient, it is not possible for every patient to take Botox therapy.⁸ There are 3 other methods generally employed to manage duct lacerations. These are primary repair of the duct with microsurgical anastomosis, diversion of salivary flow by creation of an oral fistula, and suppression of salivary gland function. Diversion of parotid secretion into the mouth can be done by various methods one of these are reconstructive methods; which include reconstruction of duct with vein graft, mucosal flaps or suturing of proximal duct to the buccal mucosa. The other method is the formation of a controlled internal fistula which could be done by either T-tube or catheter drainage into the mouth or the drainage of

proximal duct by a catheter. Another technique is parotidectomy that locally treats the fistula by excision of the fistulous tract with the parotid duct or cauterization of the duct. Depression of parotid secretion also be done by various surgical approaches that include duct ligation and sectioning of the auriculotemporal or Jacobsen's nerve. Radiotherapy has also been found useful in the parotid gland fistula.⁶

Conclusion

Diagnosis of fistula is done by fistulography, intraoperative fistulography helps in meticulous dissection and complete excision of the fistulous tract with layered closure of the parotid fascia. Application of a post-operative pressure bandage, use of anticholinergic agents and antibiotics helps in healing.

In our case, the biggest challenge for repair was the presence of a dense fibrous scar over the area of injury making the attempt to repair the ductal injuries almost impossible. We excised the fistulous tract and sutured parotid fascia and skin. Patient got complete relief, and no recurrence was reported in a period of follow-up for 1 year.

Acknowledgments

We thank Dr. Sunita Managutti and, Dr. Arti Choudhary for their timely guidance and valuable support.

References

1. Naragund AI, Halli VB, Mudhol RS, Sonoli SS. Parotid fistula secondary to suppurative parotitis in a 13-year-old girl: a case report. *J Med Case Rep* 2010;4:249.
2. Ajike SO, Omisakin OO. The use of a feeding tube in the treatment of a parotid duct fistula: A case report. *J Med Med Sci* 2011;2(8):1014-6.
3. Parekh D, Glezerson G, Stewart M, Esser J, Lawson HH. Post-traumatic parotid fistulae and sialoceles. A prospective study of conservative management in 51 cases. *Ann Surg* 1989;209(1):105-11.
4. Shetty N, Pandey A, Mokal N. Dental sinus with parotid duct fistula: An unusual presentation. *Indian J Plast Surg* 2007;40(2):213-6.
5. Srinidhi D, Shruthi R. Parotid Sialocele and fistulae: Current treatment options. *Int J Contemp Dent* 2011;2(1):9-12.
6. Chow TL, Kwok SP. Use of botulinum toxin type A in a case of persistent parotid sialocele. *Hong Kong Med J* 2003;9(4):293-4.
7. Dalili Z. Sialography and fistulography of post traumatic fistulae; A case presentation. *J Dent* 2005;2(2):70-3.
8. Van Sickels JE. Parotid duct injuries. *Oral Surg Oral Med Oral Pathol* 1981;52(4):364-7.