



Usefulness and Safety of Gelatin–Thrombin Matrix Sealants in Minimally Invasive Microscopic Discectomy

Yushi Sakamoto^{1,2} Seiichiro Naruo¹ Tomonori Ozaki¹ Shogo Tahata¹ Toru Fujimoto¹
Atushi Ogata² Fumitaka Yoshioka² Yukiko Nakahara² Jun Masuoka² Tatsuya Abe²

¹Department of Spine Surgery, Naruo Orthopedic Hospital, Kumamoto, Japan

²Department of Neurosurgery, Faculty of Medicine, Saga University, Saga, Japan

Address for correspondence Yushi Sakamoto, MD, Department of Spine Surgery, Naruo Orthopedic Hospital, 12-24 Okadamachi, Kumamoto-shi, Kumamoto 862-0958, Japan (e-mail: bebeko19831210@gmail.com).

Asian J Neurosurg 2024;19:478–483.

Abstract

Objective This study aimed to evaluate the usefulness and safety of gelatin–thrombin matrix sealants (GTMSs) in minimally invasive microscopic discectomy, a surgical procedure commonly used to treat lumbar disc herniation.

Materials and Methods Out of 484 patients who underwent minimally invasive microscopic discectomy between April 2018 and December 2022, 35 patients with a history of surgery at the same level were excluded, resulting in a total of 449 patients included in the study. Among them, 316 patients were treated using GTMS, whereas 133 were treated using collagen-based absorbable local hemostatic agents. Patient characteristics, surgical duration, intraoperative blood loss, postoperative drainage volume, intraoperative dural injury, and incidence of postoperative epidural hematoma were analyzed and compared between the two groups.

Results No significant differences in patient demographics were observed between the two groups, except for activated partial thromboplastin time and prothrombin time. Although there were no significant differences in the mean surgical time and intraoperative blood loss between the two groups, they tended to be shorter and less in the GTMS group (56.3 ± 20.2 vs. 58.2 ± 20.4 minutes [$p = 0.36$] and 10.0 ± 15.4 vs. 11.8 ± 8.3 g [$p = 0.20$]). The volume of postoperative drainage was significantly lower in the GTMS group than that in the comparison group (35.3 ± 21.8 vs. 49.5 ± 34.1 g [$p < 0.01$]). There was a trend indicating a difference in the number of intraoperative dural injuries and the need for reoperation due to postoperative epidural hematoma (2 vs. 3 ± 20.4 minutes [$p = 0.21$] and 1 vs. 2 [$p = 0.16$]).

Conclusion The use of a GTMS in minimally invasive microscopic discectomy appears to be beneficial in reducing postoperative drainage volume. It has also been shown that it may improve clinical outcomes such as intraoperative dural injury and postoperative epidural hematoma. Furthermore, further consideration of the medical economic impact is required.

Keywords

- ▶ gelatin–thrombin matrix sealants
- ▶ intraoperative blood loss
- ▶ lumbar disc herniation
- ▶ minimally invasive microscopic discectomy
- ▶ postoperative drainage volume
- ▶ tubular retractor

article published online
June 12, 2024

DOI <https://doi.org/10.1055/s-0044-1787777>.
ISSN 2248-9614.

© 2024. Asian Congress of Neurological Surgeons. All rights reserved.

This is an open access article published by Thieme under the terms of the Creative Commons Attribution-NonDerivative-NonCommercial-License, permitting copying and reproduction so long as the original work is given appropriate credit. Contents may not be used for commercial purposes, or adapted, remixed, transformed or built upon. (<https://creativecommons.org/licenses/by-nc-nd/4.0/>)

Thieme Medical and Scientific Publishers Pvt. Ltd., A-12, 2nd Floor, Sector 2, Noida-201301 UP, India

Introduction

Sciatica is often caused by lumbar disc herniation (LDH).¹ Patients with LDH often have a good natural history, and conservative treatment is the initial treatment of choice.² Surgery is recommended when patients with intractable pain are refractory to conservative treatment or experience progressive neuropathy.³

Since the first successful lumbar disc surgery was reported by Mixter and Barr⁴ in 1934, various surgical techniques have been developed. With the development of operating microscopes, microscopic discectomy was introduced by Caspar and Yasargil.⁵ Conversely, the development of the tubular retractor has allowed for less invasive and faster postoperative recovery than the traditional subperiosteal discectomy with dissection of the multifidus muscle.⁶ Furthermore, the use of a tubular retractor and an operating microscope has been reported to be as invasive as endoscopic surgery and helps in overcoming the disadvantage of the two-dimensional nature of endoscopic images.⁷ Therefore, we use a 16-mm-diameter tubular retractor in our institution to make microscopic discectomy less invasive.

However, the risk of postoperative bleeding is reported to be higher for minimally invasive, small skin incisions than that of conventional surgery.⁸ Gelatin–thrombin matrix sealants (GTMSs), which are absorbent localized hemostatic agents using gelatin containing human thrombin, are excellent hemostatic agents with strong primary and secondary hemostatic effects in addition to the tamponade effect of the gelatin foam.⁹ In the field of spine surgery, its usefulness for anterior decompression and fixation of the cervical spine¹⁰ and endoscopic laminectomy¹¹ has been reported; however, no reports on microscopic discectomy exist.

Therefore, this study aimed to investigate the usefulness and safety of the GTMS in minimally invasive microscopic discectomy.

Materials and Methods

Patients

This study was approved by the ethics committee of our hospital. During the period from April 2018 to December 2022, we included patients who underwent single-level microscopic discectomy at our hospital as the subjects of this study. Exclusion criteria comprised cases with previous surgery at the same level. LDH was diagnosed by spinal surgery attending physicians in all patients based on clinical findings, and magnetic resonance imaging (MRI) and computed tomography myelography results, and nerve root blocks were performed as required. All patients experienced symptoms in the lower extremities, and surgery was performed in patients with poor response to preoperative medical therapy and epidural block. GTMS was employed in instances characterized by a pronounced likelihood of hemorrhage emanating from the epidural venous plexus due to manipulation surrounding the nerve root, instances wherein achieving hemostasis posed a formidable challenge despite the utilization of collagen-based absorbable local hemostatic agents, and instances involving

patients who had been administered antiplatelet or anticoagulant medications prior to undergoing surgery. Preoperative antiplatelet and anticoagulant medications were withdrawn preoperatively and resumed on the day after drain removal. During the period from April 2018 to December 2022, cases where GTMS was employed intraoperatively were categorized into Group G, while cases utilizing collagen-based absorbable local hemostatic agents were allocated to Group C.

Surgical Procedures, Application of the Hemostatic Agent, and Postoperative Measurement of Drainage

Surgery was performed under a microscope using a tubular retractor for discectomy. All the patients underwent surgery under general anesthesia in the supine position. A 20-mm skin section and fascial incision were made, and a 16-mm-diameter tubular retractor was placed at the base of the spinous process using a dilator. The vertebral arch at the ligamentum flavum attachment site was osteotomized using a high-speed drill, and the ligamentum flavum was resected from the cephalad side using a Kerrison punch. Decompression of the lateral recess was performed up to the medial margin of the navicular vertebral arch while preserving the intervertebral joint as much as possible. Herniated disc removal was then performed using a nerve hook and retractor with suction while deflecting the dura mater and nerve root medially.

If used, GTMS was injected into the bleeding site (→Fig. 1A, B), and compression was applied over it for 2 minutes using sterilized Ben Sheets XR (Kawamoto Sangyo, Osaka-shi, Osaka, Japan) (→Fig. 1C). The sheets were then deflected, and the GTMS and blood clot complex were flushed with saline and removed

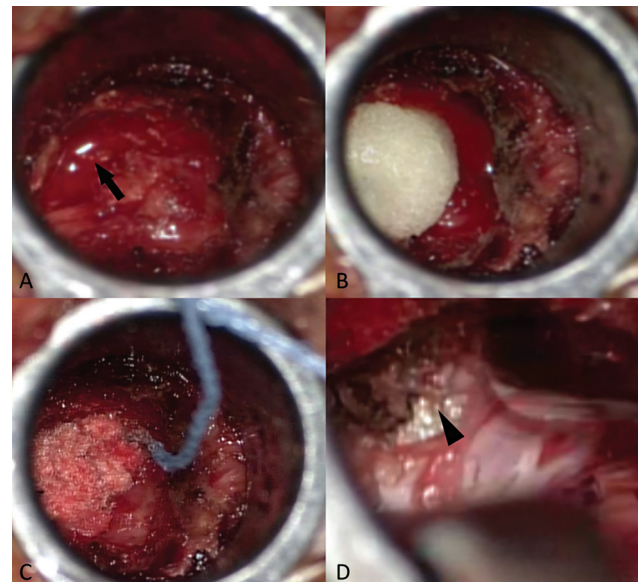


Fig. 1 (A) Intraoperative photos of L4/5 right lumbar disk herniation. The surgeon is standing on the left side. Venous bleeding continues from the foraminal area (arrow). (B, C) gelatin–thrombin matrix sealant is applied to the bleeding site, followed by 2 minutes of compression using Ben Sheets XR. After removing Ben Sheets XR, the thrombus complex is washed out and removed with saline solution. (D) Hemostasis has been achieved, and a clear field of view is obtained, revealing the intervertebral disc (intervertebral disc: arrowhead).

through aspiration (►Fig. 1D). When using collagen-based absorbable local hemostatic agents, the bleeding site was filled in the same manner, followed by compression with the sheet for 2 minutes, and then rinsing with saline for removal. After confirming complete hemostasis, the surgical field was washed again with saline solution, and a closed negative pressure drain was placed to close the wound. All patients were fitted with a soft orthosis, and gait training was initiated the day after surgery. Postoperative drainage was measured on the mornings of the day following surgery and second postoperative day. The drain was removed on the second postoperative day in all patients. Almost all patients were discharged home 1 to 2 weeks after the surgery.

Data Collection and Analyses

Two independent spine surgeons, who were not involved in the treatment of enrolled patients, performed patient selection and data collection. For all enrolled patients in each study group, the following factors were extracted from patient records: age, gender, body mass index (BMI), history of hypertension, history of diabetes, history of antiplatelet medication, history of anticoagulation, preoperative platelet count, activated partial thromboplastin time (APTT), prothrombin time (PT), and operative levels. The primary outcomes were operative time (minutes), intraoperative blood loss (g), total drainage volume (g), and the occurrence of intraoperative dural tear. In the secondary assessments, we investigated the necessity of hematoma evacuation surgery in instances of postoperative epidural hematoma. Comparisons between

groups were made using Student's *t*-test and considered statistically significant when the *p*-value <0.05.

Results

Between April 2018 and December 2022, a total of 484 patients underwent minimally invasive microscopic discectomy in our hospital. Among them, 35 patients with a history of surgery at the same level were excluded, resulting in 449 patients being included in this study. Out of the 449 patients included in the study, 316 patients were in Group G, and 133 patients were in Group C. ►Table 1 summarizes the characteristics and basic clinical information of Groups G and C. The mean age was 50.7 ± 16.6 years in Group G and 51.5 ± 16.8 years in Group C. Regarding sex, 218 (70.0%) of the patients in Group G and 37 (68.4%) in Group C were male. No statistically significant differences in age or sex were observed between the two groups ($p = 0.64$ and 0.91 , respectively). BMI was 24.6 ± 4.2 kg/m² for patients in Group G and 24.3 ± 3.7 kg/m² in Group C. No significant difference was noted between the two groups ($p = 0.37$). No significant difference was observed between the two groups in terms of a history of hypertension (99 [31.3%] in Group G and 31 [23.3%] in Group C) and diabetes mellitus (40 [12.7%] in Group G and 14 [10.5%] in Group C) ($p = 0.81$ and 0.63 , respectively). No significant difference in the use of antiplatelet (36 [11.4%] in Group G and 10 [7.5%] in Group C) and anticoagulant (2 [0.6%] in Group G and 0 [0%] in Group C) medications was noted between the two groups ($p = 0.24$ and >0.99 , respectively). Preoperative platelet count ($\times 10^4$) was

Table 1 Patient characteristics and basic clinical information in Groups G and C

	Group G (n = 316)	Group C (n = 133)	p-Value
Age (y)	50.7 ± 16.6	51.5 ± 16.8	0.64 ^a
Gender (male/female)	218/98	91/42	0.91 ^b
BMI	24.6 ± 4.2	24.3 ± 3.7	0.37 ^a
History of HT	99	31	0.81 ^b
History of DM	40	14	0.63 ^b
Medication of antiplate drugs	36	10	0.24 ^b
Medication of anticoagulants	2	0	1 ^b
Preoperative platelet count ($\times 10^4$)	24.1 ± 5.3	24.2 ± 5.1	0.83 ^a
Preoperative APTT (s)	27.3 ± 2.3	27.7 ± 2.5	0.08 ^a
Preoperative PT (s)	9.8 ± 0.5	10.0 ± 0.5	<0.01 ^a
Levels of LDH			
L1/2	2	1	0.98 ^b
L2/3	9	3	
L3/4	36	14	
L4/5	132	54	
L5/S	137	61	

Abbreviations: APTT, activated partial thromboplastin time; BMI, body mass index; DM, diabetes mellitus; HT, hypertension; LDH, lumbar disc herniation; PT, prothrombin time.

^aStudent's *t*-test.

^bFisher's exact test.

Table 2 Four postoperative measurements

	Group G (n = 316)	Group C (n = 133)	p-Value
Surgical time (min)	56.3 ± 20.2	58.2 ± 20.4	0.36 ^a
Intraoperative blood loss (g)	10.0 ± 15.4	11.8 ± 8.3	0.20 ^a
Drainage volume (g)	35.3 ± 21.8	49.5 ± 34.1	<0.01 ^a
Dural tear	2	3	0.16 ^b
Revision surgery for PSEH (n)	1	2	0.21 ^b

Abbreviation: PSEH, postoperative spinal epidural hematoma.

^aStudent's *t*-test.

^bFisher's exact test.

24.1 ± 5.3 in Group G and 24.2 ± 5.1 in Group C ($p = 0.83$). The preoperative APTT in patients of Group G was 27.3 ± 2.1 seconds, and in patients of Group C, it was 27.7 ± 2.5 seconds, showing a tendency for a shorter duration in Group G ($p = 0.08$). Moreover, the PT of patients in Group G (9.8 ± 0.5 seconds) was significantly shorter than that of patients in Group C (10.0 ± 0.5 seconds) ($p < 0.01$). No significant difference was noted between the two groups in operative levels of LDH ($p = 0.98$).

—**Table 2** summarizes the primary and secondary outcomes of this study. The following pertains to the four primary outcomes. The mean operative time was 56.3 ± 20.2 minutes for patients in Group G and 58.2 ± 20.4 minutes for those in Group C. No significant difference was observed between the groups ($p = 0.36$). The mean intraoperative blood loss was 10.0 ± 15.4 g for patients in Group G and 11.8 ± 0.6 g for patients in Group C, and although there was no significant difference between the two groups, there was a trend toward difference ($p = 0.20$). The volume of drainage before drain removal was significantly lower for patients in Group G (35.3 ± 21.8 g) than for those in Group C (49.5 ± 34.1 g) ($p < 0.01$). The incidence of dural injuries amounted to two occurrences in Group G and three occurrences in Group C, indicating an observable divergence in trends ($p = 0.21$). As a secondary outcome, the number of cases undergoing reoperation for postoperative epidural hematoma was one in Group G and two in Group C, indicating an observable trend of difference ($p = 0.16$).

Discussion

In this study, we compared the surgical time, intraoperative blood loss, drainage volume, and number of intraoperative dural injuries between the group that used GTMS and the group that did not use it as primary and secondary outcomes. Additionally, we compared the number of reoperations due to postoperative epidural hematoma as the secondary outcome. Regarding drainage volume, the GTMS group exhibited a significantly lower amount. While no statistically significant differences were observed in other outcomes, overall, the GTMS group demonstrated favorable results. Comparing patient backgrounds, we found that there was a tendency for differences in APTT and a significant difference in PT, but no differences were observed in patient backgrounds between the groups. Therefore, this study was considered to accurately

reflect the effects of the GTMS when compared with the control group.

GTMS is believed to produce local hemostatic effects in the following two aspects: First, the GTMS has a tamponade effect, which means that it physically reduces blood flow by expanding the volume by ~20% after coming into contact with the blood of the patient. Second, blood permeating between the cross-linked gelatin particles comes into contact with human thrombin, which converts fibrinogen to fibrin, thereby promoting the stabilization of the clot and assisting hemostasis.⁹ Because of its fluidity, GTMS is also expected to be effective in the hemostasis of bleeding from anatomically difficult sites, such as lateral recesses and depths of the intervertebral foramen in spinal surgery where hemostasis is difficult.¹⁰ Intraoperative hemostatic efficacy of GTMS has been reported in several cases outside the field of orthopaedic surgery.^{12–15} Li et al reported an anterior cervical fusion procedure and found that the volume of fluid drained from the drain at 24 hours postoperatively and that drained per 8 hours were <10 mL in the GTMS group compared with those in the non-GTMS group.¹⁰ In their report on endoscopic laminectomy, Nomura et al reported that intraoperative blood loss was higher in the GTMS group; however, postoperative drainage was lower in the GTMS group than in the nonuser group.¹¹ In this study, no significant difference in intraoperative blood loss was observed; however, postoperative drainage was significantly lower in the GTMS group, as in the previous study. Nomura et al pointed out that postoperative hemostasis may not have been sufficient to withstand extubation and subsequent hypertension.¹¹ However, the GTMS-reinforced clots were stronger than normal clots, which may have resulted in a difference in the postoperative drainage volume.

In this study, there was no significant difference in the average operative time between the two groups, but the operative time in Group G was about 2 minutes shorter. However, a previous study by Nomura et al reported that the surgical time was longer in the group using GTMS. In the study by Nomura et al, the use of GTMS required dissolving thrombin and mixing it with gelatin, which is thought to have prolonged surgical time. In this study, it is believed that the effectiveness of GTMS resulted in a shortened hemostasis procedure time and facilitated the surgical technique due to improved field visibility. As a result, the preparation time was offset, leading to no significant differences in the surgical duration between the groups.

Conversely, postoperative epidural hematoma of the spine can cause early postoperative neurological deterioration. The exact frequency is unknown, as most symptoms are limited to transient buttock pain or the lower extremities. However, an MRI study on microscopic lumbar discectomy reported that 14.6% of patients had an epidural hematoma regardless of the presence or absence of symptoms.¹⁶ Hematomas can occur for a variety of reasons; however, in cases of paralysis, a high percentage of patients are left with permanent disability if not treated promptly. Takami et al measured the hematoma area ratio on postoperative MRI in endoscopic laminectomy for lumbar spinal canal stenosis and reported that no difference was observed in the hematomas even with the use of prophylactic GTMS.¹⁷ In this study, removal of postoperative epidural hematoma was performed in both Groups G and C; however, no statistically significant difference was noted between the groups. As most postoperative hematomas are asymptomatic or present only with transient mild buttock or leg pain, further studies are required to determine whether the GTMS is effective in preventing hematomas that require removal.

GTMS has been reported to have economic effects in spinal surgery. Ramirez et al used Premier's US Perspective Hospital Database to compare cases in which GTMS alone was used versus GTMS plus a nonflowing hemostatic agent in spine surgery.^{18,19} According to their study, the GTMS alone group was superior in terms of average hospital stay, surgical time, amount of blood loss, and frequency of dural injury and bleeding-related complications, and it was reported that hospital resource utilization and medical costs were reduced. In this study, dural injuries was observed in two cases in Group G and three cases in Group C, and reoperation due to epidural hematoma was observed in one case in Group G and two cases in Group C. These results indicate that the use of GTMS in minimally invasive microscopic discectomy may reduce perioperative complications and reduce the use of medical resources. Japan and the United States have different medical systems, and the number of cases in this study was small, so it is thought that it is necessary to increase the number of cases to verify the medical economic effects in Japan.

One of the limitations of this study is that it was a retrospective study and not a prospective randomized trial. Although some homogeneity in patient background is expected, temporal changes in the study population and variations in surgeon skill level may potentially influence the results. Furthermore, although there was a significant difference in the volume of postoperative drainage, there was no significant difference in the use of GTMS in reducing intraoperative dural damage or postoperative epidural hematoma removal. Therefore, we were unable to determine the clinical usefulness of this study. Third, the impact of GTMS on postoperative clinical symptoms is unknown, and clinical outcome evaluations such as Japanese Orthopaedic Association score were not performed.

Conclusion

The use of GTMS significantly reduced postoperative drainage volume in minimally invasive microscopic discectomy. Additionally, there was a trend toward a reduction in intraoperative dural injuries and postoperative epidural hematoma removal procedures. This has the potential to be advantageous in terms of health care economics.

Authors' Contributions

Y.S. and S.N. designed the study; Y.S., T.O., and S.T. performed the experiments and analyzed the data; T.F., A.O., F.Y., Y.N., J.M., and T.A. conducted manuscript writing and provided guidance for statistical analysis; Y.S., T.O., and T.A. wrote the manuscript.

Ethical Approval

Ethical approval was waived by the ethics committee due to the retrospective study design.

Patients' Consent

Informed consent for all participants in this study was obtained through an opt-out process.

Funding

None.

Conflict of Interest

None declared.

References

- 1 Konstantinou K, Dunn KM. Sciatica: review of epidemiological studies and prevalence estimates. *Spine* 2008;33(22):2464–2472
- 2 Jacobs WC, van Tulder M, Arts M, et al. Surgery versus conservative management of sciatica due to a lumbar herniated disc: a systematic review. *Eur Spine J* 2011;20(04):513–522
- 3 Angevine PD, McCormick PC. Outcomes research and lumbar discectomy. *Neurosurg Focus* 2002;13(02):E8
- 4 Mixter W, Barr JS. Rupture of the intervertebral disc with involvement of the spinal canal. *N Engl J Med* 1934;211:1632–1638
- 5 Yasargil MG. Microsurgical operation of herniated lumbar disc. *Adv Neurosurg* 1977;(04):81–82
- 6 Foley KT, Smith MM. Microendoscopic discectomy. *Tech Neurosurg* 1997;3:301–307
- 7 Greiner-Perth R, Böhm H, El Saghir H. Microscopically assisted percutaneous nucleotomy, an alternative minimally invasive procedure for the operative treatment of lumbar disc herniation: preliminary results. *Neurosurg Rev* 2002;25(04):225–227
- 8 Nakagawa Y, Yoshida M. Posterior spinal endoscopic surgery and complications, especially postoperative hematoma and its countermeasures. *J Spine Res* 2013;4:7–15
- 9 Oz MC, Rondinone JF, Shargill NS. FloSeal Matrix: new generation topical hemostatic sealant. *J Card Surg* 2003;18(06):486–493
- 10 Li QY, Lee O, Han HS, et al. Efficacy of a topical gelatin-thrombin matrix sealant in reducing postoperative drainage following anterior cervical discectomy and fusion. *Asian Spine J* 2015;9(06):909–915
- 11 Nomura K, Yoshida M, Okada M, Nakamura Y, Yawatari K, Nakayama E. Effectiveness of a gelatin-thrombin matrix sealant

- (FloSeal®) for reducing blood loss during microendoscopic decompression surgery for lumbar spinal canal stenosis: a retrospective cohort study. *Global Spine J* 2023;13(03):764–770
- 12 Fiss I, Danne M, Stendel R. Use of gelatin-thrombin matrix hemostatic sealant in cranial neurosurgery. *Neurol Med Chir (Tokyo)* 2007;47(10):462–467
 - 13 Yao HH, Hong MK, Drummond KJ. Haemostasis in neurosurgery: what is the evidence for gelatin-thrombin matrix sealant? *J Clin Neurosci* 2013;20(03):349–356
 - 14 Brand Y, Narayanan V, Prepageran N, Waran V. A cost-effective delivery system for FloSeal during endoscopic and microscopic brain surgery. *World Neurosurg* 2016;90:492–495
 - 15 Echave M, Oyagüez I, Casado MA. Use of FloSeal®, a human gelatine-thrombin matrix sealant, in surgery: a systematic review. *BMC Surg* 2014;14:111
 - 16 Modi HN, Lee DY, Lee SH. Postoperative spinal epidural hematoma after microscopic lumbar decompression: a prospective magnetic resonance imaging study in 89 patients. *J Spinal Disord Tech* 2011;24(03):146–150
 - 17 Takami M, Yoshida M, Minamide A, et al. Does prophylactic use of topical gelatin-thrombin matrix sealant affect postoperative drainage volume and hematoma formation following microendoscopic spine surgery? A randomized controlled trial. *Spine J* 2021;21(03):446–454
 - 18 Ramirez MG, Niu X, Epstein J, Yang D. Cost-consequence analysis of a hemostatic matrix alone or in combination for spine surgery patients. *J Med Econ* 2018;21(10):1041–1046
 - 19 Ramirez MG, Deutsch H, Khanna N, Cheatem D, Yang D, Kuntze E. FloSeal only versus in combination in spine surgery: a comparative, retrospective hospital database evaluation of clinical and healthcare resource outcomes. *Hosp Pract* 2018;46(04):189–196