

Impact of fluidic parameters during phacoemulsification on the anterior vitreous face behavior: Experimental study

Vaishali Vasavada, Samaresh Srivastava, Viraj Vasavada, Shail Vasavada, Abhay R Vasavada, Aditya Sudhalkar, Alper Bilgic

Purpose: To evaluate the effect of different aspiration flow rates (AFR) and bottle heights (BH) on vitreous face (AVF) during phacoemulsification. **Methods:** Experimental study in 20 porcine eyes. Transzonular viscodissection was performed between the posterior capsule(PC) and AVF to dissect out the Berger's space. Triamcinolone acetonide was injected into this space to aid visualization with ultrasound B-Scan(USG). Realtime USG was performed during phacoemulsification. Eyes were divided randomly into Group I: Low parameters (AFR = 20 cc/min, BH = 90 cm, vacuum = 400 mmHg), and Group II: High parameters (AFR = 40 cc/min, BH = 110 cm, vacuum = 650 mmHg). **Results:** 15 eyes were analysed (8 in Group I; 7 in Group II). In all eyes, forward and backward movement of the PC was seen when going from foot position 0 to 1, or on occlusion break. Amplitude of these movements was much greater in Group II compared to Group I. There was no PC rupture in either group. In 2 of the 7 eyes in Group II, USG showed a sudden, spontaneous dispersion appearance of sono-opaque echoes in the vitreous cavity along with disappearance of the well-defined, crescentic stained space despite an intact PC. This suggests rupture of the AVF, leading to dispersion of the triamcinolone into the entire vitreous cavity. No AVF rupture was seen in Group I. **Conclusion:** We report a rarely described entity of AVF rupture with intact PC. The use of high AFR and BH may have clinically invisible detrimental consequences to the anterior vitreous face.

Key words: Anterior vitreous face, fluidic parameters, intact posterior capsule, phacoemulsification

Phacoemulsification is a very safe procedure today with predictable outcomes as a result of improved surgical techniques and technology. During cataract surgery, surgeons adopt different approaches that can be differentiated by the use of high, medium or low aspiration flow rates (AFR), bottle height (BH) as well as ultrasound energy modulations. Clinically, different surgeons use varying combinations of AFRs, vacuum and BHs and still have "successful" outcomes.

It has been reported that the use of high AFR and BH leads to higher intraocular IOP, greater IOP fluctuations and detrimental effects on the anterior segment structures.^[1-7] However, not much attention has been paid to the effects that phacoemulsification and its fluidic parameters can have on the posterior segment, specifically on the anterior vitreous.

Until very recently, little attention has been paid to the anterior vitreous face (AVF) and its role in maintaining both the anatomical and functional barriers between the anterior and posterior segments. The AVF adheres to the posterior lens capsule by the hyaloideocapsular ligament of Weiger,^[8,9] enclosing the potential Berger's space between the two. Although the role of posterior vitreous detachment has been studied extensively with relation to posterior segment pathologies, not much is reported about the role of the AVF as a functional barrier in the eye. In recent experimental trials, Kawasaki and colleagues^[10,11] have shown that the posterior

capsule and anterior hyaloid membrane together function as a unit, whose integrity can be damaged by excessive irrigation pressure or pressure fluctuations in the anterior chamber.

The purpose of this experimental study was to evaluate in real-time the effects of varying AFRs and BHs on the behavior of the AVF during phacoemulsification.

Methods

In this experimental trial, 20 phakic porcine eyes obtained from a local abattoir were stored at 4 degrees Celsius and used within 12 hours of enucleation. Prior to starting the experiment, the eye was mounted on a Matiz head. Gauze strips were wrapped around the eye to ensure stable positioning of the eye within the Matiz head. A 1 mm corneal paracentesis incision was made, followed by injection of a cohesive ophthalmic viscosurgical device (OVD), (Provisc, Alcon Laboratories, Fortworth, USA). Another 1 mm paracentesis was created, and a 23 gauge vitrector was introduced through it. The vitrector was used at a maximum available cut rate of 2500 cuts/minute

This is an open access journal, and articles are distributed under the terms of the Creative Commons Attribution-NonCommercial-ShareAlike 4.0 License, which allows others to remix, tweak, and build upon the work non-commercially, as long as appropriate credit is given and the new creations are licensed under the identical terms.

For reprints contact: reprints@medknow.com

Raghudeep Eye Hospital, Ahmedabad, Gujarat, India

Correspondence to: Dr. Vaishali Vasavada, Raghudeep Eye Hospital, Gurukul Road, Ahmedabad - 380 052, Gujarat, India. E-mail: vaishali@raghudeepeyeclinic.com

Manuscript received: 08.03.19; Revision accepted: 30.05.19

Access this article online

Website:

www.ijjo.in

DOI:

10.4103/ijjo.IJO_465_19

Quick Response Code:



Cite this article as: Vasavada V, Srivastava S, Vasavada V, Vasavada S, Vasavada AR, Sudhalkar A, et al. Impact of fluidic parameters during phacoemulsification on the anterior vitreous face behavior: Experimental study. Indian J Ophthalmol 2019;67:1634-7.

to remove as much iris tissue as possible, taking care that the zonules or anterior capsule were not damaged. This allowed clearer visualization of the lens equator and the zonules circumferentially.

Thereafter, a microincision vitreoretinal (MVR) knife was used to create a sclerotomy 1.5 mm behind the limbus, taking care not to touch the posterior capsule of the lens. A blunt spatula was introduced through the sclerotomy and into the cleavage plane between the posterior capsule and AVF, which could be identified easily due to absence of iris tissue. Once this space was identified, the spatula was advanced for 1.5 mm towards the center to further dissect out the space. Care was taken to avoid puncturing the posterior capsule or rupturing the AVF. A dispersive OVD, Viscoat (Alcon Laboratories, Fortworth, USA) was then injected through the sclerotomy by advancing the cannula into the dissected Berger's space. Injection of about 0.2 cc dispersive OVD caused widening of the space and complete separation between the AVF and the posterior capsule. Next, preservative free undiluted triamcinolone acetonide (40 mg/ml, Aurocort, Aurolab, India) was injected into the enlarged space. Triamcinolone acetonide acted as a sono-opaque marker that aided visualization of the dissected space with an ultrasound B-Scan (USG).

Subsequently, anterior capsulorhexis was performed through the paracentesis incision using microcapsulorhexis forceps, followed by cortical cleaving hydrodissection. Lens removal in all eyes was performed on the Infiniti Vision System (Alcon Laboratories, Fortworth, Texas, USA) using bimanual irrigation/aspiration (I/A) with standardized surgical parameters.

After lens removal, a 2.2 mm single plane, clear corneal incision was created temporally and cohesive OVD (Provisc, Alcon Laboratories, Fortworth, Texas, USA) was injected. The phaco tip was introduced into the anterior chamber through this incision. The phaco probe was then held steady by the surgeon. A 0.9 mm, mini-flared, Kelman tip with 45 degree bevel was used with an ultrasleeve (Alcon Laboratories, Fortworth, Texas, USA) during this study. An assistant held a 10 mega-Hertz USG B-Scan probe vertically over the cornea [Fig. 1] while the surgeon kept the foot pedal in position 1 (irrigation only). Care was taken to avoid undue pressure on the cornea during the USG B-Scan examination. Next, with the irrigation on (footpedal position 1), the aspiration line was clamped using an artery forceps to simulate complete occlusion at the phaco tip. After 5 seconds the clamp was released to simulate occlusion break surge. In each group, anterior chamber surge was induced by clamping, and then releasing the aspiration tubings for a total of 5 times during a period of 10 minutes. While doing this, realtime, intraoperative USG B-Scan was performed to image the posterior segment. The aim was to visualize the triamcinolone stained space between the posterior lens capsule and AVF.

The eyes were divided randomly into 2 groups depending on the preset vacuum, bottle height (BH) and aspiration flow rate (AFR) used during surgery. These parameters were defined as high and low parameters based on a previously published randomized, clinical trial.^[6] No ultrasound energy was used in any eye. Randomization was performed using computer generated random number tables. Following lens aspiration with bimanual I/A, a nurse in the operating room informed the

surgeon of the parameters to be chosen during surge induction.

Group I (Low parameters, 10 eyes assigned) –

AFR = 20 cc/min, Bottle Height (BH) = 90 cm,
Vacuum = 400 mmHg.

Group II (High parameters, 10 eyes assigned) –

AFR = 40 cc/min, BH = 110 cm, Vacuum = 650 mmHg.

Results

Of the 20 eyes, only 15 were included in the analysis. 2 eyes in Group I and 3 in Group II respectively had an inadvertent rupture of the AVF during dissection of the space behind the posterior lens capsule, and were excluded. In one eye (Group I), there was a peripheral extension of the anterior capsulorhexis. However, the eye was included for analysis since there was no posterior capsule rupture (PCR) during surgery.

In all the 15 eyes where the retrolental space could be dissected and stained with triamcinolone, a crescentic shape was seen, bound anteriorly by the posterior capsule, and posteriorly by the AVF [Fig. 2].

Group I

On clamping the aspiration line, there was a deepening of the anterior chamber alongwith backward movement of the crescentic space. When this clamp was released, the entire complex moved forward. This response was seen in all the 8 eyes analyzed.

Group II

7 eyes were analyzed in this group. Backward and forward movements of the crescentic space were seen with clamping and releasing of the aspiration line. However, the amplitude of these movements was much larger compared to Group I. In 2/7 eyes, after the 4th occlusion break, USG B-Scan showed sudden and spontaneous sono-opaque echoes within the vitreous cavity, alongwith disappearance of the well-defined, crescentic space [Fig. 3]. However, the posterior lens capsule was seen to be intact on USG B-Scan. Similar findings were noted in another eye after break of occlusion for the 5th time. In these 3 eyes, the surgeon confirmed presence of an intact posterior capsule on the microscope. These findings suggest rupture of the AVF barrier in the presence of an intact posterior capsule, leading to dispersion of the triamcinolone into the entire vitreous cavity.

Discussion

In this experimental study, we found forward and backward trampolining movements of the posterior capsule along with the retrolental Berger's space with every deflation and inflation of the eye. These movements could be documented real-time due to the sono-opaque nature of triamcinolone acetonide. Both groups, irrespective of the fluidic parameters used showed these backward movements when there was an occlusion break or when the surgeon moved from foot pedal position zero to 1.

However, the amplitude of these forward-backward movements increased as the preset AFR, BH and vacuum were increased. There was much more posterior bowing at the time of simulated complete occlusion break when higher vacuum and fluidic parameters were used as compared to lower parameters. Similarly, the extent of forward movement

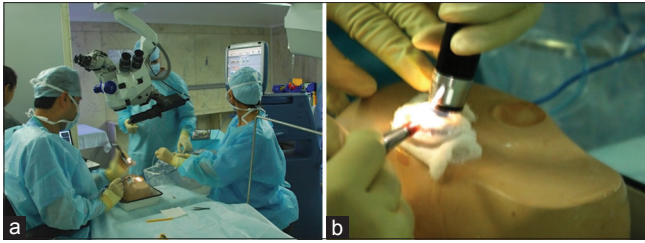


Figure 1: (a and b). Phacoemulsification being performed in porcine eye, and real-time ultrasound B scan being performed with the probe positioned over the cornea

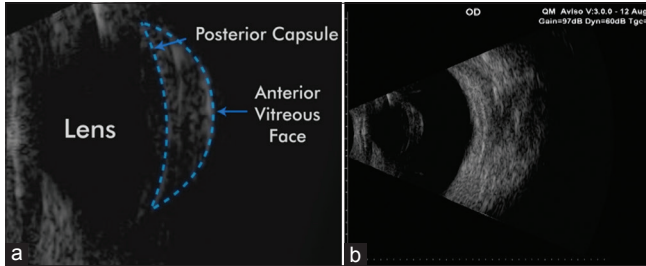


Figure 2: (a and b). Ultrasound B-Scan image showing the stained and expanded Berger's space bound on one side by the posterior capsule, and on the other, by the anterior vitreous face

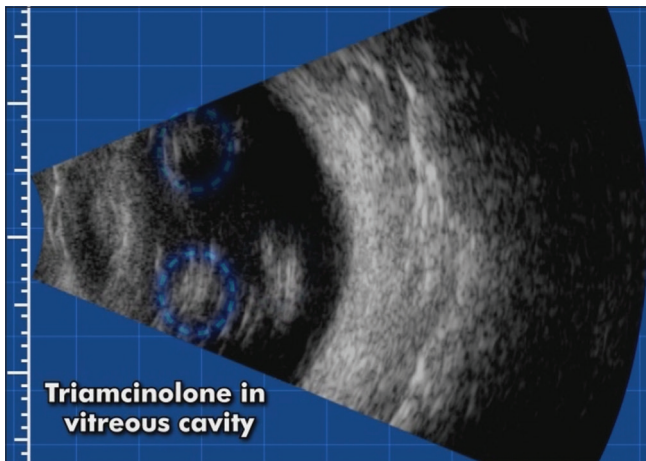


Figure 3: Sono-opaque shadows seen in the vitreous cavity, suggestive of triamcinolone dispersion in the vitreous cavity

of the entire posterior capsule-stained space was much more at simulated occlusion break with higher vacuum and BH. Further, when inducing repeated inflation/deflation with a vacuum of 600 mmHg, AFR of 40 cc/min and a BH of 110 cm, there was a rupture of the intact AVF despite an intact posterior capsule. We could document in real-time, the sudden and spontaneous appearance of sono-opaque echoes in the vitreous cavity, suggestive of AVF rupture and dispersion of triamcinolone acetonide within the posterior segment. This was seen despite an intact posterior capsule which was judged both clinically as well as in the USG B-Scan. This experimental study corroborates the existing evidence in literature^[6,7] that use of high fluidic parameters may have detrimental effects on different intraocular structures. It highlights another invisible form of damage within the eye, which has not been paid much attention to until now.

In previous experimental studies,^[10,11] Kawasaki and colleagues performed contrast-enhanced MRI as well as Miyake-Apple view analysis^[11] in porcine eyes and found that continuous elevation or abrupt fluctuations of IOP within the anterior chamber can lead to anterior hyaloid membrane detachment, or, in extreme cases, even tears within the anterior hyaloid membrane. They showed that even forceful hydrodissection can lead to extreme elevation of IOP and cause rupture of the posterior capsule and/or anterior hyaloid membrane. Based on these studies, the authors recommend that surgeons should avoid extremely high IOPs during surgery and should examine their surgical settings.

Different surgeons use different combinations of AFRs, vacuum, irrigation BH and ultrasound energy modulations. In order to reduce the total surgical time, some surgeons use higher fluidic settings. Others prefer lower settings to reduce trauma caused by the turbulence of fluid and to increase safety to the surrounding tissues.^[12] Using a high AFR necessitates using a higher BH in order to maintain anterior chamber stability. A natural consequence of using higher BH and AFR is greater intraoperative IOP as well larger IOP fluctuations during surgery.^[7] This also causes greater anterior chamber inflammation and corneal edema in the early postoperative period,^[6,7] as we reported in a previous randomized, clinical trial. Therefore, when performing phacoemulsification, surgeons should be mindful of their BH (in gravity dependent fluidics) or preset IOP (active fluidic systems) and AFR.

The current study shows in real-time that using high fluidic parameters can cause a breach in the continuity of the AVF. The clinical implications of these findings are profound. The invisible breach in the barrier between the anterior and posterior segments causes de-compartmentalization and can allow trans-zonular diffusion of infectious microbes as well as inflammatory mediators into the posterior compartment, thereby potentially increasing the risk for endophthalmitis, vitritis, macular thickening and edema. Further, disruption of the AVF barrier can cause a change in the oxygen gradient within the vitreous cavity, possibly increasing the risk of glaucoma.^[13] Whether these effects would be more pronounced in myopic eyes, or in eyes where there is pre-existing liquefaction of the vitreous is a matter of speculation.

The transparent nature of the vitreous and limitations of current diagnostic and imaging technology make it extremely difficult to examine the anatomical and functional details of the anterior vitreous both clinically as well as microscopically. Weidle^[14] described a method of visualizing the space of Berger *in vivo* by injecting an OVD to protect the anterior hyaloid face during posterior capsulotomy. We used a similar concept to delineate and visualise the Berger's space by injecting triamcinolone acetonide. Triamcinolone acetonide is sono-opaque, and also has a property to stain the vitreous.^[15-18] However, in the current study, we did not want to puncture the posterior capsule, and therefore, we tried to enter and delineate the Berger's space through the pars plana region under microscopic guidance.

Recently, with the introduction of real-time intraoperative optical coherence tomography (OCT) attached to the operating microscope^[19] as well as that attached with femtosecond laser cataract systems^[20,21] there is promise that surgeons may be able to explore better the anatomy of the anterior vitreous and Berger's space.

The limitation of this experimental technique is that the success rate in finding and staining an intact Berger's space is not hundred percent. We ruptured the AVF and could not find the Berger's space in 5 of the 20 eyes where we attempted to delineate and stain the space. Another limitation of our study is that since it was performed on porcine eyes, it may not truly mimic changes in human eyes with dynamic aqueous flow. Also, the integrity of the intraocular structures may be weakened in these enucleated eyes.

Conclusion

To summarize, this study shows for the first time, in real-time, that the anterior vitreous face can be ruptured despite an intact posterior capsule by the use of high aspiration flow rate and irrigation bottle height during phacoemulsification. This important fact needs to be kept in mind by surgeons, when choosing their surgical settings in order to minimize clinically visible as well as invisible damage to intraocular structures. However, there is still need to further understand the functional role of the anterior vitreous and the anterior vitreous face.

Financial support and sponsorship

Nil.

Conflicts of interest

There are no conflicts of interest.

References

- Moorhead LC, Armeniades CD. Variations in intraocular pressure during closed system surgical procedures. *Arch Ophthalmol* 1986;104:269-72.
- Armeniades CD, Moorhead LC. Hydrodynamic analysis of intraocular pressure changes during anterior chamber procedures. *J Cataract Refract Surg* 1992;18:444-8.
- Findl O, Strenn K, Wolzt M, Menapace R, Vass C, Eichler HG, *et al.* Effects of changes in intraocular pressure on human ocular haemodynamics. *Curr Eye Res* 1997;16:1024-9.
- Quigley HA, McKinnon SJ, Zack DJ, Pease ME, Kerrigan-Baumrind LA, Kerrigan DF, *et al.* Retrograde axonal transport of BDNF in retinal ganglion cells is blocked by acute IOP elevation in rats. *Invest Ophthalmol Vis Sci* 2000;41:3460-6.
- Moorhead LC, Gardner TW, Lambert HM, O'Malley RE, Willis AW, Meharg LS, *et al.* Dynamic intraocular pressure measurements during vitrectomy. *Arch Ophthalmol* 2005;123:1514-23.
- Vasavada AR, Praveen MR, Vasavada VA, Vasavada VA, Raj SM, Asnani PK, *et al.* Impact of high and low aspiration parameters on postoperative outcomes of phacoemulsification: Randomized, clinical trial. *J Cataract Refract Surg* 2010;36:588-93.
- Vasavada V, Raj SM, Praveen MR, Vasavada AR, Henderson BA, Asnani PK, *et al.* Real-time dynamic intraocular pressure fluctuations during microcoaxial phacoemulsification using different aspiration flow rates and their impact on early postoperative outcomes: A randomized clinical trial. *J Refract Surg* 2014;30:534-40.
- Hogan MJ, Alvarado JA, Weddell JE. Vitreous. In: Hogan MJ, Alvarado JA, Weddell JE, editors. *Histology of the Human Eye: An Atlas and Textbook*. Philadelphia: WB Saunders Co; 1971. p. 60737.
- Bron AJ, Tripathi RC, Tripathi BJ. The vitreous. In: Bron AJ, Tripathi RC, Tripathi BJ, editors. *Wolff's Anatomy of the Eye and Orbit*; CRC Press. 1998.
- Kawasaki S, Suzuki T, Yamaguchi M, Tasaka Y, Shiraishi A, Uno T, *et al.* Disruption of the posterior chamber–anterior hyaloid membrane barrier during phacoemulsification and aspiration as revealed by contrast-enhanced magnetic resonance imaging. *Arch Ophthalmol* 2009;127:465-70.
- Kawasaki S, Tasaka Y, Suzuki T, Zheng X, Shiraishi A, Uno T, *et al.* Influence of elevated intraocular pressure on the posterior chamber–anterior hyaloid membrane barrier during cataract operations. *Arch Ophthalmol* 2011;129:751-7.
- Verges C, Cazal J, Lavin C. Surgical strategies in patients with cataract and glaucoma. *Curr Opin Ophthalmol* 2005;16:44-52.
- Chang S. LXII Edward Jackson lecture: Open angle glaucoma after vitrectomy. *Am J Ophthalmol* 2006;141:1033-43.
- Weidle E. Visualization of Berger's space in the living eye. *Ophthalmic Surg* 1985;11:733-4.
- Yamakiri K, Uchino E, Kimura K, Sakamoto T. Intracameral triamcinolone helps to visualize and remove the vitreous body in anterior chamber in cataract surgery. *Am J Ophthalmol* 2004;138:650-2.
- Kasbekar S, Prasad S, Kumar BV. Clinical outcomes of triamcinolone-assisted anterior vitrectomy after phacoemulsification complicated by posterior capsule rupture. *J Cataract Refract Surg* 2013;39:414-8.
- Peyman GA, Cheema R, Conway MD, Fang T. Triamcinolone acetate as an aid to visualization of the vitreous and the posterior hyaloid during pars plana vitrectomy. *Retina* 2000;20:554-5.
- Shah SK, Vasavada V, Praveen MR, Vasavada AR, Trivedi RH, Dixit NV. Triamcinolone-assisted vitrectomy in pediatric cataract surgery. *J Cataract Refract Surg* 2009;35:230-2.
- Tassignon MJ, Dhubhghaill SN. Real-time intraoperative optical coherence tomography imaging confirms older concepts about the Berger space. *Ophthalmic Res* 2016;56:222-6.
- Dick H, Schultz T. Primary posterior laser-assisted capsulotomy. *J Refract Surg* 2014;30:128-33.
- Haeussler-Singangin Y, Schultz T, Holtmann E, Dick HB. Primary posterior capsulotomy in femtosecond laser-assisted cataract surgery: *In vivo* spectral-domain optical coherence tomography study. *J Cataract Refract Surg* 2016;9:1339-44.