

## CASE REPORT

# Fighting diagnostic confirmation bias: Cystic fibrosis, allergic bronchopulmonary aspergillus, or both?

Patricia Choi<sup>1</sup> | Laura Bauler<sup>2</sup>  | M. Myrtha Gregoire-Bottex<sup>1</sup> 

<sup>1</sup>Department of Pediatric and Adolescent Medicine, Western Michigan University Homer Stryker M.D. School of Medicine, Kalamazoo, MI, USA

<sup>2</sup>Department of Biomedical Sciences, Western Michigan University Homer Stryker M.D. School of Medicine, Kalamazoo, MI, USA

**Correspondence**

Laura Bauler, Department of Biomedical Sciences, Western Michigan University Homer Stryker M.D. School of Medicine, Kalamazoo, MI, USA.  
Email: laura.bauler@med.wmich.edu

**Present address**

Patricia Choi, Department of Internal Medicine, Spectrum Health/Michigan State University, Grand Rapids, MI, USA  
M. Myrtha Gregoire-Bottex, Department of Pediatrics, University of Miami, Miller School of Medicine, Miami, FL, USA

**Abstract**

As diagnostic algorithms for cystic fibrosis (CF) continue to evolve, education of general practitioners is essential to prevent delayed diagnosis of CF and allow prompt referral to CF centers. For patients suffering from allergic bronchopulmonary aspergillosis (ABPA), CF should be at the top of the differential diagnosis.

**KEYWORDS**

allergic bronchopulmonary aspergillosis, cystic fibrosis

## 1 | INTRODUCTION

Cystic fibrosis (CF), caused by mutations in the cystic fibrosis transmembrane conductance regulator (CFTR) gene, is the most common autosomal recessive disorder of Caucasians.<sup>1,2</sup> Today, the majority of CF cases are diagnosed with newborn screening.<sup>3</sup> Despite universal newborn screening, which was achieved in the United States in 2010, increasing numbers of patients are being diagnosed in adulthood.<sup>4</sup> With widely available advanced genetic testing and multiple classes of mutations identified, CF is now recognized as a disease with a range of severities, affecting various ages, races, and ethnicities, and is no longer limited to a pediatric disease of Caucasian race.<sup>4,5</sup> However, the widening epidemiological background of the

disease is posing new diagnostic challenges. Achieving CF diagnosis in the adult population has been notoriously difficult as symptom onset and severity can be variable.<sup>6</sup> Moreover, CF patients diagnosed as adults have more subtle symptoms and can have inconclusive sweat chloride test results, which have traditionally been the key to CF diagnosis.<sup>7</sup> This diagnostic challenge had been recognized by the US and European CF foundations, and subsequently, consensus guidelines were released in 2008 and revised in 2017.<sup>6</sup> The major update in the 2017 consensus guidelines was to lower the threshold for the intermediate sweat chloride levels to 30–59 mmol/L with < 30 mmol/L being considered normal for all ages.

Allergic bronchopulmonary aspergillosis (ABPA) is a frequent complication of CF with an incidence of 8.9% (ranging

This is an open access article under the terms of the Creative Commons Attribution-NonCommercial-NoDerivs License, which permits use and distribution in any medium, provided the original work is properly cited, the use is non-commercial and no modifications or adaptations are made.

© 2021 The Authors. *Clinical Case Reports* published by John Wiley & Sons Ltd.

from 3% to 25%).<sup>8</sup> ABPA is a less prevalent complication of asthma with an incidence ranging from 1% to 3%. ABPA results from a hypersensitivity reaction to *Aspergillus* antigens (most commonly *Aspergillus fumigatus* (AF)) causing a Th2-type inflammatory reaction and airway obstruction. Patients present with wheezing, mucus plugging, hemoptysis, and abnormal radiologic appearance including bronchiectasis. The clinical presentation and diagnosis criteria for ABPA often overlap with the clinical and radiologic features of CF pulmonary exacerbation. Here, we report a case of undiagnosed CF despite a long-term diagnosis of ABPA. This report highlights the evolving CF guidelines, and the greater need to educate general practitioners or primary care providers how to identify patients who need referral to CF centers.

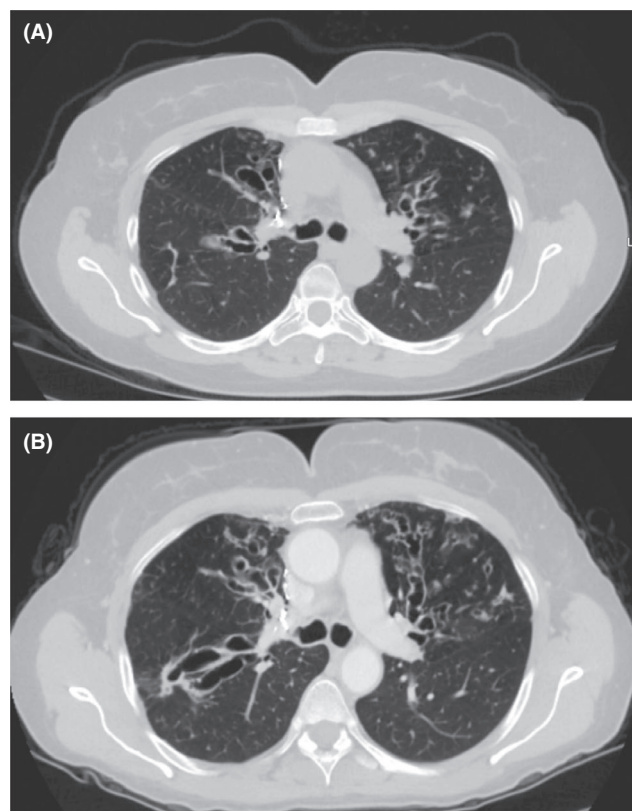
## 2 | CASE HISTORY

A 58-year-old Caucasian woman, with history of asthma, allergic bronchopulmonary aspergillosis (ABPA), and right upper lung lobectomy secondary to eosinophilic granuloma and osteopenia presented with worsening pulmonary symptoms over the preceding four years. Pertinent family history included asthma in her mother and sister. The patient denied any smoking history.

Her medical history started with childhood asthma that resolved in her late teenage years but recurred at age 35. She had undergone multiple sinus surgeries and septoplasty in the interim years. ABPA was diagnosed at the age of 54 with elevated serum IgE of 711 IU/L and *Aspergillus fumigatus* (AF) recovered from sputum. Her FEV1 was at 64% of predicted levels. She was hospitalized numerous times for *Pseudomonas* pneumonia and exacerbation of her severe bronchiectasis, each time treated with IV antibiotics (Figure 1A). She also suffered acute pancreatitis with an elevated lipase of 340 at the age of 54.

Due to worsening lung condition and pancreatitis, her primary care doctor ordered a standard 32 CFTR mutation panel. The test revealed one mutation, 394delTT(c.262\_263delTT, p.Leu88IleefsX22),<sup>9</sup> and she was diagnosed as a CF carrier. Her sweat chloride was deemed indeterminate at 40 mmol/L based on the 2008 guidelines. Unfortunately, her treatment remained focused on managing severe asthma and ABPA without further workup for CF.

Four years later, at the age of 58, the patient continued to complain of an increasingly congested cough and severe hemoptysis with significant difficulty raising secretions. She was diagnosed with severe bronchiectasis (Figure 1B) and declining lung function. Her FEV1 levels had decreased to 51% despite extensive treatment for asthma and ABPA with systemic steroids. Given her worsening lung condition, the possibility of CF was again raised and a full CFTR gene sequencing was ordered by her primary care



**FIGURE 1** A. Pre-CF diagnosis at age 52. CT chest without contrast illustrates central and varicose bronchiectasis. There are focal areas of mucoid impaction. Radiology reports indicate the image is suggestive of allergic bronchopulmonary aspergillosis. B. Post-CF diagnosis at age 57. CT chest with contrast illustrates extensive bronchiectasis throughout the lung, especially severe in the right middle lobe

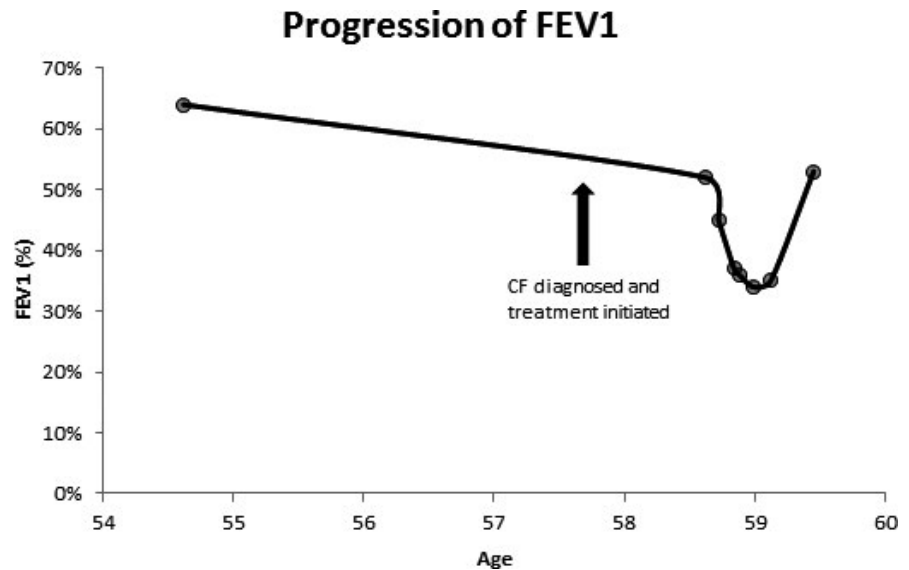
physician. The full panel revealed an additional mutation, defining her as compound heterozygous for two rare mutations: 394delTT (c.262\_263delTT, p.Leu88IleefsX22) and L967S (c.2900T > C, p.Leu967Ser).

The patient was referred to a CF center for treatment and genetic counseling. Repeat chloride testing at the CF center was 22 mmol/L. Family testing was offered to relatives. Following prescription of a proper airway clearance regimen including dornase alfa and chronic antipseudomonal treatment, her last FEV1 significantly improved from 35% to 53% (Figure 2).

## 3 | DISCUSSION

This case illustrates how an initial diagnosis of ABPA led to diagnostic confirmation bias resulting in a many-year delay to diagnose CF despite an array of symptoms pointing to CF and continued lung function decline even with full ABPA and asthma therapy. The course of this patient's CF was compounded by ABPA, a common complication of CF which is

**FIGURE 2** Graph illustrating patient's FEV1 (%) progression. The arrow points to the age the patient was diagnosed with CF and started on treatment. Even after the diagnosis was made, patient's FEV1 continued to decline as she suffered recurrent MDR *Pseudomonas pneumonia*. After recovering from her last exacerbation and the introduction of appropriate CF treatment, the patient's FEV1 improved significantly



more prevalent in adult patients. There is a significant overlap in the presentation of ABPA and CF; therefore, CF should be seriously considered in any patient with bronchiectasis or ABPA regardless of the presence of asthma.<sup>10</sup>

Our patient's clinical presentation of CF with sinus disease, bronchiectasis, recurrent pulmonary exacerbation with hemoptysis, multi-drug-resistant *Pseudomonas*, and gastrointestinal manifestations including pancreatitis should have guided the clinicians to obtain sweat chloride testing to help determine the relevance a CF diagnosis. Her first sweat chloride testing at 40 mmol/L is in fact intermediate and should have triggered a referral to an accredited CF center where an extended CFTR gene analysis or CFTR functional analysis would be considered to conclusively diagnose CF. This patient's CF therapy was also significantly delayed due to being incorrectly labeled a CF carrier with one mutation captured on the 32-mutation panel. There are over 1700 recognized mutations, and by only performing a 32-mutation panel for a symptomatic patient, full understanding of their CF diagnosis will be further delayed.<sup>11</sup> If a single CFTR variant is identified on limited analysis, then sequencing of the entire CFTR gene should be performed.<sup>12</sup>

Patients diagnosed with CF as adults often have involvement of fewer organ systems at the time of presentation. This delayed disease manifestation has been attributed to the presence of a residual function mutation combined with a more severe mutation<sup>13</sup> and genetic modifiers of the severe genotype.<sup>14</sup> Currently, the Clinical and Functional Translation of CFTR project database reports 442 variants.<sup>11</sup> Of which, 360 variants are known to be CF-causing and 11 variants are known to be of unknown significance. Our patient had 2 CFTR gene mutations. One allele 394delTT (c.262\_263delTT, p.Leu88IleefsX22) has been identified in almost 300 individuals with CF worldwide and is considered a

CF-causing variant. The second allele, L967S (c.2900T > C, p.Leu967Ser), is currently classified in the CFTR2 database as a variant of varying clinical consequence. This mutation combination resulted in sufficient CFTR function to delay serious manifestation until our patient reached her late 30s.

As the rate of individuals older than 18 years being diagnosed with CF is increasing,<sup>4</sup> the need to educate and update general practitioners must be emphasized to help guide the workup process starting with obtaining relevant history—detailed family history, under-nutrition, chronic sinus disease, and acute or chronic pancreatitis. This need was recognized by the National Institute for Health in the UK who published the National Institute for Health and Care Excellence (NICE) guidance on the diagnosis and management of CF, which encompasses children, young people, and adults and is written for general practitioners.<sup>15</sup>

Prompt diagnosis of CF will lead to early referral to CF centers and access to specialized medical care. Studies have shown that early intervention in CF management has improved outcomes.<sup>16</sup> A study from Denmark has also shown that delayed diagnosis of CF is associated with moderate-to-severe malnutrition at diagnosis.<sup>17</sup> Additionally, newly diagnosed adult CF patients who received multidisciplinary, evidence-based care at CF centers achieved significant improvement in FEV1 from the time of diagnosis.<sup>18,19</sup> Lastly, the risk factors for older age at diagnosis, diabetes, and lower lung function are predictors of reduced survival.<sup>20</sup> Thus, early diagnosis and appropriate treatment improves outcomes for CF patients.

In sum, this case shows the importance of educating general practitioners on the epidemiology of CF and evolving changes in guidelines for CF treatment and diagnosis. It is of particular importance since the CFTR corrector and modulator therapies are dramatically improving the outcomes for

most patients. Had the 2017 CF guidelines and NICE guidelines been followed, this patient could have had earlier access to specialized CF care, which could have improved her quality of life and prevented further deterioration of her lung function.

## ACKNOWLEDGEMENTS

We would like to thank Dr Duranceau for guidance on the manuscript, as well as the patient for their willingness to share her story. This case is published with written consent of the patient.

## CONFLICT OF INTEREST

None declared.

## AUTHOR CONTRIBUTIONS

PC, LB, and MG: planned the manuscript. PC: composed the first draft. PC, LB, and MG: edited the final manuscript.

## ETHICS STATEMENT

Consent was obtained from the patient prior to publishing this case.

## ORCID

Laura Bauler  <https://orcid.org/0000-0001-6508-1938>

M. Myrtha Gregoire-Bottex  <https://orcid.org/0000-0002-9984-4750>

## REFERENCES

1. Ratjen F, Döring G. Cystic fibrosis. *Lancet*. 2003;361(9358):681-689.
2. Parker-McGill K, Nugent M, Bersie R, et al. Changing incidence of cystic fibrosis in Wisconsin, USA. *Pediatr Pulmonol*. 2015;50(11):1065-1072.
3. Knapp EA, Fink AK, Goss CH, et al. The cystic fibrosis foundation patient registry: Design and methods of a national observational disease registry. *Ann Am Thorac Soc*. 2016;13(7):1173-1179.
4. Keating CL, Liu X, DiMango EA. Classic respiratory disease but atypical diagnostic testing distinguishes adult presentation of cystic fibrosis. *Chest*. 2010;137(5):1157-1163.
5. Sosnay PR, White TB, Farrell PM, et al. Diagnosis of cystic fibrosis in nonscreened populations. *J Pediatr*. 2017;181:S52-S57.e2.
6. Farrell PM, White TB, Ren CL, et al. Diagnosis of cystic fibrosis: consensus guidelines from the cystic fibrosis foundation. *J Pediatr*. 2017;181:S4-S15.e1.
7. Gilljam M, Ellis L, Corey M, Zielenski J, Durie P, Tullis DE. Clinical manifestations of cystic fibrosis among patients with diagnosis in adulthood. *Chest*. 2004;126(4):1215-1224.
8. Knutsen AP, Slavin RG. Allergic bronchopulmonary aspergillosis in asthma and cystic fibrosis. *J Immunol Res*. 2011;2011:843763.
9. Cystic Fibrosis Mutation Database. <http://genet.sickkids.on.ca/cftr/>
10. Delfino E, Del Puente F, Briano F, Sepulcri C, Giacobbe DR. Respiratory fungal diseases in adult patients with cystic fibrosis. *Clin Med Insights Circ Respir Pulm Med*. 2019;13:117954841984993.
11. Clinical and Functional Translation of CFTR (CFTR2). <https://cftr2.org>
12. Sosnay PR, Salinas DB, White TB, et al. Applying Cystic Fibrosis Transmembrane Conductance Regulator Genetics and CFTR2 Data to Facilitate Diagnoses. *J Pediatr*. 2017;181:S27-S32.e1.
13. Noone PG, Knowles MR. "CFTR-opathies": disease phenotypes associated with cystic fibrosis transmembrane regulator gene mutations. *Respir Res*. 2001;2(6):328-332.
14. Cutting GR. Modifier genes in Mendelian disorders: the example of cystic fibrosis. *Ann N Y Acad Sci*. 2010;1214(1):57-69.
15. Walshaw MJ. Cystic fibrosis: Diagnosis and management – NICE guideline 78. *Paediatr Respir Rev*. 2019;31:12-14.
16. Farrell PM, Rosenstein BJ, White TB, et al. Guidelines for Diagnosis of Cystic Fibrosis in Newborns through Older Adults: Cystic Fibrosis Foundation Consensus Report. *J Pediatr*. 2008;153(2):S4-S14.
17. Pedersen MG, Højte C, Olesen HV, Pressler T, Skov M. Late diagnosis and poor nutrition in cystic fibrosis diagnosed before implementation of newborn screening. *Acta Paediatr*. 2019;108(12):2241-2245.
18. Nick JA, Nichols DP. Diagnosis of adult patients with cystic fibrosis. *Clin Chest Med*. 2016;37(1):47-57.
19. Nick JA, Chacon CS, Brayshaw SJ, et al. Effects of Gender and Age at Diagnosis on Disease Progression in Long-term Survivors of Cystic Fibrosis. *Am J Respir Crit Care Med*. 2010;182(5):614-626.
20. Desai S, Wong H, Sykes J, Stephenson AL, Singer J, Quon BS. Clinical Characteristics and Predictors of Reduced Survival for Adult-diagnosed Cystic Fibrosis. Analysis of the Canadian CF Registry. *Ann Am Thorac Soc*. 2018;15(10):1177-1185.

**How to cite this article:** Choi P, Bauler L, Gregoire-Bottex MM. Fighting diagnostic confirmation bias: Cystic fibrosis, allergic bronchopulmonary aspergillus, or both?. *Clin Case Rep*. 2021;9:1379–1382. <https://doi.org/10.1002/ccr3.3781>