



Case Report

Efficacy of perampanel for controlling seizures and improving neurological dysfunction in a patient with dentatorubral-pallidoluysian atrophy (DRPLA)



Hideaki Shiraishi*, Kiyoshi Egawa, Tomoshiro Ito, Osamu Kawano, Naoko Asahina, Shinobu Kohsaka

Department of Pediatrics, Faculty of Medicine and Graduate School of Medicine, Hokkaido University, Sapporo, Japan

ARTICLE INFO

Article history:

Received 3 April 2017

Received in revised form 21 May 2017

Accepted 22 May 2017

Available online 26 May 2017

Keywords:

Perampanel

Dentatorubral-pallidoluysian atrophy

DRPLA

Progressive myoclonic epilepsy

Child

ABSTRACT

We administered perampanel (PER) to a bedridden 13-year-old male patient with dentatorubral-pallidoluysian atrophy (DRPLA). The DRPLA diagnosis was based on the presence of a CAG trinucleotide repeat in the *ATN1* gene. The patient experienced continuous myoclonic seizures and weekly generalized tonic-clonic seizures (GTCs). PER stopped the patient's myoclonic seizures and reduced the GTCs to fragmented clonic seizures. The patient recovered his intellectual abilities and began to walk again with assistance. We suggest that PER be considered as one of the key drugs used to treat patients with DRPLA.

© 2017 The Authors. Published by Elsevier Inc. This is an open access article under the CC BY-NC-ND license (<http://creativecommons.org/licenses/by-nc-nd/4.0/>).

1. Introduction

Dentatorubral-pallidoluysian atrophy (DRPLA) is characterized by ataxia, myoclonus, epilepsy and dementia. DRPLA is an autosomal-dominant disease that is often diagnosed during genetic counseling for children with a family history of neurological disorders. Patients with DRPLA experience progressive myoclonus epilepsy and spinocerebellar degeneration. It is caused by excessive CAG trinucleotide repeats in the *ATN1* gene, which may cause abnormal protein truncation and consequently induce apoptosis and death in neurons [1].

Perampanel (PER) was recently shown to effectively treat Lafora disease (LD), which is also characterized by progressive myoclonus epilepsy (PME) [2–4]. *EPM2A*, which encodes laforin glucan phosphatase, and *EPM2B* (*NHLRC1*), which encodes E3 ubiquitin ligase, are the major genes associated with LD. Variant in these genes cause the formation of Lafora bodies in neural cells and in the dendritic synapses of neurons [5,6]. Lafora bodies may cause apoptosis and loss of neurons in patients with LD [7]. Similarly, Igarashi et al. [1] reported that truncated DRPLA proteins, generated from truncated *ATN1* cDNAs containing extended polyglutamine stretches, were found to form filamentous peri- and intranuclear aggregates and undergo apoptosis. Therefore, since the

pathological mechanisms of DRPLA are similar to those of LD, we anticipated that PER would also be an effective treatment for patients with DRPLA. In this study, we describe the effectiveness of PER for treating a patient with DRPLA.

2. Case report

Our patient was a 13-year-old male with an intellectual disability who weighed 23 kg. He suffered daily myoclonic seizures, generalized tonic-clonic seizures (GTCs) and ataxia. He showed developmental delays in infancy. He could talk at 3 years of age and walk at 1.5 years of age. His father fell off a bridge accidentally and died at 45 years of age. He had ataxia and this might have contributed to the events causing his death. The patient's initial seizure was a GTC that occurred when he was 6 years of age while he was swimming, and he almost drowned. His electroencephalogram (EEG) showed bilateral diffuse polyspike-and-wave complexes (Fig. 1). Photic stimulation using 9-Hz, 12-Hz, 15-Hz and 18-Hz frequencies during the EEG recording showed a photoparoxysmal response and provoked seizures. This strong evidence of photosensitivity implied that the patient could suffer from epileptic syndromes including Dravet's syndrome, various types of PME and one of the genetic (idiopathic) generalized epilepsies such as juvenile myoclonic epilepsy or GTCs upon awakening [8].

The patient had been treated with multiple antiseizure drugs; carbamazepine (CBZ; maximum dose, 150 mg/day @ 6.5 mg/kg/day), valproate (VPA; maximum dose, 650 mg/day @ 28.2 mg/kg/day), lamotrigine (LTG; maximum dose, 210 mg/day @ 9.1 mg/kg/day),

* Corresponding author at: Department of Pediatrics, Faculty of Medicine and Graduate School of Medicine, Hokkaido University, North 15, West 7, Kita-ku, Sapporo 060-8638, Japan.

E-mail address: siraisi@med.hokudai.ac.jp (H. Shiraishi).

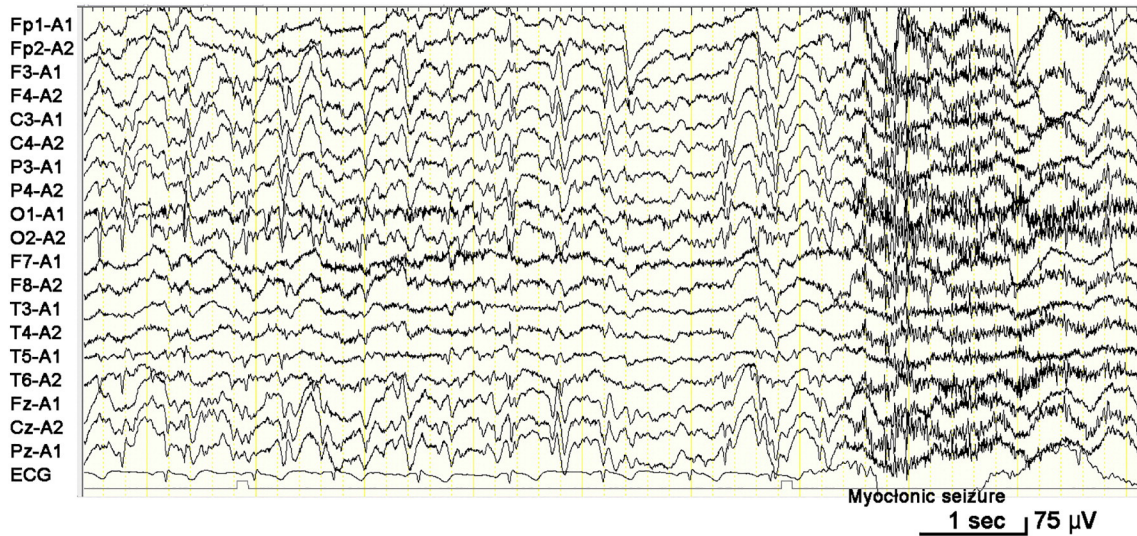


Fig. 1. EEG performed while awake at 11 years of age. The EEG showed bilateral diffuse spike-and-wave complexes and diffuse polyspike bursts followed by motion artifacts during a myoclonic seizure.

levetiracetam (LEV; maximum dose, 1500 mg/day @ 65.2 mg/kg/day), clobazam (CLB; maximum dose, 20 mg/day @ 0.87 mg/kg/day) and phenobarbital (PB; maximum dose, 120 mg/day @ 5.2 mg/kg/day). However, he continued to experience daily myoclonic seizures and weekly GTCs (Fig. 2). His intellectual and motor abilities gradually deteriorated until 9 years of age, after which he remained bedridden and never talked. He paid attention to what was outside and did not even communicate with his mother.

Gene analysis was performed at 12 years of age and showed that the CAG trinucleotide was repeated 70 times in the *ATN1* gene (normal population: 6–35 times; patients with DRPLA: 48–93 times), which suggested a diagnosis of DRPLA. A skin biopsy was not performed, since the results of the gene analysis suggested DRPLA. The patient's deceased father was supposed to have the same disease, although this cannot be confirmed as gene analysis was never performed on him. The patient's MRI scan only demonstrated non-specific findings. Based on his

clinical symptoms and the results of gene analysis we made a formal diagnosis of DRPLA.

We tried to coadminister 2 mg PER (0.09 mg/kg) with PB (120 mg/day @ 5.2 mg/kg/day), LTG (100 mg/day @ 4.3 mg/kg/day), CLB (20 mg/day @ 0.87 mg/kg/day) and VPA (600 mg/day @ 26.1 mg/kg/day) when the patient was 13 years of age (Fig. 2). The myoclonic seizures disappeared following PER administration, but the patient slept for almost the whole day. We decreased the dose of PER to 0.8 mg/day (0.035 mg/kg/day) on day 28 after the initial dose and further decreased the dose to 0.4 mg/day after 35 days, but he still could not wake up. We also decreased the dose of PB to 90 mg/day (3.9 mg/kg/day) from day 35 and then to 60 mg/day (2.6 mg/kg/day) from day 40. The patient was able to gradually wake up after day 45 and his myoclonic seizures continued to be controlled. The patient's GTCs diminished to clonic seizures of short duration, and he could stand and walk with assistance from day 85. He could also communicate

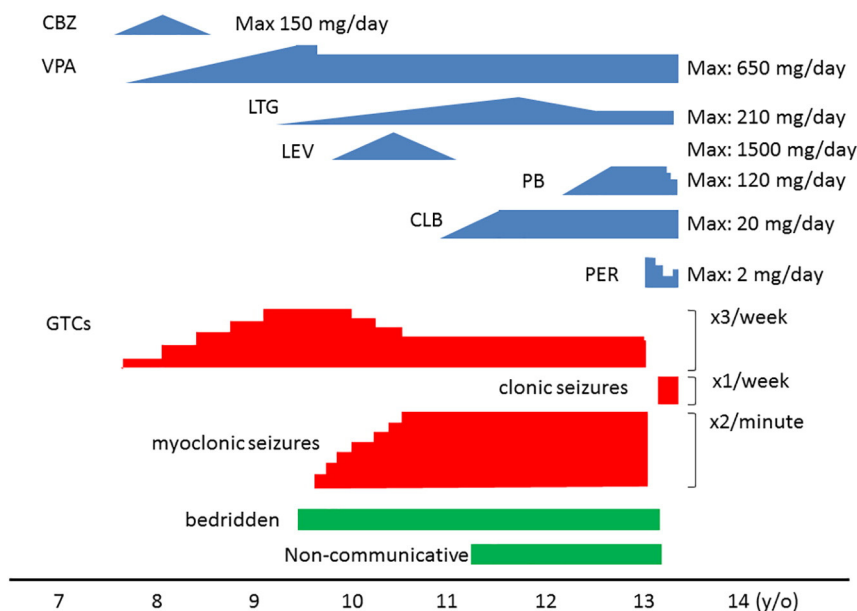


Fig. 2. Clinical course of drugs, seizures and neurological findings in our patient from 7 to 14 years of age. CBZ, carbamazepine; VPA, valproate; LTG, lamotrigine; LEV, levetiracetam; PB, phenobarbital; CLB, clobazam; PER, perampanel; GTCs, generalized tonic-clonic seizures.

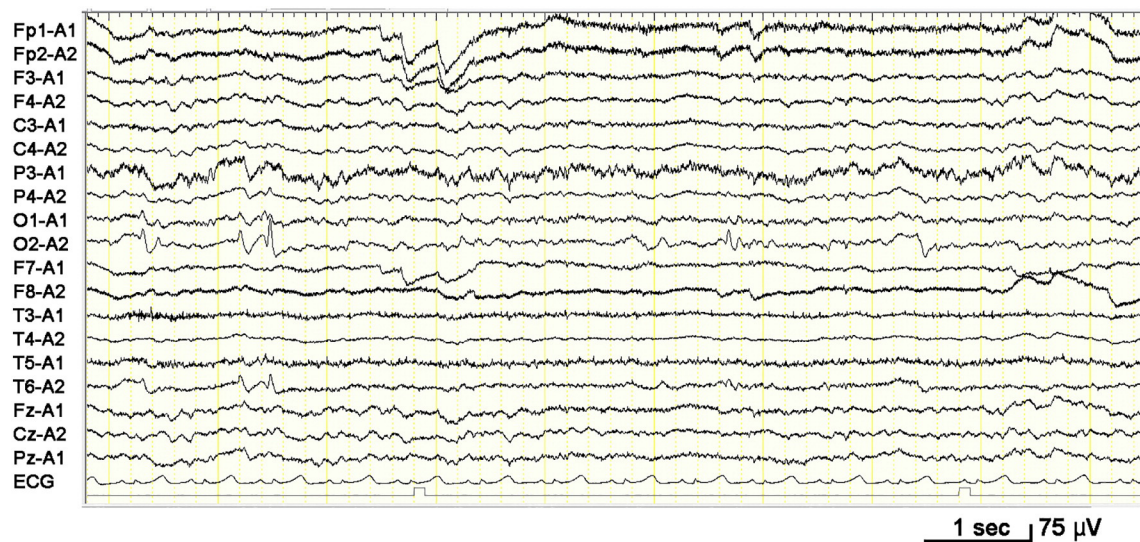

Fig. 3. EEG performed while awake at 13 years of age. The EEG showed bilaterally independent occipital spikes.

with his relatives and showed an interest in television programs. The patient's EEG on day 35 showed only bilateral occipital focal spikes (Fig. 3).

3. Discussion

DRPLA is characterized by drug-resistant myoclonic seizures, GTCs, dementia and motor disabilities. Almost all patients become bedridden and can live with assistance from a caregiver. In this study we showed that PER was an effective treatment for DRPLA. Our DRPLA patient had suffered neurological and intellectual deterioration, but recovered his abilities following PER administration.

There are 2 possibilities that could explain the improvements in our patient's condition after PER administration. First, PER stopped his habitual seizures, which interfered with his mental and motor abilities. PER has been shown to effectively treat epileptic seizures in patients with LD and Unverricht–Lundborg disease, which are both PME disorders [9], and Lance–Adams syndrome, which is characterized by the presence of cortical myoclonus after hypoxic cortical damage [10]. This is a simple explanation but we cannot explain why a very low dosage of PER also caused severe sleepiness. Second, PER is a noncompetitive α -amino-3-hydroxy-5-methyl-4-isoxazolepropionic acid (AMPA)-receptor antagonist [11]. AMPA receptors regulate the majority of glutamate-mediated synaptic excitatory systems in neurons. Therefore, it is possible that PER acts as an adjunctive agent during excitatory neurotransmission in patients with DRPLA. We speculate that the AMPA system is a major pathway involved in the pathogenesis of DRPLA and that PER could be an effective treatment for patients with DRPLA. Similarly, PER effectively improved the daily behaviors of patients with LD, possibly by ameliorating the associated neurological dysfunction in LD [2,3].

Based on our results and those of other studies [9], PER appeared to improve the seizures and overall functioning in this patient and should be considered as a potential first-line agent in the treatment of this condition. Moreover, PER might effectively alleviate intellectual deficits in patients with DRPLA and LD, indicating that PER might have a direct effect on the pathogenesis of these 2 diseases. Our results suggest that PER be considered as one of the key drugs for treating patients with DRPLA. Of course, our case report only describes the results based on the treatment of one patient so there is no clear evidence that the efficacy of PER will also apply to other cases. Further studies from other institutions are warranted.

Declaration of interest

The authors have no conflicts of interest to declare.

Financial disclosure/funding

The authors received no financial support for the research, authorship, and/or publication of this article.

Ethical publication statement

The patient consented to publication of this manuscript which includes potentially identifying information. Informed consent was obtained from the patient's caregiver.

We confirm that we have read the Journal's position on issues involved in ethical publication and affirm that this report is consistent with those guidelines.

References

- [1] Igarashi S, Koide R, Shimohata T, Yamada M, Hayashi Y, Takano H, et al. Suppression of aggregate formation and apoptosis by transglutaminase inhibitors in cells expressing truncated DRPLA protein with an expanded polyglutamine stretch. *Nat Genet* 1998;18:111–7.
- [2] Schorlemmer K, Bauer S, Belke M, Hermsen A, Klein KM, Reif PS, et al. Sustained seizure remission on perampanel in progressive myoclonic epilepsy (Lafora disease). *Epilepsy Behav Case Rep* 2013;1:118–21.
- [3] Dirani M, Nasreddine W, Abdulla F, Beydoun A. Seizure control and improvement of neurological dysfunction in Lafora disease with perampanel. *Epilepsy Behav Case Rep* 2014;2:164–6.
- [4] Goldsmith D, Minassian BA. Efficacy and tolerability of perampanel in ten patients with Lafora disease. *Epilepsy Behav* 2016;62:132–5.
- [5] Chan EM, Bulman DE, Paterson AD, Turnbull J, Andermann E, Andermann F, et al. Genetic mapping of a new Lafora progressive myoclonus epilepsy locus (EPM2B) on 6p22. *J Med Genet* 2003;40:671–5.
- [6] Minassian BA, Lee JR, Herbrick JA, Huizenga J, Soder S, Mungall AJ, et al. Variant in a gene encoding a novel protein tyrosine phosphatase cause progressive myoclonus epilepsy. *Nat Genet* 1998;20:171–4.
- [7] Turnbull J, DePaoli-Roach AA, Zhao X, Cortez MA, Pencea N, Tiberia E, et al. PTG depletion removes Lafora bodies and rescues the fatal epilepsy of Lafora disease. *PLoS Genet* 2011;7:e1002037.
- [8] Shiraishi H, Fujiwara T, Inoue Y, Yagi K. Photosensitivity in relation to epileptic syndromes: a survey from an epilepsy center in Japan. *Epilepsia* 2001;42:393–7.
- [9] Crespel A, Gelisse P, Tang NP, Genton P. Perampanel in 12 patients with Unverricht–Lundborg disease. *Epilepsia* 2017.
- [10] Steinhoff BJ, Bacher M, Kurth C, Staack AM, Kornmeier R. Add-on perampanel in Lance–Adams syndrome. *Epilepsy Behav Case Rep* 2016;6:28–9.
- [11] Hanada T. The discovery and development of perampanel for the treatment of epilepsy. *Expert Opin Drug Discov* 2014;9:449–58.