



An amino-terminal *BRAF* deletion accounting for acquired resistance to RAF/EGFR inhibition in colorectal cancer

Jack K. Tung,¹ Nastaran Neishaboori,² Sigurdis Haraldsdottir,^{3,4} and Carlos J. Suarez¹

¹Department of Pathology, Stanford University School of Medicine, Stanford, California 94305, USA;

²Adaptive Biotechnologies, Seattle, Washington 98102, USA; ³Department of Oncology, Dana-Farber Cancer

Institute, Boston, Massachusetts 02215, USA; ⁴Department of Medicine—Oncology, Stanford University School of Medicine, Stanford, California 94305, USA

Abstract Although combination therapy with RAF and EGFR inhibitors has improved the survival outcomes of patients with *BRAF*-mutated colorectal cancer (CRC), acquired resistance invariably develops. The mechanisms of acquired resistance to RAF inhibitors have been largely attributed to activating mutations in *RAS* genes, *MAP2K* mutations, and amplifications in *BRAF*, *RAS* genes, and *EGFR*. In this report, we describe a patient with *BRAF*-mutated CRC who acquired an amino-terminal *BRAF* deletion involving the Ras-binding domain (RBD) after treatment with RAF/EGFR inhibitor therapy. Amino-terminal *BRAF* deletions involving the RBD are a rare mechanism of acquired resistance to RAF inhibitors, particularly in CRC for which there is only one prior report in the literature.

Corresponding author:
cjsuarez@stanford.edu;
Sigurdis_haraldsdottir@
dfci.harvard.edu

© 2020 Tung et al. This article is distributed under the terms of the Creative Commons Attribution-NonCommercial License, which permits reuse and redistribution, except for commercial purposes, provided that the original author and source are credited.

Ontology terms: neoplasm of the gastrointestinal tract; neoplasm of the large intestine

Published by Cold Spring Harbor Laboratory Press

doi:10.1101/mcs.a005140

INTRODUCTION

Colorectal cancer (CRC) is one of the leading causes of cancer worldwide with an estimated 1.8 million new cases in 2018. Despite a greater understanding of disease mechanisms and advances in treatment options over the last several decades, some patients with CRC still have a relatively poor prognosis and show a limited response to conventional therapy. In particular, CRCs harboring *BRAF* mutations have a poor response to standard therapies and ultimately develop resistance to currently available targeted therapies.

BRAF is part of the RAF family of serine/threonine kinases and is a component of the mitogen-activated protein kinase (MAPK) signaling pathway. The *BRAF* protein has two main functional domains: a kinase domain that serves to phosphorylate and activate downstream MEK/ERK signaling and an autoinhibitory domain, where *RAS*-GTP binds, that serves to inhibit RAF kinase activity. Upstream receptor tyrosine kinase (RTK) activity ultimately leads to Ras-mediated disruption of the autoinhibitory region via recruitment of RAF dimers and phosphorylation of RAF. *BRAF* mutations are found in 7%–10% of patients with metastatic CRC and can confer a poor prognosis (Samowitz et al. 2005; Tol et al. 2009; Roth et al. 2010; Tie et al. 2011). Specifically, the V600E point mutation accounts for nearly 90% of *BRAF* mutations seen in CRC and results in a constitutively active kinase domain and subsequent MAPK activation (Cancer Genome Atlas Network 2012). The median survival of

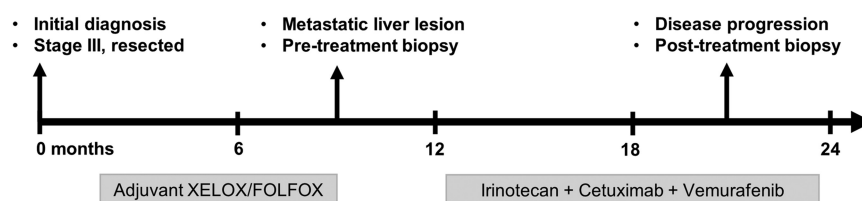


Figure 1. Timeline of events.

patients with metastatic CRC harboring $BRAF^{V600E}$ mutations is 1 yr compared to 2–3 yr in patients with wild-type $BRAF$. Non- $V600E$ $BRAF$ mutations have been associated with a more favorable prognosis in metastatic CRC, exhibiting different responses to targeted therapy depending on the functional class of the mutation (Jones et al. 2017; Yaeger et al. 2019).

$BRAF$ inhibitors such as vemurafenib and dabrafenib have been utilized as targeted therapies for $V600E$ -mutated CRC with the initial expectation that they would be as effective as they are with $BRAF^{V600E}$ -mutated melanomas. Unfortunately, vemurafenib monotherapy has produced limited response rates in patients with $V600E$ -mutant metastatic CRC (5% overall response rate compared to 50%–80% in melanoma) as a result of reactivation of EGFR and MAPK signaling (Chapman et al. 2011; Sosman et al. 2012; Corcoran 2015; Kopetz et al. 2015). Combination therapy with EGFR and $BRAF$ inhibitors has therefore been investigated and has shown improved response rates ranging from 4% to 23% in various early clinical trials (Geel et al. 2014; Hyman et al. 2015; Yaeger et al. 2015; Tabernero et al. 2016; Desai et al. 2017). Despite these promising results, patients who initially responded to therapy ultimately acquire resistance and develop disease progression. A greater understanding of the mechanisms of acquired resistance is therefore crucial to developing strategies to overcome resistance and prolong the overall survival of patients.

Although a limited number of studies have investigated the resistance mechanisms of $BRAF$ -mutated CRC, several in vitro studies have demonstrated that MAPK signaling reactivation is a common feature seen in resistant cell lines. Oddo et al. (2016) demonstrated that MAPK signaling reactivation is achieved via different mechanisms, including amplification of $EGFR$, $KRAS$, and $BRAF$ genes as well as acquired mutations in $KRAS$, $EGFR$, and $MAP2K1$. Ahronian et al. (2015) similarly identified various MAPK pathway alterations ($KRAS$ amplification, $BRAF$ amplification $MEK1$ mutations) as mechanisms of resistance in vitro and in clinical samples. Yaeger et al. (2017) also found various genetic alterations in the MAPK pathway in CRC tumor samples that had progressed on RAF and EGFR inhibitors, with RAS amplification being the most recurrent mechanism of resistance. Although other genomic alterations (e.g., $BRAF$ fusions, splice variants, internal deletions, kinase domain duplications) associated with acquired resistance to $BRAF$ inhibitors have been reported for melanomas and various other tumors (Poulikakos et al. 2011; Rizos et al. 2014; Shi et al. 2014), published reports for CRC are rare. Here, we describe a case in which a large amino-terminal deletion in $BRAF$ was detected in a patient with CRC that had acquired resistance to $BRAF$ and EGFR inhibitors (Fig. 1).

CASE PRESENTATION

The patient is a 40-yr-old woman who initially presented to the emergency department with a partial large bowel obstruction. Colonoscopy revealed an obstructing mass in the transverse colon with biopsy-proven adenocarcinoma. She underwent partial colectomy, and her pathology showed a well to moderately differentiated invasive adenocarcinoma (pT4a N1a–AJCC eighth edition) with proficient mismatch repair status. She was treated with

Table 1. Pathogenic and likely pathogenic somatic variants identified in the tumors

Gene	Chr	HGVS DNA reference	HGVS protein reference	VAF (%)	Coverage	Predicted effect
Pretreatment liver biopsy (50% tumor content); median exon coverage: 963×						
<i>BRAF</i>	7	NM_004333.4:c.1799T>A	p.(Val600Glu)	24.0	1000	Nonsynonymous SNV
<i>PIK3CA</i>	3	NM_006218.2:c.1258T>C	p.(Cys420Arg)	27.7	877	Nonsynonymous SNV
<i>TP53</i>	17	NM_000546.5:c.527G>T	p.(Cys176Phe)	32.8	922	Nonsynonymous SNV
<i>SMAD4</i>	18	NG_013013.2(NM_005359.6): c.(−129+1_−128−1)_(424+1_425−1)dup	p.(Asp142fs)	n/a	n/a	Duplication exon 2–3
<i>PTEN</i>	10	n/a	n/a	n/a	n/a	Whole gene deletion
Post-treatment abdominal wall biopsy (30% tumor content); median exon coverage: 393×						
<i>BRAF</i>	7	NM_004333.4:c.1799T>A	p.(Val600Glu)	20.0	365	Nonsynonymous SNV
<i>PIK3CA</i>	3	NM_006218.2:c.1258T>C	p.(Cys420Arg)	19.5	334	Nonsynonymous SNV
<i>TP53</i>	17	NM_000546.5:c.527G>T	p.(Cys176Phe)	29.6	449	Nonsynonymous SNV
<i>SMAD4</i>	18	NG_013013.2(NM_005359.6): c.(−129+1_−128−1)_(424+1_425−1)dup	p.(Asp142fs)	n/a	n/a	Duplication exon 2–3
<i>CUL4A</i>	13	n/a	n/a	n/a	n/a	Amplification
<i>BRAF</i>	7	NG_007873.3(NM_004333.4):c.(138+1_139−1)_(1314+1_1315−1)del	p.(Val47_Met438del)	n/a	n/a	Deletion exon 2–10

(HGVS) Human Genome Variation Society, (VAF) variant allele fraction, (SNV) single-nucleotide variant; (n/a) not available.

two cycles of capecitabine and oxaliplatin followed by eight cycles of leucovorin, fluorouracil, and oxaliplatin (switched because of poor tolerance), but CEA levels rose 7 mo later and imaging showed a new liver nodule. Then, she underwent partial hepatectomy for a 2-cm lesion consistent with metastatic adenocarcinoma by histopathology. DNA analysis of the liver lesion by a 324-gene next-generation sequencing (NGS) assay revealed *BRAF*^{V600E}, *TP53*^{C176F}, *PIK3CA*^{C420R}, *PTEN* loss, and a *SMAD4* exons 2-3 duplication (Table 1). CEA levels continued to rise over the next 2 mo and imaging revealed new peritoneal, abdominal wall, portacaval lymph node, and ovarian metastases. Patient transferred care to Stanford and was started on irinotecan and cetuximab initially in early 2018 with vemurafenib added several weeks later given the *BRAF* mutation detected in the liver specimen. The patient had rapid clinical improvement with notable shrinkage in palpable abdominal wall nodules and improvement in pain. Surveillance imaging showed a partial response until 6 mo later when enlarging abdominal wall masses were identified. Computed tomography (CT)-guided biopsy of one of the masses confirmed metastasis, and a new *BRAF* exon 2–10 deletion and *CUL4A* amplification was detected by DNA analysis using the same 324-gene NGS assay (Table 1). Irinotecan, cetuximab, and vemurafenib treatment was continued while the patient received palliative radiation therapy to the abdominal wall. Following recommendation from the molecular tumor board, cobimetinib, a MEK inhibitor, was added to her treatment 2 mo later through compassionate use. However, given disease progression, she was transitioned to hospice care soon after.

DISCUSSION

The *BRAF* exon 2–10 deletion identified in the peritoneal mass after treatment with vemurafenib involves deletion of the amino-terminal autoinhibitory region (CR1), which includes the Ras-binding domain (RBD) (Fig. 2B). Amino-terminal *BRAF* deletions are uncommon

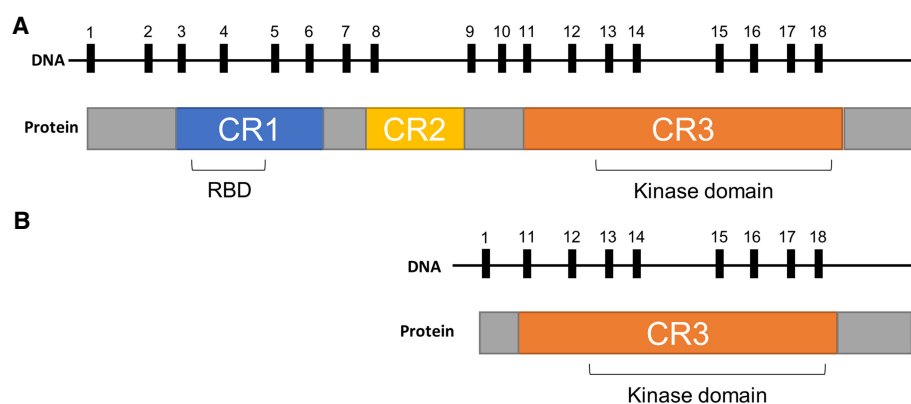


Figure 2. Schematic of wild-type *BRAF* gene (A) and *BRAF* exon 2–8 deletion (B). Exon numbers are shown above their corresponding protein products, with relevant functional domains labeled. (RBD) Ras-binding domain, (CR) conserved region.

alterations and have been mostly identified in metastatic melanoma, with fewer reports in other tumor types such as multiple myeloma, glioblastoma, and adenocarcinoma (lung, pancreas, and prostate) (Rizos et al. 2014; Johnson et al. 2018). Although there is currently no in vitro experimental evidence determining the precise effect of amino-terminal *BRAF* deletions removing the RBD, they are predicted to drive acquired resistance to BRAF inhibitors via Ras-independent constitutive dimerization and activation of the truncated *RAF*. This mechanism is predicted to be analogous to the loss of RBD by alternative splicing (Poulikakos et al. 2011) or gene fusions (Palanisamy et al. 2010; Hutchinson et al. 2013; Ross et al. 2016; Kulkarni et al. 2017), which are better studied mechanisms.

The mechanisms of resistance to RAF inhibitors in CRC have been largely attributed to mutant *BRAF* amplifications, *RAS* amplifications, *EGFR* amplifications, activating *RAS* mutations, and *MAP2K1* mutations (Oddo et al. 2016; Yaeger et al. 2017). The case presented herein provides supporting evidence that resistance to RAF inhibition can also result from amino-terminal *BRAF* deletions. To the best of our knowledge, there has only been one other previously reported amino-terminal *BRAF* deletion in CRC. Yaeger et al. reported one patient with metastatic *BRAF* mutant CRC who eventually progressed on encorafenib, cetuximab, and alpelisib (Yaeger et al. 2017). The patient had a partial response to this combination therapy (62% response by RECIST) for 24 wk before acquiring a *BRAF* exon 2–8 deletion in a peritoneal metastasis and *NRAS* mutation in a liver metastasis.

Acquired resistance to combination therapy has been long thought to result from multiple mechanisms working in concert. In one study, amino-terminal *BRAF* deletions involving the RBD have been described with concurrent *BRAF*^{V600E} mutations in the majority (90%) of melanomas, but less so (44%) with other tumor types (Johnson et al. 2018). Interestingly, in CRC, both the case described in this report and the case reported by Yaeger et al. harbored a *BRAF*^{V600E} along with the amino-terminal *BRAF* deletion. The patient also developed a *CUL4A* amplification in her post-*BRAF* inhibitor treatment specimen, which has been shown to promote proliferation and metastasis of CRC cells in vitro (Sui et al. 2017). Finally, the patient's preexisting *PTEN* loss and *PI3K* mutations may have also primed the patient for developing RAF inhibitor resistance as these alterations have been associated with resistance in preclinical models (Paraiso et al. 2011; Xing et al. 2012) and decreased response duration in patients with melanoma (Nathanson et al. 2013).

The approach to treating CRC is rapidly evolving as our understanding of resistance mechanisms to targeted therapy continues to grow. Clinical trials investigating combination

therapies targeting EGFR, RAF, and MEK are ongoing and have shown encouraging results (Hong et al. 2016; Corcoran et al. 2018; Ursem et al. 2018; Kopetz et al. 2019). With recent evidence supporting the notion that RAF dimerization may be a common feature of the mechanism of acquired resistance to RAF inhibitors in CRC (Yaeger et al. 2017), novel RAF dimer inhibitors have also been evaluated in this context and have been shown to be effective in inhibiting growth of RAF/EGFR inhibitor resistant cells in vitro (Yaeger et al. 2017; Yao et al. 2019). Although it may be safe to assume that amino-terminal *BRAF* deletions represent class II mutations that function as RAS-independent activated dimers, further characterization of this rare alteration is needed in order to guide effective targeted therapy strategies in the future.

METHODS

The specimens obtained from our patient were sequenced by the FoundationOne CDx (F1CDx) assay. An amount of 50–1000 ng of extracted DNA is subjected to whole-genome shotgun library construction and hybridization-based capture of all coding exons from 309 cancer-related genes, one promoter region, one noncoding RNA (ncRNA), and select intronic regions from 34 commonly rearranged genes, 21 of which also include the coding exons. In total, the assay detects alterations in a total of 324 genomic regions. Using the Illumina HiSeq 4000 platform, hybrid capture–selected libraries are sequenced to high uniform depth (targeting >500× median coverage with >99% of exons at coverage >100×). Sequence data is then processed using a customized analysis pipeline designed to detect all classes of genomic alterations, including base substitutions, indels, copy-number alterations (amplifications and homozygous gene deletions), and selected genomic rearrangements (e.g., gene fusions). Additionally, genomic signatures including microsatellite instability (MSI) and tumor mutational burden (TMB) are reported.

ADDITIONAL INFORMATION

Data Deposition and Access

The interpreted variants have been deposited to the Catalog of Somatic Mutations in Cancer (COSMIC) database (<https://cancer.sanger.ac.uk/cosmic>) under the identifier COSP48265. Consent could not be obtained to make the raw sequence data publicly available.

Ethics Statement

The patient information has been appropriately de-identified in accordance with regulatory requirements.

Acknowledgments

We are grateful to the patient who allowed us to participate in her care.

Author Contributions

All authors contributed to conception and design, collection and assembly of data, data analysis and interpretation, manuscript writing, and final approval of manuscript. S.H. provided the patient's information.

Competing Interest Statement

The authors have declared no competing interest.

Received January 10, 2020;
accepted in revised form
May 5, 2020.

REFERENCES

- Ahronian LG, Sennott EM, Van Allen EM, Wagle N, Kwak EL, Faris JE, Godfrey JT, Nishimura K, Lynch KD, Mermel CH, et al. 2015. Clinical acquired resistance to RAF inhibitor combinations in BRAF-mutant colorectal cancer through MAPK pathway alterations. *Cancer Discov* **5**: 358–367. doi:10.1158/2159-8290.CD-14-1518
- Cancer Genome Atlas Network. 2012. Comprehensive molecular characterization of human colon and rectal cancer. *Nature* **487**: 330–337. doi:10.1038/nature11252
- Chapman PB, Hauschild A, Robert C, Haanen JB, Ascierto P, Larkin J, Dummer R, Garbe C, Testori A, Maio M, et al. 2011. Improved survival with vemurafenib in melanoma with BRAF V600E mutation. *N Engl J Med* **364**: 2507–2516. doi:10.1056/NEJMoa1103782
- Corcoran RB. 2015. New therapeutic strategies for BRAF mutant colorectal cancers. *J Gastrointest Oncol* **6**: 650–659. doi:10.3978/j.issn.2078-6891.2015.076
- Corcoran RB, André T, Atreya CE, Schellens JHM, Yoshino T, Bendell JC, Hollebecque A, McRee AJ, Siena S, Middleton G, et al. 2018. Combined BRAF, EGFR, and MEK inhibition in patients with BRAF^{V600E}-mutant colorectal cancer. *Cancer Discov* **8**: 428–443. doi:10.1158/2159-8290.CD-17-1226
- Desai J, Markman B, Ananda S, Tebbutt NC, Michael M, Solomon BJ, McArthur GA, Tie J, Gibbs P, Ritchie D, et al. 2017. A phase I/II trial of combined BRAF and EGFR inhibition in patients (Pts) with BRAF V600E mutated (BRAFM) metastatic colorectal (MCRC): the EVICT (Erlotinib and Vemurafenib in Combination Trial) study. *J Clin Oncol* **35**: 3557. doi:10.1200/JCO.2017.35.15_suppl.3557
- Geel RV, Elez E, Bendell JC, Faris JE, Lolkema MPJK, Eskens F, Spreafico A, Kavan P, Delord J-P, Schuler MH, et al. 2014. Phase I study of the selective BRAF^{V600} inhibitor encorafenib (LGX818) combined with cetuximab and with or without the α -specific PI3K inhibitor BYL719 in patients with advanced BRAF-mutant colorectal cancer. *J Clin Oncol* **32**: 3514. doi:10.1200/jco.2014.32.15_suppl.3514
- Hong DS, Morris VK, Osta BE, Sorokin AV, Janku F, Fu S, Overman MJ, Piha-Paul S, Subbiah V, Kee B, et al. 2016. Phase IB study of vemurafenib in combination with irinotecan and cetuximab in patients with metastatic colorectal cancer with BRAF^{V600E} mutation. *Cancer Discov* **6**: 1352–1365. doi:10.1158/2159-8290.CD-16-0050
- Hutchinson KE, Lipson D, Stephens PJ, Otto G, Lehmann BD, Lyle PL, Vnencak-Jones CL, Ross JS, Pietenpol JA, Sosman JA, et al. 2013. BRAF fusions define a distinct molecular subset of melanomas with potential sensitivity to MEK inhibition. *Clin Cancer Res* **19**: 6696–6702. doi:10.1158/1078-0432.CCR-13-1746
- Hyman DM, Puzanov I, Subbiah V, Faris JE, Chau I, Blay J-Y, Wolf J, Raje NS, Diamond EL, Hollebecque A, et al. 2015. Vemurafenib in multiple nonmelanoma cancers with BRAF V600 mutations. *N Engl J Med* **373**: 726–736. doi:10.1056/NEJMoa1502309
- Johnson DB, Childress MA, Chalmers ZR, Frampton GM, Ali SM, Rubinstein SM, Fabrizio D, Ross JS, Balasubramanian S, Miller VA, et al. 2018. BRAF internal deletions and resistance to BRAF/MEK inhibitor therapy. *Pigment Cell Melanoma Res* **31**: 432–436. doi:10.1111/pcmr.12674
- Jones JC, Renfro LA, Al-Shamsi HO, Schrock AB, Rankin A, Zhang BY, Kasi PM, Voss JS, Leal AD, Sun J, et al. 2017. Non-V600 BRAF mutations define a clinically distinct molecular subtype of metastatic colorectal cancer. *J Clin Oncol* **35**: 2624–2630. doi:10.1200/JCO.2016.71.4394
- Kopetz S, Desai J, Chan E, Hecht JR, O'Dwyer PJ, Maru D, Morris V, Janku F, Dasari A, Chung W, et al. 2015. Phase II pilot study of vemurafenib in patients with metastatic BRAF-mutated colorectal cancer. *J Clin Oncol* **33**: 4032–4038. doi:10.1200/JCO.2015.63.2497
- Kopetz S, Grothey A, Yaeger R, Van Cutsem E, Desai J, Yoshino T, Wasan H, Ciardiello F, Loupakis F, Hong YS, et al. 2019. Encorafenib, binimetinib, and cetuximab in BRAF V600E-mutated colorectal cancer. *N Engl J Med* **381**: 1632–1643. doi:10.1056/NEJMoa1908075
- Kulkarni A, Al-Hraishawi H, Simhadri S, Hirshfield KM, Chen S, Pine S, Jeyamohan C, Sokol L, Ali S, Teo ML, et al. 2017. BRAF fusion as a novel mechanism of acquired resistance to vemurafenib in BRAF^{V600E} mutant melanoma. *Clin Cancer Res* **23**: 5631–5638. doi:10.1158/1078-0432.CCR-16-0758
- Nathanson KL, Martin A-M, Wubbenhorst B, Greshock J, Letrero R, D'Andrea K, O'Day S, Infante JR, Falchook GS, Arkenau H-T, et al. 2013. Tumor genetic analyses of patients with metastatic melanoma treated with the BRAF inhibitor dabrafenib (GSK2118436). *Clin Cancer Res* **19**: 4868–4878. doi:10.1158/1078-0432.CCR-13-0827
- Oddo D, Sennott EM, Barault L, Valtorta E, Arena S, Cassingena A, Filicetto G, Marzolla G, Elez E, van Geel RMJM, et al. 2016. Molecular landscape of acquired resistance to targeted therapy combinations in BRAF-mutant colorectal cancer. *Cancer Res* **76**: 4504–4515. doi:10.1158/0008-5472.CAN-16-0396
- Palanisamy N, Ateeq B, Kalyana-Sundaram S, Pflueger D, Ramnarayanan K, Shankar S, Han B, Cao Q, Cao X, Suleman K, et al. 2010. Rearrangements of the RAF kinase pathway in prostate cancer, gastric cancer and melanoma. *Nat Med* **16**: 793–798. doi:10.1038/nm.2166

- Paraiso KHT, Xiang Y, Rebecca VW, Abel EV, Ann Chen Y, Cecilia Munko A, Wood E, Fedorenko IV, Sondak VK, Anderson ARA, et al. 2011. PTEN loss confers BRAF inhibitor resistance to melanoma cells through the suppression of BIM expression. *Cancer Res* **71**: 2750–2760. doi:10.1158/0008-5472.CAN-10-2954
- Poulikakos PI, Persaud Y, Janakiraman M, Kong X, Ng C, Moriceau G, Shi H, Atefi M, Titz B, Gabay MT, et al. 2011. RAF inhibitor resistance is mediated by dimerization of aberrantly spliced BRAF(V600E). *Nature* **480**: 387–390. doi:10.1038/nature10662
- Rizos H, Menzies AM, Pupo GM, Carlino MS, Fung C, Hyman J, Haydu LE, Mijatov B, Becker TM, Boyd SC, et al. 2014. BRAF inhibitor resistance mechanisms in metastatic melanoma: spectrum and clinical impact. *Clin Cancer Res* **20**: 1965–1977. doi:10.1158/1078-0432.CCR-13-3122
- Ross JS, Wang K, Chmielecki J, Gay L, Johnson A, Chudnovsky J, Yelensky R, Lipson D, Ali SM, Elvin JA, et al. 2016. The distribution of BRAF gene fusions in solid tumors and response to targeted therapy. *Int J Cancer* **138**: 881–890. doi:10.1002/ijc.29825
- Roth AD, Tejpar S, Delorenzi M, Yan P, Fiocca R, Klingbiel D, Dietrich D, Biesmans B, Bodoky G, Barone C, et al. 2010. Prognostic role of KRAS and BRAF in stage II and III resected colon cancer: results of the translational study on the PETACC-3, EORTC 40993, SAKK 60-00 trial. *J Clin Oncol* **28**: 466–474. doi:10.1200/JCO.2009.23.3452
- Samowitz WS, Sweeney C, Herrick J, Albertsen H, Levin TR, Murtaugh MA, Wolff RK, Slattery ML. 2005. Poor survival associated with the BRAF V600E mutation in microsatellite-stable colon cancers. *Cancer Res* **65**: 6063–6069. doi:10.1158/0008-5472.CAN-05-0404
- Shi H, Hugo W, Kong X, Hong A, Koya RC, Moriceau G, Chodon T, Guo R, Johnson DB, Dahlman KB, et al. 2014. Acquired resistance and clonal evolution in melanoma during BRAF inhibitor therapy. *Cancer Discov* **4**: 80–93. doi:10.1158/2159-8290.CD-13-0642
- Sosman JA, Kim KB, Schuchter L, Gonzalez R, Pavlick AC, Weber JS, McArthur GA, Hutson TE, Moschos SJ, Flaherty KT, et al. 2012. Survival in BRAF V600-mutant advanced melanoma treated with vemurafenib. *N Engl J Med* **366**: 707–714. doi:10.1056/NEJMoa1112302
- Sui X, Zhou H, Zhu L, Wang D, Fan S, Zhao W. 2017. CUL4A promotes proliferation and metastasis of colorectal cancer cells by regulating H3K4 trimethylation in epithelial–mesenchymal transition. *OncoTargets Ther* **10**: 735–743. doi:10.2147/OTT.S118897
- Tabernero J, Van Geel R, Guren TK, Yaeger RD, Spreafico A, Faris JE, Yoshino T, Yamada Y, Kim TW, Bendell JC, et al. 2016. Phase 2 results: Encorafenib (ENCO) and Cetuximab (CETUX) with or without Alpelisib (ALP) in patients with advanced BRAF-mutant colorectal cancer (BRAFM CRC). *J Clin Oncol* **34**: 3544. doi:10.1200/JCO.2016.34.15_suppl.3544
- Tie J, Gibbs P, Lipton L, Christie M, Jorissen RN, Burgess AW, Croxford M, Jones I, Langland R, Kosmider S, et al. 2011. Optimizing targeted therapeutic development: analysis of a colorectal cancer patient population with the BRAF^{V600E} mutation. *Int J Cancer* **128**: 2075–2084. doi:10.1002/ijc.25555
- Tol J, Nagtegaal ID, Punt CJA. 2009. BRAF mutation in metastatic colorectal cancer. *N Engl J Med* **361**: 98–99. doi:10.1056/NEJMc0904160
- Ursem C, Atreya CE, Van Loon K. 2018. Emerging treatment options for BRAF-mutant colorectal cancer. *Gastrointest Cancer* **8**: 13–23. doi:10.2147/gicct.s125940
- Xing F, Persaud Y, Pratilas CA, Taylor BS, Janakiraman M, She Q-B, Gallardo H, Liu C, Merghoub T, Hefter B, et al. 2012. Concurrent loss of the PTEN and RB1 tumor suppressors attenuates RAF dependence in melanomas harboring (V600E)BRAF. *Oncogene* **31**: 446–457. doi:10.1038/onc.2011.250
- Yaeger R, Cercek A, O'Reilly EM, Reidy DL, Kemeny N, Wolinsky T, Capanu M, Gollub MJ, Rosen N, Berger MF, et al. 2015. Pilot trial of combined BRAF and EGFR inhibition in BRAF-mutant metastatic colorectal cancer patients. *Clin Cancer Res* **21**: 1313–1320. doi:10.1158/1078-0432.CCR-14-2779
- Yaeger R, Yao Z, Hyman DM, Hechtman JF, Vakiani E, Zhao HY, Su W, Wang L, Joelson A, Cercek A, et al. 2017. Mechanisms of acquired resistance to BRAF V600E inhibition in colon cancers converge on RAF dimerization and are sensitive to its inhibition. *Cancer Res* **77**: 6513–6523. doi:10.1158/0008-5472.CAN-17-0768
- Yaeger R, Kotani D, Mondaca S, Parikh AR, Bando H, Van Seventer EE, Taniguchi H, Zhao H, Thant CN, de Stanchina E, et al. 2019. Response to anti-EGFR therapy in patients with BRAF non-V600-mutant metastatic colorectal cancer. *Clin Cancer Res* **25**: 7089–7097. doi:10.1158/1078-0432.CCR-19-2004
- Yao Z, Gao Y, Su W, Yaeger R, Tao J, Na N, Zhang Y, Zhang C, Rymar A, Tao A, et al. 2019. RAF inhibitor PLX8394 selectively disrupts BRAF dimers and RAS-independent BRAF-mutant-driven signaling. *Nat Med* **25**: 284–291. doi:10.1038/s41591-018-0274-5