



Published in final edited form as:

*Am J Med Case Rep.* 2021 ; 9(3): 158–162. doi:10.12691/ajmcr-9-3-7.

## Lemierre's Syndrome with Severe Thrombocytopenia without Disseminated Intravascular Coagulation: A Case Report and Literature Review

Hira Chaudhary, Srinath Ramaswamy, Yusra Qaiser, Unaiza Zaman, Regina Miller, Samy I. McFarlane\*

Department of Medicine, SUNY-Downstate Health Sciences University, 450 Clarkson Avenue, Brooklyn, New York 11203, USA

### Abstract

Lemierre's syndrome (LS) is an uncommon clinical entity characterized by a primary oropharyngeal infection with subsequent septic thrombophlebitis. Diagnosis is made with clinical or radiographic evidence of internal jugular vein (IJV) thrombosis, along with metastatic focus such as lungs or joints. Life threatening thrombocytopenia in Lemierre's syndrome in the absence of disseminated intravascular coagulation (DIC) is rarely reported. We present a case of a 41-year-old woman with Lemierre's syndrome caused by beta-hemolytic group C streptococci and fusobacterium species manifested as worsening pharyngitis, IJV thrombosis, and complicated by severe thrombocytopenia.

### Keywords

Lemierre's syndrome; thrombocytopenia; hemophagocytic lymphohistiocytosis (HLH); immune thrombocytopenia purpura (ITP); Disseminated intravascular coagulation (DIC)

## 1. Introduction

The two most common bacteria associated with post anginal sepsis are *Fusobacterium necrophorum* and *Fusobacterium nucleatum*. They are part of normal flora in the upper respiratory tract and GI tract. About 10% of the cases are from *Bacteroides*, *Eikenella*, *Staphylococcus* and *Streptococcus* species [1]. An important contributing factor is the history of molar extraction or sore throat [1]. The virulence of *Fusobacterium* is enhanced in the presence of a concomitant infectious agent such as beta-hemolytic group C streptococci in our case which acts in synergy to debilitate host defense systems [2]. GCS is prevalent in less than 5% in adult pharyngitis patients but causes severe throat infections [1]. The hematological manifestations are mainly limited to anemia, suppurative thrombophlebitis, and metastatic septic emboli from consumptive coagulopathy [3,4]. In this case report, we provide some insight into unusual presentation of Lemierre disease that should be taken into

account when severe thrombocytopenia is seen in a patient with a history of sore throat or neck pain. We discuss the major mechanisms of severe thrombocytopenia including platelet consumption at IJV thrombosis site, sepsis induced platelet aggregation/activation, DIC, secondary hemophagocytosis, and/or secondary immune thrombocytopenic purpura.

## 2. Case Presentation

A 41-year old African American female presented with fever, sore throat, headache, dysphagia, and malaise for one week. She described the headache as left sided, stabbing, 10/10 in intensity, radiating to the front of her neck and shoulder, with associated photophobia. She endorsed progressive dysphagia to both solids and liquids over one week. Other medical problems included intermittent asthma. Family history was remarkable for leukemia in her aunt and father. She denied toxic habits and IV drug abuse. Originally from Guyana, she had migrated a few years ago to the US and endorsed recent travel to Upstate New York to visit her daughter at college. At presentation, she was afebrile, in distress due to pain, with tachycardia to 138 bpm, BP of 90/65 mm Hg, and respiratory rate of 18 per minute. IV fluids were initiated, and pain was managed appropriately. Physical exam revealed bilateral conjunctival erythema, left submandibular tenderness without palpable lymph nodes, and neck stiffness with restriction of movement. Systemic exam was unremarkable and focal neurological signs were absent.

Initial lab studies showed leukocytosis of 14000/ $\mu$ L with 5% bands, hemoglobin of 11.2 g/dL, severe thrombocytopenia 10,000/ $\mu$ L, and normal platelet morphology on peripheral smear. Her baseline platelet count was 250,000/ $\mu$ L. Elevated ferritin (797.8 ng/mL), triglyceride level 228 mg/dL, total bilirubin (1.1 mg/dL), and direct bilirubin (0.9 m/dL) were noted with normal LFTs. Prothrombin time (15.6 sec), INR (1.3), and fibrinogen level (590 mg/dL) with normal d-dimer (< 0.5 mg/L) and activated partial thromboplastin time (18.3 sec). No bleeding manifestations were observed.

IV ceftriaxone and vancomycin were initiated for clinical diagnosis of sepsis with possible bacterial meningitis, and doxycycline for coverage of anaplasmosis, due to recent travel. We could not perform a lumbar puncture given the degree of thrombocytopenia. Non-contrast CT head was unremarkable. Blood culture was positive for Group C streptococcus and *Micromonas micros* (peptostreptococcus) and *Fusobacterium sp. (nucleatum/necrophorum)*-indicative of a classic polymicrobial oral source of infection. Bacterial throat culture was negative for group C streptococcus likely due to broad spectrum antibiotic use since admission. Patient's neck pain was initially attributed to deep cervical adenitis; however, due to increasing pain and opioid requirement on day 3, a CT neck with contrast was performed, revealing thrombosis of the left internal jugular vein (LIJV) (Figure 1a). A diagnosis of Lemierre syndrome was made due to sterile site isolation of *Fusobacterium* species and GCS (blood culture) and IJV thrombosis on imaging.

On Day 4-5, improvement in platelet count (57,000/ $\mu$ L) was observed but she continued to be febrile. Per blood culture sensitivity, IV ceftriaxone was continued, and IV metronidazole was added; vancomycin and doxycycline were discontinued. A CT chest with contrast showed septic emboli to lungs (Figure 2a). Trans-thoracic echocardiogram showed no

valvular vegetations. MRI brain with MR venogram confirmed IJV thrombosis with no dural sinus involvement (Figure 1b) but showed left tonsillar enhancement suggestive of acute tonsillitis. Anticoagulation could not be initiated at this time due to persistent thrombocytopenia. Further workup at admission for other etiologies revealed negative results for HIV, Hepatitis B and C serologies, respiratory viral panel, monospot test, and rapid strep test. Peripheral smear showed no Malaria or Babesia parasites. Anaplasma phagocytophilum IgM and IgG, CMV IgM, and EBV VCA IgM serologies were negative. ADAMTS13 levels, ANA, ds-DNA, ANCA screen, MPO and proteinase-3 Ab were also negative.

By Day 7-8 of antibiotic regimen, her fever, neck pain, and platelet count (247,000/ $\mu$ L) improved significantly. Serial blood cultures were negative. At this time, a drop-in hemoglobin was noted (7.7-9 g/dL). No bleeding was observed, and coagulation parameters and lab markers of hemolysis were within normal ranges. Reticulocyte index was found to be low (0.41). Unfractionated heparin infusion was initiated for IJV thrombosis and transitioned to low molecular weight heparin at therapeutic dosing. After transient improvement, she was noted to have recurrent fever spikes on Day 8-9. Repeat blood cultures were negative and repeat CT imaging showed persistent filling defects in the IJV but with significantly reduced edema and gas shadows (Figure 1). Repeat contrast chest CT showed cavitation of prior embolic nodules (Figure 1b, Figure 2b) with marked consolidation and pleural effusions. An empirical course of IV piperacillin-tazobactam and vancomycin was then started, with rapid resolution of fever. Patient was clinically stable and received a total of 14 days of antibiotics. She was discharged home to continue full-dose anticoagulation with Eliquis and an oral antibiotic course of amoxicillin-clavulanate for 4 weeks with appropriate outpatient follow up.

### 3. Discussion

The pathophysiologic mechanisms of drastic thrombocytopenia in Lemierre's syndrome are not fully understood. While there have been cases with mild thrombocytopenia, instances of decreased platelet count to 10,000/uL from a baseline of 250,000/uL- as seen with our patient- are rare. There are a few experimental observations discussed in literature that possibly highlight the pathophysiological basis of consumption coagulopathy. Platelet aggregation in platelet rich plasma has been demonstrated by virulent strains of *F. necrophorum* [4]. Aerobic gram-negative organisms with LPS, which typically cause endotoxin-mediated sepsis, primarily depend upon a complement mediated LPS- platelet interaction which requires C3 fixation to the LPS, followed by immune adherence of platelets to fixed C3. This results in reactive lysis of platelets and platelets factor 3 (PF3) activation [5]. *Fusobacterium*, being a gram-negative anaerobe, also has a classical lipopolysaccharide endotoxin (LPS) that could promote factor XII activation in the absence of an intact complement system [2,4]. Factor XII or Hageman factor is the initiating step of the intrinsic coagulation pathway, which along with other virulence factors such as hemagglutinin contribute to septic thrombus formation [3]. The resultant platelet consumption at the site of jugular thrombosis exacerbates thrombocytopenia [3]. Furthermore, mucosal invasion of bacteria results in release of hemolysin, which reduces oxygen supply and favors growth of anaerobes by destroying erythrocytes through lysis. [8] IJV thrombophlebitis is initiated either by the direct extension of primary infection through

the parapharyngeal space or by vascular or lymphatic spread from the peritonsillar space [9]. Certain genetic polymorphisms related to coagulation cascade in Toll-Like receptor 5, tissue factor 60, and plasminogen activator inhibitor-1 gene are also known to play a role in its pathology [2].

Disseminated intravascular coagulation (DIC) is a recognized complication of Lemierre's syndrome resulting in thrombocytopenia, but in our case, the disparity between normal coagulation times and severe thrombocytopenia indicate other possible mechanisms. One of such hypotheses is acquired hemophagocytic lymphohistiocytosis (HLH) that has been reported once as an atypical cause of severe thrombocytopenia in fusobacterium Lemierre's syndrome [6]. It occurs secondary to a strong immunological response due to underlying malignancy or systemic infections [7]. The underlying pathology involves uncontrolled activity of histiocytic systems against hematological cell lines diagnosed with biopsy samples of bone marrow, spleen or lymph nodes [7]. Although our patient did not get a bone marrow biopsy and fulfill the diagnostic criteria but had 4 out of 8 clinical features. Her ferritin was more than 500 with hypertriglyceridemia. Reticulocyte index was 0.41 suggesting hypo proliferation, that could be either from sepsis induced marrow suppression or presumed hemophagocytosis. Therefore, screening for secondary HLH in the setting of non-resolving sepsis, persistent fevers, or cytopenias, with less invasive measures initially like ferritin, triglyceride levels, and molecular analysis may be a smart approach.

An alternate explanation for drop in platelets could be secondary immune thrombocytopenia purpura (ITP) triggered by beta-hemolytic group-C streptococci infection as a result of an inflammatory cascade [3]. The theory of an autoantibody mediated response is supported by the observation that the peripheral smear showed no platelet clumping or morphological abnormalities, and the fact that platelet count was affected more than the other cell lines.

#### 4. Conclusion

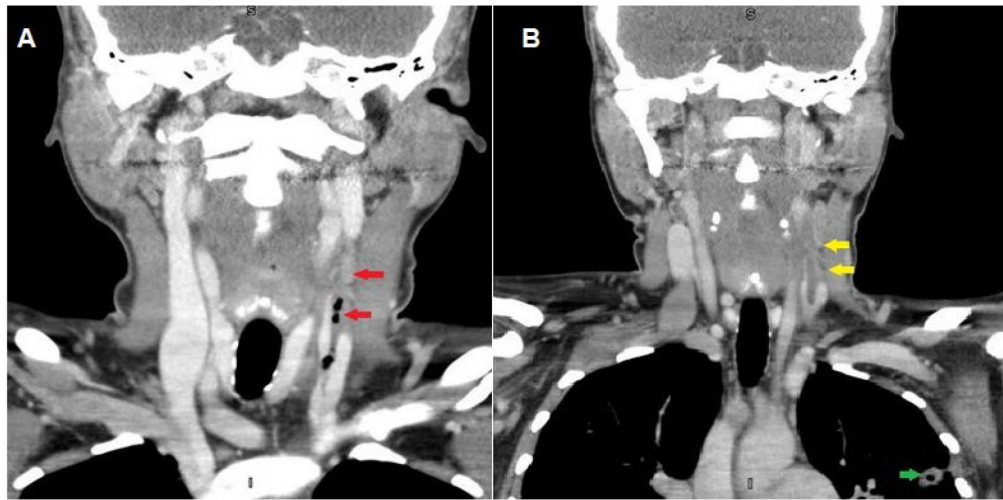
We presented an unusual case of Lemierre's disease with severe thrombocytopenia in the absence of over clinical features of DIC. The progression of thrombocytopenia during a septic episode is a significant event, with the degree of coagulation activation being related to the severity of the illness. All patients with sepsis especially secondary to bacterial infections have underlying coagulation activation and disordered clotting irrespective of the overt features of DIC. The expected mortality rate is higher in DIC. The exact mechanisms related to Lemierre's syndrome associated with severe thrombocytopenia remain unclear, but it may represent a multifactorial phenomenon involving consumptive coagulopathy, marrow suppression, hemophagocytic lymphohistiocytosis and/or secondary immune thrombocytopenia.

#### Acknowledgements

This work is supported, in part, by the efforts of Dr. Moro O. Salifu M.D., M.P.H., M.B.A., M.A.C.P., Professor and Chairman of Medicine through NIH Grant number S21MD012474.

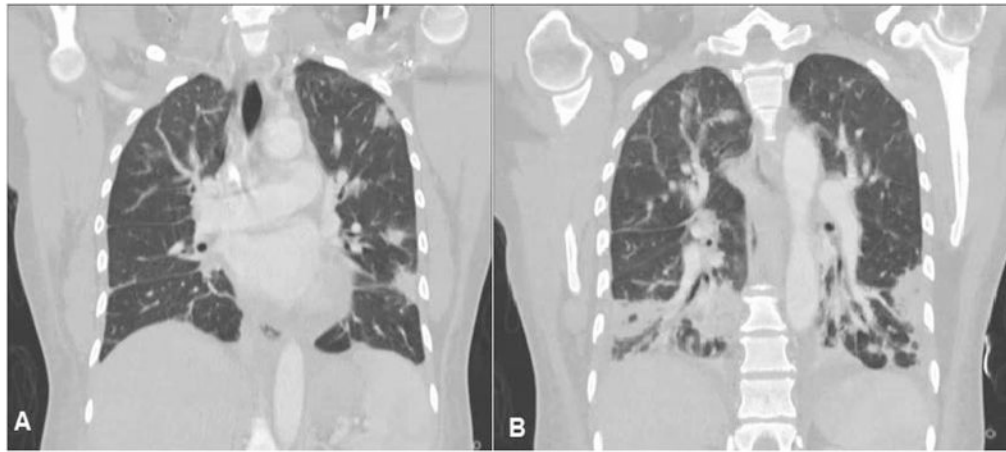
## References

- [1]. Mewawalla P, Bauer F, Dasanu C. Lemierre Syndrome Caused by Group C Streptococci and Associated with Red Cell Aplasia and Immune Thrombocytopenia. *Southern Medical Journal*. 2011; 104(3): 244–246.
- [2]. Hadjinicolaou AV, & Philippou Y (2015). Lemierre's syndrome: a neglected disease with classical features. *Case reports in medicine*, 2015.
- [3]. Forrester LJ, Campbell BJ, Berg JN, Barrett JT. Aggregation of platelets by *Fusobacterium necrophorum*. *J Clin Microbiol*. 1985; 22: 245–249. [PubMed: 4031037]
- [4]. Potter MN, Drysdale HC, Price PA, & Buck AC (1988). Disseminated intravascular coagulation with *Fusobacterium necrophorum* septicaemia. *Postgraduate medical journal*, 64(748), 155–156. [PubMed: 3174529]
- [5]. Bjornson HS, & Hill EO (1973). Bacteroidaceae in thromboembolic disease: effects of cell wall components on blood coagulation in vivo and in vitro. *Infection and immunity*, 8(6), 911–918. [PubMed: 4594118]
- [6]. Ellis GR, Gozzard DI, Looker DN, & Green GJ (1998). Postanginal septicaemia (Lemierre's disease) complicated by haemophagocytosis. *The Journal of infection*, 36(3), 340–341. [PubMed: 9661952]
- [7]. Wong KF, & Chan JK (1992). Reactive hemophagocytic syndrome—a clinicopathologic study of 40 patients in an Oriental population. *The American journal of medicine*, 93(2), 177–180. [PubMed: 1497014]
- [8]. Righini Christian A., et al. "Lemierre Syndrome: Study of 11 Cases and Literature Review." *Head & Neck*, vol. 36, no. 7, 2014, pp. 1044–1051. [PubMed: 23784917]
- [9]. Syed MI, Baring D, Addidle M, Murray C, & Adams C (2007). Lemierre syndrome: two cases and a review. *The Laryngoscope*, 117(9), 1605–1610. [PubMed: 17762792]
- [10]. Joost A, Loose S, Kramme E, Derad I. Das Lemierre-Syndrom - eine häufig übersehene Infektionserkrankung [Lemierre syndrome - a frequently overlooked infectious disease]. *Dtsch Med Wochenschr*. 2019; 144(20): 1449–1454. [PubMed: 31594022]
- [11]. Lee KJ, Kim EJ, Kang SJ, et al. Lemierre Syndrome Caused by *Arcanobacterium haemolyticum* Alone in a Healthy Man. *Chonnam Med J*. 2012; 48(3): 190–192. [PubMed: 23323228]
- [12]. Van Dijk EJ, van Swieten JC, Koudstaal PJ. Meningitis, cranial nerve palsies and bilateral cerebral infarcts: a neurological variant of Lemierre's syndrome. *J Neurol*. 2008; 255(10): 1588–1589. [PubMed: 19005628]
- [13]. Croft DP, Philippo SM, Prasad P. A case of Lemierre's syndrome with septic shock and complicated parapneumonic effusions requiring intrapleural fibrinolysis. *Respir Med Case Rep*. 2015; 16: 86–88. [PubMed: 26744664]
- [14]. Noh HJ, Freitas CA, Souza Rde P, Simões JC, Kosugi EM. Lemierre syndrome: a rare complication of pharyngotonsillitis. *Braz J Otorhinolaryngol*. 2015; 81(5): 568–570. [PubMed: 26324201]
- [15]. Zee J, Lois M, Cota D. Lemierre's Syndrome: A Case Report with Fatal CNS Complications. *Clin Med Img Lib*. 2016; 2: 048.



**Figure 1.**

a) CT soft-tissues neck with contrast demonstrating filling defect of the left internal jugular vein with gas shadows and tissue edema (red arrows). b) Repeat CT scan on Day 10 of antibiotics showing resolution of gas shadows and edema with persistent venous filling defect (yellow arrow) and cavitation of embolic nodule in the left lung (green arrow)



**Figure 2.**

a) CT chest with contrast demonstrating bilateral nodular lung opacities due to septic emboli. b) Repeat CT scan on Day 10 for recurrent fever showing bilateral consolidation, pleural effusions, and cavitation of septic emboli

Table 1.

Reports of severe thrombocytopenia (platelet count <30,000/ $\mu$ L) in Lemierre syndrome

Author	Age (years)	Sex	Blood culture	Imaging	Platelet count (per $\mu$ L)	HUS/TTP	DIC	Other hematological parameters	Management	Outcome and Comments
Joost et al. [10]	30	M	Fusobacterium necrophorum	IJV thrombosis on Ultrasound	12,000	No	No	Anemia, mild elevated LDH and bilirubin, normal haptoglobin and complement	Antibiotics, anticoagulation (UFH)	Discharged after 19 days
Lee et al. [11]	37	M	Arcanobacterium hemolyticum	L IJV thrombosis on CT angiography	22,000	No	No	Elevated total bilirubin and LDH, Hb 1.3 g/dL	Antibiotics, anticoagulation (UFH)	Discharged, no residual disease or thrombus on imaging after 4 weeks of antibiotics
Van Dijk et al. [12]	17	M	Fusobacterium necrophorum (blood and CSF cultures)	No IJV thrombosis, MRI- L internal carotid artery (ICA) occlusion, bilateral white matter lesions, sigmoid sinus opacification, contrast enhancement of the cavernous sinus	3,000	NA	NA	NA, "consumptive thrombocytopenia" but parameters not available	Antibiotics, Aspirin, bilateral antral wash-outs and opening of ethmoid and sphenoid sinuses	Outcome- NA. L ICA thrombosis and R ICA stenosis on 9-month follow up.
Croft et al. [13]	26	M	Fusobacterium necrophorum	CT angiography- R IJV thrombosis	7,000	NA	NA	NA	Antibiotics, intrathoracic t-PA for parapneumonic pleural effusions, NO anticoagulation	Discharged after 33-day hospitalization
Noh et al. [14]	18	M	Negative (clinical diagnosis)	Ultrasound- L IJV thrombosis, Embolic lung nodules on CT.	26,000	NA	NA	NA	Antibiotics, NO anticoagulation	Discharged after 14 days. Clinical diagnosis in view of ENT infection, sepsis, IJV thrombosis, lung emboli.
Zee et al. [15]	30	F	Negative (clinical diagnosis)	CT- L IJV thrombophlebitis, embolic lung nodules	20,000	NA	NA	Elevated total bilirubin and aspartate aminotransferase	Antibiotics, No anticoagulation, incision and drainage of pharyngeal space	Clinical diagnosis in view of ENT infection, sepsis, IJV thrombosis, lung emboli.

NA- data not available, M- male, F- female, IJV- internal jugular vein, UFH- unfractionated heparin, LMWH- low molecular weight heparin.