

Radiologic predictor of intraoperative lateral wall fractures in treatment of pertrochanteric fractures with cephalomedullary nailing

Jun-qi Dai¹, Dongxu Jin², Changqing Zhang^{2,*}
and Yi-Gang Huang^{2,*} 

Abstract

Objective: This study was performed to investigate the reliability of the height of pertrochanteric fractures as a predictor of lateral wall fractures after cephalomedullary nailing and provide a simple way to determine the threshold value.

Methods: We performed a prospective randomized clinical study of 50 consecutive patients who underwent measurement of the height of the pertrochanteric fracture and the tangent line to the superior margin of the contralateral femoral neck. The preoperative and postoperative integrity of the lateral wall was evaluated by computed tomography.

Results: The pertrochanteric fracture height was significantly lower in patients with than without intraoperative lateral wall fractures (15.6 vs. 28.5 mm, respectively). The threshold value of the fracture height was 20.445 mm, which was not significantly different from the mean height of the tangent line of the superior margin of the contralateral femoral neck (19.4 mm).

Conclusions: Pertrochanteric fractures with the proximal starting point lower than the mirror position of the tangent line to the superior margin of the contralateral femoral neck have a higher risk of intraoperative lateral wall fractures during cephalomedullary nailing.

¹Department of Orthopedics, Taixing People's Hospital, Taizhou, Jiangsu, China

²Department of Orthopaedic Surgery, Shanghai Jiao Tong University Affiliated Sixth People's Hospital, Shanghai, China

*These authors contributed equally to this work.

Corresponding author:

Yi-Gang Huang, Department of Orthopaedic Surgery, Shanghai Jiao Tong University Affiliated Sixth People's Hospital, 600 Yishan Road, Shanghai 200233, China.
Email: huangyigang@126.com



Keywords

Pertrochanteric fractures, lateral wall, cephalomedullary nail, radiologic predictor, fracture height, computed tomography

Date received: 5 December 2019; accepted: 17 March 2020

Introduction

Pertrochanteric fractures are one of the most common types of fracture, especially in the growing population of older people with osteoporosis. Surgical treatments are usually considered the most effective ways to restore the patient's prefracture activity and decrease the mortality rate. Although various surgical techniques have been employed, early fixation failure still occurs and may adversely affect the prognosis of these patients. Several factors are reportedly involved in the breakdown of pertrochanteric fractures, including fracture instability, poor bone quality, and inappropriate treatments.¹⁻³ Intraoperative lateral wall fractures are strongly associated with higher rates of prolonged union and reoperation in fractures treated with dynamic hip screws (DHS).⁴⁻⁹ An intact lateral femoral wall prevents excessive collapse and provides rotational stability of the fracture. If iatrogenic lateral wall fractures occur, a simple pertrochanteric fracture can be converted into an unstable reverse one, possibly resulting in malunion or nonunion.¹⁰

Cephalomedullary nails (CMNs) have recently become the most popular internal fixation devices for the treatment of pertrochanteric fractures, especially unstable fractures.^{11,12} The popularity of CMNs derives from the belief that these intramedullary implants are less invasive and may provide more biomechanical stability than DHS.¹³⁻¹⁶ Furthermore, CMNs are believed to be more appropriate for pertrochanteric fractures that are accompanied by lateral wall fractures because the proximal end of the nails may act as the lateral wall to buttress the proximal fragments.^{13,17,18} However, several mechanical instability-

related failures may occur following CMN fixation of pertrochanteric fractures with lateral wall fractures.¹⁸⁻²¹ Gao et al.¹⁷ reported a 4.69% failure rate of using CMNs in the treatment of this type of fracture, although this rate is significantly lower than that of fractures treated with DHS. In another series, screw cut-out was observed in 7.8% of the patients treated with CMNs without lateral wall reconstruction.¹⁸ When the load is forced to the femoral head, an intact lateral wall can offer the lateral point of three force-bearing points for the lag screw and provide compressive resistance to the lateral side of the lag screw. In comminuted fractures, the lag screw merely anchors the nail to the proximal fragment, and the excessive load may result in implant failure. One retrospective study showed that the incidence of iatrogenic fracture after cephalomedullary nailing was similar to that after fixation by DHS.²² Therefore, precise preoperative prediction will help surgeons to be cautious of the risk of lateral wall fracture during cephalomedullary nailing. Although previous studies have focused on preoperative predictors of lateral wall fractures during fixation with DHS, none have done so for fixation with CMNs.²³⁻²⁶

Lower pertrochanteric fractures reportedly have a higher risk of lateral wall fractures when using DHS because the proximal end of the fracture line is near the lag screw insertion site.^{24,27} In this study, we investigated the reliability of the height of pertrochanteric fractures as a predictor of intraoperative lateral wall fractures after cephalomedullary nailing and provide a simple way to determine the threshold value. We hypothesized that patients with lower fractures have a higher

risk of intraoperative lateral wall fractures and that the height of the tangent line to the contralateral superior femoral neck may be relative to the threshold value. These findings may help surgeons to prevent intraoperative lateral wall fractures and provide proper postoperative rehabilitation.

Materials and methods

Patients and methods

This prospective randomized clinical study involved consecutive patients admitted to our trauma center for surgical treatment of pertrochanteric fractures from August 2014 to February 2015. All patients were preoperatively evaluated with plain radiographs and computed tomography (CT) scans. Only fractures starting from the lateral femoral cortex proximal to the vastus ridge were included in the study (AO/OTA 31-A1 or A2). The exclusion criteria were type A3 fractures, pathologic fractures, previous fractures at the proximal femur, multiple fractures, periprosthetic fractures, and preoperative fractures of the lateral wall. All patients underwent closed reduction and internal fixation using the third-generation Gamma nail (Gamma3; Stryker, Kalamazoo, MI, USA) or INTERTAN nail (Smith & Nephew, London, UK). The choice of implant mainly depended on the patient's general status; Gamma3 nails were used for patients with an American Society of Anesthesiologists score of 3 or 4 to decrease the blood loss volume and operating time. This study was approved by the Ethics Committee of Shanghai Jiao Tong University Affiliated Sixth People's Hospital. Informed consent was obtained from all patients.

Surgical procedures

All surgeries were performed by two senior orthopedic surgeons who were experienced in the cephalomedullary nailing technique. The fractures were treated by closed reduction with continuous traction under fluoroscopic control. Both types of CMNs were introduced with similar techniques based on the standard protocol. Briefly, a guide needle was inserted into the marrow cavity of the femur through the apex of the greater trochanter, and the proximal part was reamed. The nail was then driven into the bone and checked fluoroscopically in both planes. When using the Gamma3 nail, a guidewire was introduced into the center of the head/neck fragment, and the lag screw was advanced close to the subchondral bone without penetration. When using the INTERTAN nail, an anti-rotation rod was advanced with a guidewire, and a lag screw of appropriate length was inserted. A compression screw was then screwed closely beneath the lag screw. The distal interlocked screw was routinely inserted through the drill guide. Only short nails were used in this series.

Postoperative treatment

Pain control and venous thromboembolism prophylaxis were routinely used. Patients were encouraged to bear partial weight as early as possible. On the first postoperative day, each patient underwent an X-ray examination and CT scan to determine the integrity of the lateral wall.

Radiological evaluation

An intraoperative lateral wall fracture was defined as the presence of new fracture lines or bone defects occurring at the lag screw insertion site or lateral displacement of a fracture fragment on the postoperative CT image.²⁷ The vastus ridge is the watershed of cortical and cancellous bone. To evaluate the height of the fractures, we marked the

point at which the fracture line started from the lateral cortex and then measured the distance from this point to the vastus ridge on a plain pelvic radiograph (Figure 1(a)). We referred to the CT images to determine the starting point at which the fracture line was not well seen on plain radiographs, especially in patients with displaced greater trochanters. On the contralateral side, we measured the height of the tangent line along the superior margin of the femoral neck. For this measurement, we drew a tangent line to the curve of the tensile trabeculae along the superior margin of the femoral neck, and we then measured the distance from the point at which the tangent line met the lateral cortex of the proximal femur to the vastus ridge (Figure 1(b)). The tip-apex distance (TAD) was also measured according to the method described by Baumgaertner et al.²⁸ Two well-trained surgeons who were blinded to the research protocol performed

all measurements independently. The mean values of both observers' measurements were calculated for the statistical analyses.

Statistical analysis

Statistical analysis was performed using SPSS version 11.5 (SPSS Inc., Chicago, IL, USA). Student's t-test was used for interval data (age, the height of the fracture (H1), the height of the tangent line (H2) and TAD). The chi-square test was used for categorical data (sex, side injured, fracture classification, and rate of lateral wall fracture). Receiver operating characteristic curves were used to determine the cut-off value for the fracture height. Findings were considered statistically significant if the P-value was <0.05 (two-sided).

Results

Fifty consecutive patients with pertrochanteric fractures were included in this study

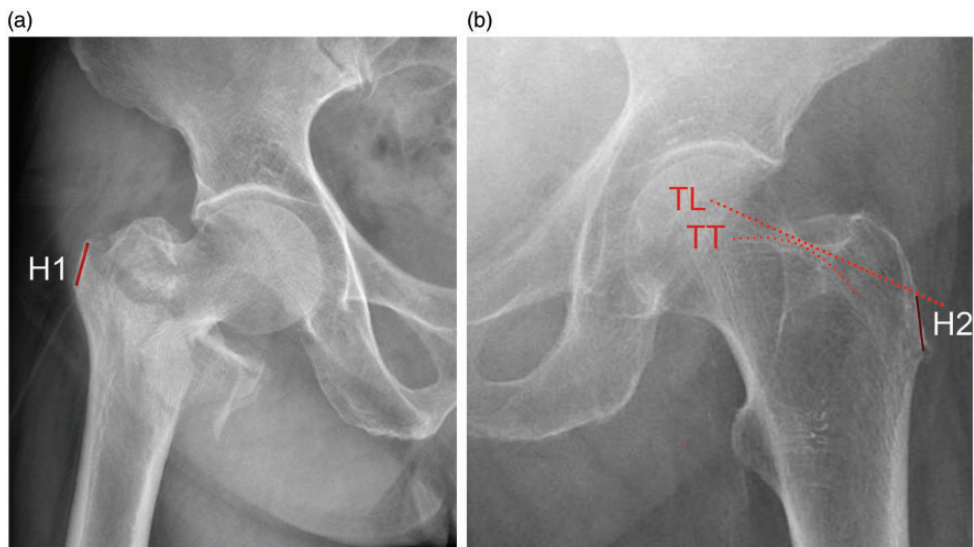


Figure 1. (a) The height of the fracture (H1) was defined as the distance from the point at which the fracture line started at the lateral cortex of the proximal femur to the vastus ridge. (b) On the contralateral side, we drew a tangent line (TL) to the curve of the tensile trabeculae (TT) along the superior margin of the femoral neck. The height of the tangent line (H2) was measured from the point at which the tangent line crossed the lateral cortex of the proximal femur to the vastus ridge.

(A1, n = 20; A2, n = 30). The patients comprised 17 men and 33 women with a mean age of 74.9 years (range, 47 to 94 years). All patients underwent an operation within 7 days (range, 2 to 7 days; mean, 2.9 days) after injury. The detailed data of all patients according to the postoperative integrity of the lateral wall are summarized in Table 1. Intraoperative fractures of the lateral wall occurred in 17 patients (34%). The patients' variables (age, sex, and fracture side) had no relationship with the development of intraoperative lateral wall fractures. The mean pertrochanteric fracture height was significantly lower in patients with than without intraoperative lateral wall fractures (15.6 vs. 28.5 mm, respectively; $P=0.00000004$). The incidence of intraoperative lateral wall fractures was significantly higher in A2 fractures (14 of 30) than in A1 fractures (3 of 20) ($\chi^2=5.36$, $P=0.021$). The mean height of A1 fractures was 29.4 mm (range, 13.2 to 42.7 mm), which was significantly higher than the

mean height of A2 fractures (20.5 mm; range, 0.0 to 39.4 mm) ($P=0.0003$).

Further stratification of the data revealed that the pertrochanteric fracture height still significantly contributed to lateral wall fractures in both A1 ($P=0.004$) and A2 fractures ($P=0.0001$) (Figure 2). For A1 fractures, the mean pertrochanteric fracture height in patients with intraoperative lateral wall fractures was 19.1 mm (range, 13.2 to 24.5 mm), which was significantly lower than that in patients without intraoperative lateral wall fractures (mean, 31.2 mm; range, 22.5 to 42.7 mm). Similarly, for A2 fractures, the mean pertrochanteric fracture height in 14 patients with intraoperative lateral wall fractures was 14.9 mm (range, 0.0 to 25.5 mm), which was also significantly lower than that in patients without intraoperative lateral wall fractures (25.5 mm; range, 12.8 to 39.4 mm) (Figure 2). We used a receiver operating characteristic curve to estimate the threshold value of the pertrochanteric

Table 1. Comparison of patients with and without lateral wall fracture after fixation of intertrochanteric fracture by cephalomedullary nailing.

	Total	Fractured lateral wall	Intact lateral wall	P-value
Patients	50	17	33	
Age, years	74.9 (47–94)	77.0 (54–92)	73.8 (47–94)	0.402
Sex				0.080
Male	17	3	14	
Female	33	14	19	
Fracture side				0.777
Left	31	11	20	
Right	19	6	13	
Fracture height, mm	24.1 (0.0–42.7)	15.6 (0.0–25.5)	28.5 (12.8–42.7)	0.00000004**
AO/OTA classification				0.021*
31-A1	20	3	17	
31-A2	30	14	16	
Tip–apex distance, mm	19.1 (9.5–35.1)	16.8 (11.3–22.7)	20.2 (9.5–35.1)	0.024*
Implant				0.369
INTERTAN	31	12	19	
Gamma3	19	5	14	

Data are presented as n or mean (range).

* $P < 0.05$

** $P < 0.01$

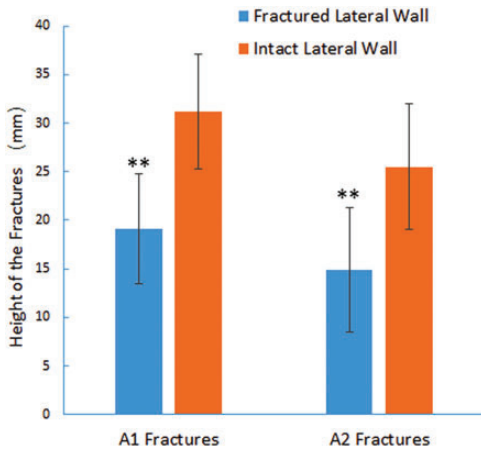


Figure 2. In both the A1 and A2 subgroups, the pertrochanteric fracture height was lower in patients with than without lateral wall fractures. *** $P < 0.01$.

fracture height that could predict intraoperative lateral wall fractures. When the value was set at 20.445 mm, the sensitivity was 90.9% and specificity was 88.2% (Figure 3). The area under the curve was 0.925, which was statistically significant ($P < 0.0001$).

The height of the superior margin's tangent line of the femoral neck was 19.4 ± 3.16 mm (range, 13.2–25.7 mm), which was not significantly different from the above-mentioned threshold value of 20.445 mm that could predict intraoperative lateral wall fractures (one-sample t-test).

The mean TAD of the patients with lateral wall fractures was 16.8 mm (range, 11.3 to 22.7 mm), which was shorter than that of patients without lateral wall fractures (20.2 mm; range, 9.5 to 35.1 mm) ($P = 0.024$). There was no significant difference in the incidence of intraoperative lateral wall fractures between the patients treated with the INTERTAN nail (12 of 31, 38.7%) and those treated with the Gamma3 nail (5 of 19, 26.3%) (Table 1).

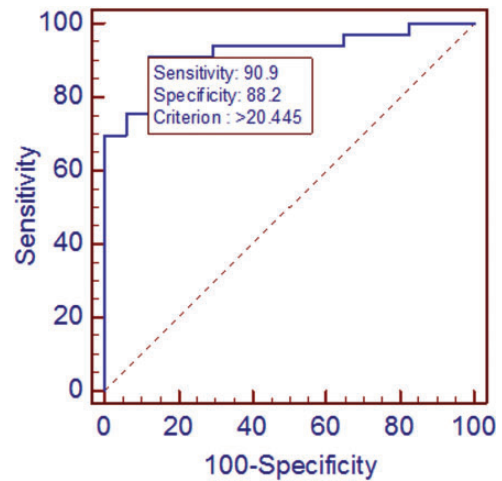


Figure 3. Receiver operating characteristic curve showing the sensitivity against 100 – specificity. When the fracture height was set at a value of 20.445 mm, the sensitivity was 90.9% and specificity was 88.2%. The area under the curve was 0.925, which was statistically significant.

Discussion

In this study, we found that the height of the fracture line in type A1 and A2 pertrochanteric fractures may predict the occurrence of intraoperative lateral wall fractures after cephalomedullary nailing. In lower fractures, there is a decreased volume of lateral walls with only a narrow cortical bridge left for insertion of the lag screws; as a result, the risk of intraoperative lateral wall fractures is higher. Previous studies have revealed that lateral wall fractures occur more frequently in unstable fractures than in simple fractures when using DHS.^{6,26,29} Hsu et al.²⁶ considered that these results were caused by the thinner lateral wall and comminution of the posteromedial fragment in the presence of unstable fractures. Our results showed that the incidence of iatrogenic fractures was also significantly higher in A2 than A1 fractures (46.7% vs. 15.0%, respectively) when using CMNs. This is consistent with a previous

retrospective study in which the A2 fractures accounted for 72% of the patients with intraoperative lateral wall fractures after fixation by CMNs.²² The reason is that A2 fractures usually have a lower fracture line, which is generally accompanied by a thinner lateral wall and smaller circumference. Therefore, less cortical bone stock is left for insertion of a lag screw through the lateral wall than in A1 fractures.

A recent CT-based study concluded that a height of <16.8 mm is associated with a higher incidence of intraoperative lateral wall fractures in patients with AO/OTA A2 pertrochanteric fractures treated with DHS.²⁷ We demonstrated that the threshold height of 20.445 mm is a reliable predictor of iatrogenic lateral wall fractures when using CMNs. When the height is less than this value, surgeons must be aware of the higher risk of iatrogenic lateral wall fractures and pay more attention to surgical procedures and implants that can help to avoid such fractures.

Although we identified a precise height of the fracture line with which to predict intraoperative lateral wall fractures, it is still inconvenient to perform radiographic measurements for all patients. Furthermore, the size and shape of the femur may influence this value. A simple method is essential to determine the location of the threshold height on proximal femurs. We measured the height of the tangent line of the contralateral superior femoral neck with a mean length of 19.4 mm, which was not significantly different from the threshold mentioned above (20.445 mm). Thus, we believe that the height of the tangent line may indicate the threshold value of the height of the fracture, and the point at which the tangent line extends to the proximal lateral femoral cortex is the corresponding position of the threshold value of 20.445 mm. This finding means that surgeons can use the height of the tangent to the superior femoral neck to

predict the occurrence of intraoperative lateral wall fractures. The risk of iatrogenic fractures is higher when the starting point of the fractures is lower than the mirrored point where the tangent line meets on the contralateral lateral femur.

Boopalan et al.²² found no significant difference in the TAD between the two groups. In the present study, however, we found that the mean TAD was significantly shorter in patients with than without lateral wall fractures. Because the TAD is usually considered one of the strongest predictors of cut-out failure after cephalomedullary nailing of pertrochanteric fractures, we believe that this result may be attributed to surgeons' repetitive pursuit to attain the best TAD, thus ignoring the screw entrance point.³⁰ An excessive posterolateral starting entry for reaming and lag screw insertion may increase the risk of lateral wall fractures. Surgeons should maintain a careful balance between the TAD and the potential occurrence of lateral wall fractures.

Caiaffa et al.^{31,32} recently confirmed that pertrochanteric fractures can be treated successfully using CMNs without distal interlocking screws. For patients with a very wide medullary cavity or an unstable four-part fracture, however, distal interlocking screws may increase the biomechanical stability, especially the failure rotational load.³³ Furthermore, the interlocking screw may decrease the impact of nail impingement with the cortical bone in patients with a large femoral anterior bow, which might lead to delayed union or cut-out.^{34,35} To ensure uniformity of the surgical treatment in this study, we routinely performed distal locking for all patients.

This study had several limitations. First, we did not report the final radiological and functional outcomes of the fractures. The purpose of this study was to identify a precise predictor of lateral wall fractures during cephalomedullary nailing. Although

previous studies identified no adverse effect on healing by lateral wall fractures, a well-designed randomized controlled trial is necessary to further clarify the impact of this type of iatrogenic fracture on the outcomes of CMN fixation for pertrochanteric fractures.²² Second, the selection of CMNs with two different designs may have introduced bias. The INTERTAN nail has a larger dimension that might have increased the risk of iatrogenic fracture.²³ In this study, the demographic and clinic characteristics were similar between the patients who underwent fixation with the two types of CMNs. We found no significant benefit of one system over another. The characteristics of the fractures may have the greatest influence on the risk of intraoperative lateral wall fractures.

Conclusions

The height of the pertrochanteric fracture is a reliable predictor of the occurrence of intraoperative lateral wall fractures during cephalomedullary nailing. Surgeons can use the height of the tangent line to the contralateral superior femoral neck as the threshold value, and fractures with a lower height than this threshold may have a higher risk of intraoperative lateral wall fractures.

Declaration of conflicting interest

The authors declare that there is no conflict of interest.

Ethics and consent statement

All participants provided written informed consent to participate in this study.

Funding

This research received no specific grant from any funding agency in the public, commercial, or not-for-profit sectors.

ORCID iD

Yi-Gang Huang  <https://orcid.org/0000-0001-7571-4858>

References

1. Kregor PJ, Obrebsky WT, Kreder HJ, et al. Unstable pertrochanteric femoral fractures. *J Orthop Trauma* 2005; 19: 63–66.
2. Laohapoonrungrsee A, Arpornchayanon O and Phornputkul C. Two-hole side-plate DHS in the treatment of intertrochanteric fracture: results and complications. *Injury* 2005; 36: 1355–1360. DOI: 10.1016/j.injury.2005.04.014.
3. Hsu CJ, Chou WY, Chiou CP, et al. Hemiarthroplasty with supplemental fixation of greater trochanter to treat failed hip screws of femoral intertrochanteric fracture. *Arch Orthop Trauma Surg* 2008; 128: 841–845. DOI: 10.1007/s00402-007-0483-8.
4. Gotfried Y. The lateral trochanteric wall: a key element in the reconstruction of unstable pertrochanteric hip fractures. *Clin Orthop Relat Res* 2004; 425(425): 82–86. DOI: 1097/01.blo.0000132264.14046.c2.
5. Hsu CE, Huang KC, Lin TC, et al. Integrated risk scoring model for predicting dynamic hip screw treatment outcome of intertrochanteric fracture. *Injury* 2016; 47: 2501–2506. DOI: 10.1016/j.injury.2016.09.012.
6. Palm H, Jacobsen S, Sonne-Holm S, et al. Integrity of the lateral femoral wall in intertrochanteric hip fractures: an important predictor of a reoperation. *J Bone Joint Surg Am* 2007; 89: 470–475. DOI: 10.2106/JBJS.F.00679.
7. Tawari AA, Kempegowda H, Suk M, et al. What makes an intertrochanteric fracture unstable in 2015? Does the lateral wall play a role in the decision matrix? *J Orthop Trauma* 2015; 29: S4–S9. DOI: 10.1097/BOT.0000000000000284.
8. Babhulkar S. Unstable trochanteric fractures: issues and avoiding pitfalls. *Injury* 2017; 48: 803–818. DOI: 10.1016/j.injury.2017.02.022.
9. Gupta RK, Sangwan K, Kamboj P, et al. Unstable trochanteric fractures: the role of lateral wall reconstruction. *Int Orthop*

- 2010; 34: 125–129. DOI: 10.1007/s00264-009-0744-y.
10. Parker MJ. Trochanteric hip fractures. Fixation failure commoner with femoral medialization, a comparison of 101 cases. *Acta Orthop Scand* 1996; 67: 329–332.
 11. Niu E, Yang A, Harris AH, et al. Which fixation device is preferred for surgical treatment of intertrochanteric hip fractures in the United States? A survey of orthopaedic surgeons. *Clin Orthop Relat Res* 2015; 473: 3647–3655. DOI: 10.1007/s11999-015-4469-5.
 12. Socci AR, Casemyr NE, Leslie MP, et al. Implant options for the treatment of intertrochanteric fractures of the hip: rationale, evidence, and recommendations. *Bone Joint J* 2017; 99-B: 128–133. DOI: 10.1302/0301-620X.99B1.BJJ-2016-0134.R1.
 13. Haidukewych GJ, Israel TA and Berry DJ. Reverse obliquity fractures of the intertrochanteric region of the femur. *J Bone Joint Surg Am* 2001; 83: 643–650. DOI: 10.2106/00004623-200105000-00001.
 14. Kokoroghiannis C, Aktseles I, Deligeorgis A, et al. Evolving concepts of stability and intramedullary fixation of intertrochanteric fractures—a review. *Injury* 2012; 43: 686–693. DOI: 10.1016/j.injury.2011.05.031.
 15. Parker MJ, Bowers TR and Pryor GA. Sliding hip screw versus the Targon PF nail in the treatment of trochanteric fractures of the hip: a randomised trial of 600 fractures. *J Bone Joint Surg Br* 2012; 94: 391–397. DOI: 10.1302/0301-620x.94b3.28406.
 16. Utrilla AL, Reig JS, Muñoz FM, et al. Trochanteric gamma nail and compression hip screw for trochanteric fractures: a randomized, prospective, comparative study in 210 elderly patients with a new design of the gamma nail. *J Orthop Trauma* 2005; 19: 229–233.
 17. Gao Z, Lv Y, Zhou F, et al. Risk factors for implant failure after fixation of proximal femoral fractures with fracture of the lateral femoral wall. *Injury* 2018; 49: 315–322. DOI: 10.1016/j.injury.2017.11.011.
 18. Kulkarni SG, Babbhulkar SS, Kulkarni SM, et al. Augmentation of intramedullary nailing in unstable intertrochanteric fractures using cerclage wire and lag screws: a comparative study. *Injury* 2017; 48: S18–S22.
 19. Kashigar A, Vincent A, Gunton MJ, et al. Predictors of failure for cephalomedullary nailing of proximal femoral fractures. *Bone Joint J* 2014; 96-b: 1029–1034. DOI: 10.1302/0301-620x.96b8.33644.
 20. Tucker A, Warnock M, McDonald S, et al. Fatigue failure of the cephalomedullary nail: revision options, outcomes and review of the literature. *Eur J Orthop Surg Traumatol* 2018; 28: 511–520. DOI: 10.1007/s00590-017-2059-9.
 21. Kasimatis GB, Lambiris E, Tyllianakis M, et al. Gamma nail breakage: a report of four cases. *J Orthop Surg (Hong Kong)* 2007; 15: 368–372. DOI: 10.1177/23094990070150326.
 22. Boopalan PR, Oh JK, Kim TY, et al. Incidence and radiologic outcome of intraoperative lateral wall fractures in OTA 31A1 and A2 fractures treated with cephalomedullary nailing. *J Orthop Trauma* 2012; 26: 638–642. DOI: 10.1097/BOT.0b013e318244e5ad.
 23. Knobe M, Drescher W, Heussen N, et al. Is helical blade nailing superior to locked minimally invasive plating in unstable pertrochanteric fractures? *Clin Orthop Relat Res* 2012; 470: 2302–2312. DOI: 10.1007/s11999-012-2268-9.
 24. Im GI, Shin YW and Song YJ. Potentially unstable intertrochanteric fractures. *J Orthop Trauma* 2005; 19: 5–9.
 25. Langford J, Pillai G, Ugliailoro AD, et al. Perioperative lateral trochanteric wall fractures: sliding hip screw versus percutaneous compression plate for intertrochanteric hip fractures. *J Orthop Trauma* 2011; 25: 191–195. DOI: 10.1097/BOT.0b013e3181e3fcb4.
 26. Hsu CE, Shih CM, Wang CC, et al. Lateral femoral wall thickness. A reliable predictor of post-operative lateral wall fracture in intertrochanteric fractures. *Bone Joint J* 2013; 95-B: 1134–1138. DOI: 10.1302/0301-620X.95B8.31495.
 27. Sharma G, Singh R, Gn KK, et al. Which AO/OTA 31-A2 pertrochanteric fractures can be treated with a dynamic hip screw without developing a lateral wall fracture?

- A CT-based study. *Int Orthop* 2016; 40: 1009–1017. DOI: 10.1007/s00264-015-2835-2.
28. Baumgaertner MR, Curtin SL, Lindskog DM, et al. The value of the tip-apex distance in predicting failure of fixation of peritrochanteric fractures of the hip. *J Bone Joint Surg Am* 1995; 77: 1058–1064.
 29. Joshi D, Dhamangaonkar AC, Ramawat S, et al. Predictors of iatrogenic lateral wall fractures while treating intertrochanteric fracture femur with the dynamic hip screw system in Indian patients. *Eur J Orthop Surg Traumatol* 2015; 25: 677–682. DOI: 10.1007/s00590-014-1566-1.
 30. Geller JA, Saifi C, Morrison TA, et al. Tip-apex distance of intramedullary devices as a predictor of cut-out failure in the treatment of peritrochanteric elderly hip fractures. *Int Orthop* 2010; 34: 719–722. DOI: 10.1007/s00264-009-0837-7.
 31. Caiaffa V, Vicenti G, Mori C, et al. Is distal locking with short intramedullary nails necessary in stable pertrochanteric fractures? A prospective, multicentre, randomised study. *Injury* 2016; 47: S98–S106. DOI: 10.1016/j.injury.2016.07.038.
 32. Caiaffa V, Vicenti G, Mori CM, et al. Unlocked versus dynamic and static distal locked femoral nails in stable and unstable intertrochanteric fractures. A prospective study. *Injury* 2018; 49: S19–S25. DOI: 10.1016/j.injury.2018.09.063.
 33. Gallagher D, Adams B, El-Gendi H, et al. Is distal locking necessary? A biomechanical investigation of intramedullary nailing constructs for intertrochanteric fractures. *J Orthop Trauma* 2013; 27: 373–378. DOI: 10.1097/BOT.0b013e31827cd5bd.
 34. Mori CM, Vicenti G, Carrozzo M, et al. The fake unlocked femoral nail: a configuration to avoid in stable pertrochanteric femur fractures. *Injury* 2018; 49: S32–S36. DOI: 10.1016/j.injury.2018.09.057.
 35. Chang SM, Song DL, Ma Z, et al. Mismatch of the short straight cephalomedullary nail (PFNA-II) with the anterior bow of the Femur in an Asian population. *J Orthop Trauma* 2014; 28: 17–22. DOI: 10.1097/BOT.0000000000000022.