

Total ankle replacement for posttraumatic arthritis

Similar outcome in postfracture and instability arthritis: a comparison of 90 ankles

Rebecca A NIEUWE WEME¹, Guido VAN SOLINGE², Job N DOORNBERG¹, Inger SIEREVELT¹, Daniël HAVERKAMP¹, and H Cornelis DOETS³

¹ Department of Orthopaedic Surgery, Slotervaart Hospital, Amsterdam; ² Department of Orthopaedic Surgery, Isala Klinieken, Zwolle;

³ Department of Orthopaedic Surgery, Medisch Centrum Amstelveen, Amstelveen, the Netherlands.

Correspondence: Daniel@drhaverkamp.com

Submitted 2014-08-26. Accepted 2015-01-12.

Background and purpose — Most studies on total ankle replacement (TAR) have used a case mix of patients. We evaluated the outcome of TAR performed for end-stage arthritis either because of fracture or ligamentous injury.

Patients and methods — We prospectively followed 88 consecutive patients (50 postfracture ankles and 40 ankles with instability arthritis (2 bilateral)) who underwent TAR between 2001 and 2009. Mean follow-up for both groups was 5 years.

Results — Preoperative varus deformity of 10° or more was present in 23 ankles in the instability group. At 6 years, survival with revision or salvage fusion as an endpoint was 87% (95% CI: 74–99) in the postfracture group and 79% (95% CI: 63–94) in the instability group. Progressive periprosthetic osteolysis was seen in 23 ankles, and required salvage fusion in 6. The number of reoperations was similar in both groups. Clinical outcome, as assessed with 2 ankle scores and 2 questionnaires, showed good results and was similar at the latest follow-up.

Interpretation — The outcome was similar in the postfracture and instability groups and also similar to that reported in series including a case mix of patients. In contrast to earlier reports, preoperative frontal plane deformity in this series was not identified as a risk factor for failure.

traumatic arthritis, but some studies have focused on TAR in combined cohorts of posttraumatic and primary osteoarthritis (Saltzman et al. 2010, Bai et al. 2010, Flavin et al. 2013). This is surprising, as posttraumatic arthritis is considered to be the most frequent cause of ankle arthritis (Saltzman et al. 2005).

2 subgroups of posttraumatic arthritis should be distinguished: (1) postfracture arthritis, secondary to an intra- or juxta-articular fracture; and (2) ligamentous posttraumatic arthritis, secondary to a single severe ankle sprain or as a result of recurrent or chronic instability (Valderrabano et al. 2009). We refer to the latter as instability arthritis. Patients suffering from end-stage instability arthritis frequently present with a varus deformity of the ankle as a result of both lateral ligament laxity and asymmetric cartilage loss medially (Harrington 1979, Doets et al. 2008, Ryssman and Myerson 2011).

We evaluated the medium-term outcome of TAR for end-stage posttraumatic ankle arthritis and compared it for postfracture arthritis and for instability arthritis. Our research questions were whether patients treated with TAR for instability arthritis—as they more frequently have a deformity and perhaps also residual instability after TAR—will have worse results with respect to (1) implant survival, (2) the number of reoperations, and (3) ankle-specific and general patient- and physician-based outcomes.

Patients and methods

We included all patients who had been treated with a primary TAR at our institution for end-stage posttraumatic arthritis between March 2001 and December 2009. We identified 90 TARs in 88 patients with a mean age of 57 (28–77) years at surgery. These patients were divided into 2 subgroups based

Most published articles on total ankle replacement (TAR) have presented results from mixed cohorts of patients suffering from end-stage ankle arthritis of several different etiologies, such as posttraumatic arthritis, primary arthritis, and rheumatoid arthritis (Buechel et al. 2003, Wood et al. 2008, Bonnin et al. 2011, Rippstein et al. 2011, Barg et al. 2013, Zaidi et al. 2013). To our knowledge, there have been no studies on TAR concentrating exclusively on patients with post-

Table 1. Patient demographics at the time of surgery

	Postfracture OA n = 50	Instability OA n = 40	Total n = 90
Mean age (range)	54 (28–74) ^a	58 (32–77) ^a	56 (28–77)
Male/female	27 / 23 ^a	31 / 9 ^a	58 / 32
Side (right/left)	29 / 21	19 / 21	48 / 42
Mean BMI (range)	28 (22–39)	28 (22–34)	28 (22–39)
Median in-hospital stay (IQR), days	5 (4–5)	5 (5–6)	5 (4–5)
Type of prosthesis (BP/CCI)	7 / 43	8 / 32	15 / 75

^a p-value < 0.05.

BP: Buechel-Pappas; CCI: Ceramic Coated Implant.

on their primary diagnosis: 50 TARs (all unilateral) in the postfracture group (ankle arthritis after a malleolar fracture (n = 36), a lower leg fracture (n = 10), a tibial pilon fracture (n = 3), and a talar fracture (n = 1)) and 40 TARs (2 bilateral) in the instability group (defined as previously described). The ankles had been symptomatic for mean 11 (1–35) years prior to TAR (Table 1).

2 prosthetic designs were used in this study. The first 15 TARs used the Buechel-Pappas (BP) mobile-bearing prosthesis (Endotec, South Orange, NJ), and from April 2004 onwards 75 TARs were performed with the Ceramic Coated Implant (CCI) mobile-bearing prosthesis (Wright Medical Technology, Arlington, TN). Revision was defined according to Henricson et al. (2011a) as removal or exchange of 1 or more of the prosthetic components, with the exception of the incidental exchange of the polyethylene insert, e.g. during open debridement. Reoperation was defined as any subsequent non-revision surgery with involvement of the joint (open or arthroscopic).

All 90 TARs were evaluated at the outpatient clinic by HCD. Data for the ankle-specific American Orthopaedic Foot and Ankle Society score (AOFAS) and the Kofoed ankle score were obtained (Kitaoka et al. 1994, Kofoed and Stürup 1994). Combined ankle-hindfoot range of motion (ROM) in the sagittal plane was measured clinically: dorsiflexion while the patient was standing, plantar flexion while the patient was sitting. Preoperative data (baseline), and data at 1 year and at the latest follow-up (end date: September 2012) were used for analysis. Furthermore, at the latest follow-up, patients were invited to fill in the region-specific Foot and Ankle Ability Measure questionnaire (FAAM) (Martin et al. 2005) and the generic Short Form 36 (SF-36) questionnaire. Clinical outcomes were quantified by the following scoring systems: regarding ipsilateral ankle-hindfoot pain and function, by both the AOFAS ankle-hindfoot score and the Kofoed ankle score; and for activities of daily living (ADL) and sport activities, using the FAAM score. Perceived disability was quantified with the SF-36 questionnaire (Ware et al. 1994). The Dutch translation of this survey has been validated (Aaronson et al. 1998).

Preoperative radiographic evaluation and radiographic evaluation at follow-up was done using standardized antero-posterior and lateral radiographs of the ankle and foot. Preoperative weight-bearing radiographs were taken in all patients, and, from 2009, also at follow-up. When cystic changes were seen on plain radiographs, computed tomography (CT) was done. Radiographs were assessed for preoperative tibio-talar alignment, for migration of the TAR components, and for radiolucency and osteolysis—both by HCD and by an independent musculoskeletal radiologist.

Statistics

Survival analysis was performed using the Kaplan-Meier approach for the 2 definitions of failure: revision and reoperation. Patients who were lost to follow-up, or who had died with their prosthesis in situ, were defined as censored. Log rank tests were performed at the end of each time interval of 1 year, to assess the difference between the postfracture group and the instability group.

Group comparisons of the outcome measures were performed using Student's t-test or the Mann-Whitney U-test for continuous outcomes, or with chi-squared test for categorical variables. Due to skewed distribution of the response variables (e.g. AOFAS, Kofoed, FAAM), comparisons were made univariately using the Mann-Whitney U-test. In cases of suspected confounding, separate univariate analysis was performed to determine the necessity for correction. Any p-value less than 0.05 was considered significant.

Ethics

The study was approved by our institutional review board (P1222).

Results

Preoperative alignment

Tibiotalar valgus deformity was found in 2 ankles in the postfracture group (12° and 18°, respectively), but mean alignment in this group was 0° (range, 6° of varus to 18° of valgus). Tibiotalar varus deformity of 10° or more was present in 23 ankles, all of them in the instability group. Mean alignment in the instability group was 11° of varus (range: 0° to 30° of varus). The difference in varus deformity between groups was statistically significant (p = 0.03).

Survival analysis

At the last follow-up, 13 ankles in 13 patients were revised or had undergone a salvage fusion (Table 2) and 3 patients had died (3 ankles). Follow-up data from the deceased patients were available until the latest outpatient visit before death. 2 patients refused to fill in the questionnaires. None of these 5 patients had a revision of their implant and none were included in the survival analysis. Thus, 74 TARs were followed up, 72

Table 2. Data on the 13 ankles that required a revision or a salvage fusion

Case no.	Age at surgery	Months to revision	Procedure (component)	Reason for revision
Postfracture OA				
40	49	74	Salvage fusion	Osteolysis
54	59	67	Salvage fusion	Osteolysis + talar loosening
60	59	66	Salvage fusion	Osteolysis
64	70	50	Salvage fusion	Osteolysis + tibial loosening
80	53	22	Salvage fusion	Talar loosening
Instability OA				
10	58	121	Salvage fusion	Osteolysis
20	53	15	Tibial revision	Tibial loosening (malposition)
26	67	8	Tibial revision	Tibial loosening (malposition)
34	53	13	Tibial revision	Tibial loosening (malposition)
36	74	70	Salvage fusion	Osteolysis
44	59	10	Salvage fusion	Varus deformity after traumatic medial malleolar fracture
48	53	47	Salvage fusion	Talar loosening + tibial osteolysis
51	53	14	Tibial revision	Tibial loosening

OA: osteoarthritis.

of which had a complete dataset with questionnaires included. Survival rate (defined by revision or removal of the prosthesis by 6 years postoperatively) was 87% (95% CI: 74–99) in the postfracture group and 79% (95% CI: 63–94) in the instability group. Reoperations, defined as subsequent surgery with involvement of the ankle joint without removal of the prosthesis, were carried out in 23 ankles. Using log rank tests, no significant differences in survival were found between groups, either with revision as an endpoint (Figure and Table 3, see Supplementary data) or with revision and/or reoperation as an endpoint (Table 4, see Supplementary data). After 6 years, the groups became too small for proper survival analysis (< 10 patients per group).

Age and sex, both of which were significantly different between groups at baseline ($p = 0.04$ and $p = 0.03$, respectively), were tested univariately for the risk of failure of the prosthesis. There was no statistically significant influence of these variables on survival.

Additional intraoperative procedures, complications, and subsequent surgery

Percutaneous Achilles tendon lengthening was performed in 16 ankles when dorsiflexion was insufficient (less than 5°) at the end of the procedure. Medial malleolar lengthening osteotomy was carried out when, despite a release of the deep part of the medial collateral ligament, varus instability with bearing subluxation persisted when tested with trial bearings (Doets et al. 2008). Medial malleolar osteotomy was carried out more often in the instability group: in 20 of 24 ankles with a preoperative varus deformity of 10° or more and in 4 of 16 with less than 10° varus.

Complications occurred in 23 ankles, 12 in the postfracture group and 11 in the instability group. 1 intraoperative tibial

fracture, the talar fracture, and the 9 intraoperative malleolar fractures healed with prolonged immobilization; in the majority, internal fixation was not required. 7 ankles developed a wound-healing disturbance. All were successfully treated by prolonged immobilization and wound treatment. 1 TAR developed an deep infection, which was successfully treated with lavage locally and systemic antibiotics.

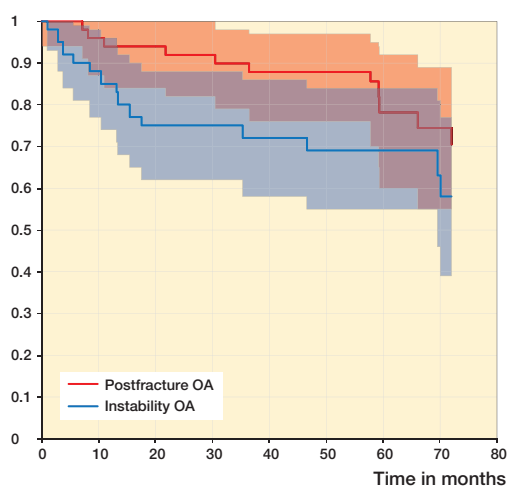
Subsequent surgery without implant exchange included either open or arthroscopic debridement in 10 TARs for symptomatic talar-malleolar arthritis. 6 TARs with progressive osteolytic cysts were treated with open debridement and grafting of the defect with autologous cancellous bone combined with routine bearing exchange at an average of 67 (37–92) months after the index operation. With longer follow-up, 2 of these 6 ankles eventually required a salvage fusion, as the cysts reoccurred. For details of reoperations and additional intraoperative procedures and perioperative complications, see Table 5 in Supplementary data.

Clinical outcome (Table 6, see Supplementary data)

Mean AOFAS score at baseline (preoperatively) was 40 (33–54) in the postfracture group and 31 (25–42) in the instability arthritis group, due to a difference in alignment subscore, as many instability ankles scored 0 points instead of 10 points. At 1 year, the scores had improved substantially, to 83 (73–94) in the postfracture group and to 88 (78–95) in the instability arthritis group. Scores at the latest follow-up did not decline. There were similar findings with the Kofoed ankle scores at baseline and at follow-up.

ROM differed 5° at baseline in favor of the instability group, mainly because of a limited dorsiflexion of 3° in the postfracture group. This difference was significant ($p < 0.01$), and it remained so at the latest follow-up.

Survival with 95% CI



Kaplan-Meier survival curve with revision and/or reoperation as an endpoint for both the postfracture group and the instability group, with 95% confidence intervals.

In addition, we investigated whether ROM increased in rigid ankles after TAR. Rigid was defined as a baseline dorsiflexion of less than 0° (n = 46) and mobile was defined as a baseline dorsiflexion of more than 0° (n = 24). At the latest follow-up, dorsiflexion remained significantly lower (p = 0.03) in the rigid group (6°, range: -5° to 12°) than in the mobile group (8°, range: 0° to 15°). Furthermore, overall ROM was 5° better in the mobile group, with borderline significance (p = 0.05). When computing change from baseline to latest follow-up, we found an improvement in dorsiflexion of 8.5° (range: -5° to 25°) in the rigid ankles (p < 0.001), whereas the mobile ankles showed no increase in dorsiflexion.

Patient-reported outcomes

As assessed by FAAM, activities of daily living (ADL) did not fully normalize, and the level of sport activities was fair to low. Disability as assessed by SF-36 showed good social functioning but some limitations regarding persistent pain and vitality. Outcome at the latest follow-up was similar for both groups, with both scoring systems. For details of the ankle scores, ROM, and patient-reported outcomes, see Table 7 in Supplementary data.

Radiographic outcome

At the latest follow-up, 11 of the 77 unrevised TARs showed a small (1-mm) complete radiolucent line around the tibial component (5 in the postfracture group and 6 in the instability group). 2 postfracture TARs showed partial radiolucent lines around the tibial component. Subsidence of the tibial component was not seen in the unrevised TARs. 2 TARs showed complete radiolucent lines around the talar component (1 in the postfracture group and 1 in the instability group). Slight subsidence of the talar component was seen in 8 ankles (postfracture, 1; instability, 7). In 23 ankles (postfracture, 13; instability, 10) periprosthetic osteolytic lesions larger than 10 mm were identified, either in the tibia or in the talus, or in both. These lesions occurred after an average interval since the index operation of 53 (13–118) months. 6 of these osteolytic ankles required a salvage fusion with longer follow-up (Table 2).

Discussion

TAR is an accepted surgical treatment for end-stage ankle arthritis (Haddad et al. 2007, Saltzman et al. 2009, Zaidi et al. 2013). In contrast to osteoarthritis of the hip and knee, post-traumatic arthritis is the most frequent cause of end-stage ankle arthritis (Saltzman et al. 2005, Brown et al. 2006, Valderrabano et al. 2009). Most papers on TAR have presented results for a combination of several etiological subgroups: posttraumatic arthritis, primary arthritis, inflammatory arthritis, and other etiologies (Buechel et al. 2003, Wood et al. 2008, Bonnin et al. 2011, Rippstein et al. 2011, Barg et al. 2013). However, in

view of the high rate of patients with a diagnosis of primary ankle arthritis in many series (Zaidi et al. 2013), it might well be possible that a large number of ankles, classified in many studies on TAR as primary arthritis, are actually secondary to ankle sprains and chronic instability. Varus deformity is frequently present in ankles with end-stage instability arthritis (Harrington 1979). As preoperative frontal plane deformity has been identified as a risk factor for failure of TAR (Doets et al. 2006, Henricson and Ågren 2007, Wood et al. 2008), the etiology of ankle arthritis may be of value for evaluation of the indication for and the expected outcome of TAR.

We investigated the medium-term results of mobile-bearing TAR for 2 subgroups of posttraumatic arthritis: postfracture arthritis and instability arthritis. The demographics of the subgroups differed with respect to age and sex: in the instability group, there were more males and mean age was somewhat higher. Furthermore, there was a high rate of varus deformity in this group. Otherwise, the patient characteristics were similar in both groups. Thus, the 2 groups varied mainly with respect to the etiology of their ankle arthritis, leading to stiffer ankles in the postfracture group and to a high rate of varus deformity in the instability group. Consequently, we expected that TAR for postfracture ankles would lead to stiffer ankles and possibly reduced function, and that TAR for instability arthritis might have a higher failure rate of the implant and might also lead to more reoperations. However, we found similar 6-year implant survival rates in the 2 subgroups, 87% and 79% respectively, which is comparable to those in a recent registry study and 2 systematic reviews (Gougoulis et al. 2010, Henricson et al. 2011b, Zaidi et al. 2013). So, both of our hypotheses that TAR for instability arthritis would have a worse survival and/or more reoperations could not be confirmed at medium-term follow-up. Furthermore, clinical outcome—as assessed with the AOFAS and Kofoed scoring systems and with 2 validated questionnaires—was similar between the postfracture TARs and the instability TARs. Dorsiflexion improved in the stiff ankles to a functional level. These findings are in line with our third hypothesis.

The most prominent failure mechanism was osteolysis, which required salvage fusion in 6 ankles (2 after a failed debridement and grafting procedure). Periprosthetic osteolysis after TAR has been described before with several designs, both of the fixed-bearing and the mobile-bearing type (Besse et al. 2009, Koivu et al. 2009, Kim et al. 2010, Kraal et al. 2013, Yoon et al. 2014, Prissel and Roukis 2014). Mechanical loosening of the tibial component occurred in 4 ankles in the instability group—in 3 of these, in relation to component malposition. These ankles were successfully revised by tibial component exchange. Furthermore, there was 1 failure due to a recurrent deformity after a late traumatic medial malleolar fracture. Mechanical loosening of the talar component was seen in 2 ankles, in 1 combined with tibial osteolysis. Potential failures might be subsidence of the talar component (as seen in 8 ankles) and progressive periprosthetic osteolysis.

A weakness of our study was the small number of TARs available with more than 6 years of follow-up. Furthermore, no multivariate analysis on the reasons for failure could be carried out due to the low number of events. Another weakness was that patient-reported outcomes were only available at the latest follow-up.

In summary, at medium-term follow-up, TAR for postfracture and for instability arthritis performed similarly, despite the high rate of preoperative varus deformity in the instability group. These results contrast with earlier medium-term reports on the outcome of TAR, in which preoperative frontal plane deformity was found to lead to reduced implant survival (Doets et al. 2006, Henricson and Ågren 2007, Wood et al. 2008). This similar survival rate might be the result of improved balancing techniques used at our institution in recent years, such as lengthening osteotomy of the medial malleolus. Considering the high rate of preoperative deformity with instability arthritis, we propose to classify this diagnosis as a separate item, apart from other etiologies, in future reports on TAR. Finally, in the present study as in other recently published series, periprosthetic osteolysis was present in a high number of ankles at medium-term follow-up.

Supplementary data

Tables 3–7 are available at Acta's website (www.actaorthop.org), identification number 7944.

RANW, INS, DH, and HCD performed the retrospective and descriptive analyses, carried out the statistical analysis of the dataset, and drafted the manuscript. RANW, GvS, JND, DH, and HCD contributed by performing patient follow-up visits, radiographic analysis, gathering of data, and translation or revision of the manuscript. HCD conceived the study and its design and performed all the operations.

No competing interest declared.

Aaronson N K, Muller M, Cohen P D, et al. Translation, validation, and norming of the Dutch language version of the SF-36 Health Survey in community and chronic disease populations. *J Clin Epidemiol* 1998; 51: 1055–68.

Bai L B, Lee K B, Song E K, Yoon T R, Seon J K. Total ankle arthroplasty outcome comparison for posttraumatic and primary osteoarthritis. *Foot Ankle Int* 2010; 31: 1048–56.

Barg A, Zwicky L, Knupp M, Henninger H B, Hintermann B. HINTEGRA total ankle replacement: survivorship analysis in 684 patients. *J Bone Joint Surg Am* 2013; 95A: 1175–83.

Besse J L, Brito N, Lienhart C. Clinical evaluation and radiographic assessment of bone lysis of the AES total ankle replacement. *Foot Ankle Int* 2009; 30: 964–75.

Bonnin M, Gaudot F, Laurent J-R, et al. The Salto total ankle arthroplasty: survivorship and analysis of 339 failures at 7 to 11 years. *Clin Orthop Rel Res* 2011; 469: 225–36.

Buechel F F Sr, Buechel F F Jr, Pappas M J. Ten-year evaluation of cementless Buechel-Pappas meniscal bearing total ankle replacement. *Foot Ankle Int* 2003; 24: 462–72.

Brown T D, Johnston R C, Saltzman C L, Marsh J L, Buckwalter J A. Post-traumatic osteoarthritis: a first estimate of incidence, prevalence, and burden of disease. *J Orthop Trauma* 2006; 20: 739–44.

Doets H C, Brand R, Nelissen R G H H. Total ankle arthroplasty in inflammatory joint disease with use of two mobile-bearing designs. *J Bone Joint Surg Am* 2006; 88-A: 1272–84.

Doets H C, Van der Plaats L W, Klein J P. Medial malleolar osteotomy for the correction of varus deformity during total ankle arthroplasty. Results in 15 ankles. *Foot Ankle Int* 2008; 29: 171–7.

Flavin R, Coleman S C, Tenenbaum S, Brodsky J W. Comparison of gait after total ankle arthroplasty and ankle arthrodesis. *Foot Ankle Int* 2013; 34: 1340–8.

Gougoulias N, Khanna A, Maffulli N. How successful are current ankle replacements?: a systematic review of the literature. *Clin Orthop Rel Res* 2010; 468: 199–208.

Haddad S L, Coetzee J C, Estok R, et al. Intermediate and long-term outcomes of total ankle arthroplasty and ankle arthrodesis. A systematic review of the literature. *J Bone Joint Surg Am* 2007; 89-A: 1899–905.

Harrington K D. Degenerative arthritis of the ankle secondary to long-standing lateral ligament instability. *J Bone Joint Surg Am* 1979; 53-A: 203–15.

Henricson A, Ågren P H. Secondary surgery after total ankle replacement. The influence of preoperative hindfoot alignment. *Foot Ankle Surg* 2007; 13: 41–4.

Henricson A, Nilsson J-Å, Carlsson Å. 10-year survival of total ankle arthroplasties. A report on 780 cases from the Swedish Ankle Register. *Acta Orthop* 2011a; 82: 655–9.

Henricson A, Carlsson A, Rydholm U. What is a revision of total ankle replacement? *Foot Ankle Surg* 2011b; 17: 99–102.

Kim B S, Knupp M, Zwicky L, Lee J W, Hintermann B. Total ankle replacement in association with hindfoot fusion. Outcome and complications. *J Bone Joint Surg Br* 2010; 92-B: 1540–7.

Kitaoka H B, Alexander I J, Adelaar R S, et al. Clinical rating system for the ankle-hindfoot, midfoot, hallux and lesser toes. *Foot Ankle Int* 1994; 15: 349–53.

Kofoed H, Stürup J. Comparison of ankle arthroplasty and arthrodesis. *Foot* 1994; 4: 6–9.

Koivu H, Kohonen I, Sipola E, et al. Severe periprosthetic osteolytic lesions after the Ankle Evolutive System total ankle replacement. *J Bone Joint Surg Br* 2009; 91-B: 907–14.

Kraal T, Van der Heide H J L, Van Poppel B J, et al. Long-term follow-up of mobile-bearing total ankle replacement in patients with inflammatory joint disease. *Bone Joint J* 2013; 95-B: 1656–61.

Martin R L, Irrgang J J, Burdett R G, Conti S F, Van Swearingen J M. Evidence of validity for the Foot and Ankle Ability Measure (FAAM). *Foot Ankle Int* 2005; 26: 968–83.

Prissel M A, Roukis T S. Management of extensive tibial osteolysis with the Agility total ankle replacement systems using geometric metal-reinforced polymethylmethacrylate cement augmentation. *J Foot Ankle Surg* 2014; 53: 101–7.

Rippstein P F, Huber M, Coetzee J C, Naal F D. Total ankle replacement with use of a new threecomponent implant. *J Bone Joint Surg Am* 2011; 93-A: 1426–35.

Ryssman D, Myerson M S. Surgical strategies: The management of varus ankle deformity with joint replacement. *Foot Ankle Int* 2011; 32: 217–24.

Saltzman C L, Salamon M L, Blanchard M, et al. Epidemiology of ankle arthritis: report of a consecutive series of 639 patients from a tertiary orthopaedic center. *Iowa Orthop J* 2005; 25: 44–6.

Saltzman C L, Mann R A, Ahrens J E, et al. Prospective controlled trial of STAR total ankle replacement versus ankle fusion: initial results. *Foot Ankle Int* 2009; 30: 579–96.

Saltzman C L, Kadoko R G, Suh J S. Treatment of isolated ankle osteoarthritis with arthrodesis or the total ankle replacement: a comparison of early outcomes. *Clin Orthop Surg* 2010; 2: 1–7.

Valderrabano V, Horisberger M, Russel I, Dougall H, Hintermann B. Etiology of ankle osteoarthritis. *Clin Orthop Rel Res* 2009; 467: 1800–6.

- Ware J E, Kosinski M, Keller S. SF-36 Physical and Mental Health Summary Scales: A User's Manual. Boston: Health Assessment Lab, New England Medical Center, 1994.
- Wood P L R, Prem H, Sutton C. Total ankle replacement. 395 Medium-term results in 200 Scandinavian total ankle replacements. *J Bone Joint Surg Br* 2008; 90B: 605-9.
- Yoon H S, Lee J, Choi W J, Lee J W. Periprosthetic osteolysis after total ankle arthroplasty. *Foot Ankle Int* 2014; 35: 14-21.
- Zaidi R, Cro S, Gurusamy N, et al. The outcome of total ankle replacement. A systematic review and meta-analysis. *Bone Joint J* 2013; 95-B: 1500-7.