

Available online at www.sciencedirect.com

ScienceDirect

journal homepage: <http://Elsevier.com/locate/radcr>

Complications of Therapy

Displacement of a power-injectable PICC following computed tomography pulmonary angiogram

Jonathan Tak Loong Lee MBBS (Hons), BMedSc (Hons)*, James Ricketts FRCR

Department of Radiology, The Alfred Hospital, Victoria, Australia

ARTICLE INFO

Article history:

Received 27 June 2017

Received in revised form 9 July 2017

Accepted 19 July 2017

Available online

Keywords:

Central venous access

PICC

CTPA

ABSTRACT

Displacement of peripherally inserted central catheter (PICC) lines during contrast-enhanced computed tomography examinations is an underappreciated phenomenon. We report a case of iatrogenic PICC line displacement following the power injection of contrast during a computed tomography pulmonary angiogram. During the study, the PICC line was shown to move on 2 occasions, resulting in 2 nondiagnostic studies. We review the available literature on the topic and suggest possible strategies to avoid this phenomenon. Radiologists should be aware of PICC line migration, and it should become common practice to review the catheter tip position after computed tomography examinations.

© 2017 the Authors. Published by Elsevier Inc. under copyright license from the University of Washington. This is an open access article under the CC BY-NC-ND license (<http://creativecommons.org/licenses/by-nc-nd/4.0/>).

Case

A 50-year-old man with 35% total body burns had a right-sided peripherally inserted central catheter (PICC) inserted under fluoroscopic guidance for prolonged intravenous antibiotic therapy. The line was an open-ended, double-lumen 5-French power-injectable PICC (PowerPICC; Bard Access Systems, Salt Lake City, UT) [1]. Four weeks into admission, the patient developed a persistent tachycardia, and a computed tomography pulmonary angiogram (CTPA) was requested to exclude a pulmonary embolism. The initial scout radiograph from the computed tomography (CT) confirmed the PICC line was appropriately positioned within the superior vena cava, at the atriocaval junction (Fig. 1A). After a small test bolus, the CTPA was performed with 90 mL of warmed iodinated contrast infused at a rate of 5 mL/s. The radiographer observed that there was poor contrast

opacification of the pulmonary vasculature. The radiologist noted that the tip of the PICC line had moved, and a repeat scout image showed the PICC was now looped within the right internal jugular vein, with the tip still facing down into the superior vena cava (Fig. 1B). A second CTPA was attempted, this time at a lower flow rate of 4 mL/s. There was again a suboptimal enhancement of the pulmonary arterial tree, and a subsequent scout image demonstrated a further displacement of the PICC catheter tip, which was now facing up into the right internal jugular vein (Fig. 1C). The study was declared as nondiagnostic, and the patient was transferred for a ventilation-perfusion scan where a pulmonary embolus was excluded. The patient went on to have the right-sided PICC line removed, and a new line was placed via a left-sided approach. A review of the patient's imaging revealed no congenital or acquired anatomic abnormalities of the central veins, and the patient did not have a history of cardiac disease to suggest an impaired cardiac function.

* Corresponding author.

E-mail address: leejonathantl@gmail.com (J.T.L. Lee).

<https://doi.org/10.1016/j.radcr.2017.07.016>

1930-0433/© 2017 the Authors. Published by Elsevier Inc. under copyright license from the University of Washington. This is an open access article under the CC BY-NC-ND license (<http://creativecommons.org/licenses/by-nc-nd/4.0/>).

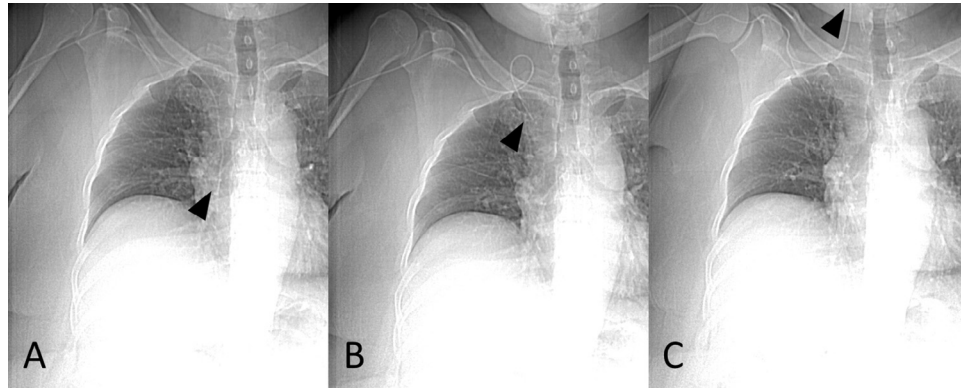


Fig. 1 – Scout images taken during a CTPA study demonstrating (A) the appropriate positioning of the PICC line before study commencement, inferior to the tracheobronchial angle (arrowhead at the distal catheter tip), (B) the subsequent looping of the PICC line in the right internal jugular vein following an initial power-contrast injection at 5 mL/s (arrowhead at the distal catheter tip), and (C) the complete displacement of the catheter tip into the right internal jugular vein after a second study attempt at 4 mL/s (arrowhead at the distal catheter tip), resulting in 2 nondiagnostic studies.

Discussion

Central venous access via a PICC line is widely used in settings where patients have difficult peripheral venous access and require long-term intravenous therapy. The ideal catheter position has been debated in the literature, but it is generally accepted that, in most clinical settings, the tip should lie within the superior vena cava, adjacent to the atriocaval junction [2]. Displaced catheter tips pose a clinical problem as they are associated with potentially serious complications such as central venous thrombosis [3], vessel wall erosion [4], and rarely, fatal cardiac tamponade [5]. In a retrospective review of over 3000 oncology patients, the most common site of PICC line misplacement was the internal jugular vein followed by the axillary vein [6]. Migration has been associated with increases in intrathoracic pressures when patients cough or vomit [7], and has also been described with abduction and adduction of the upper limbs [8]. Since the approval of the use of power-injectable PICC lines by the US Food and Drug Administration, there is now a growing recognition of iatrogenic PICC line displacement, with increasing reports in the literature of migrating PICC lines following a power injection of contrast media for imaging studies. Two retrospective studies have estimated the rate to be between 8.2% and 15.4% [9,10].

The mechanism behind this is thought to obey Newton's third law of motion, that every action has an equal and opposite reaction. It is proposed that increased torque from contrast extrusion results in a propulsion of the catheter tip along the vessel wall. Once the stored kinetic energy in a bent catheter is released, the tip travels in the direction of least resistance, which may be upstream and into another vein [11]. Therefore, decreasing the flow rate at the catheter tip should theoretically reduce the chance of catheter migration. The Poiseuille law dictates that the flow rate through a tubular structure is directly affected by the length and the diameter of the catheter, as well as the medium viscosity and the injection rate [12]. Contrast viscosity is inversely proportional to the temperature, and hence warmer media may offer less resistance through the catheter.

Despite this, in a series of 20 PICC line displacements following contrast-enhanced CT scans, there was no correlation with the catheter gauge, the number of lumens, the rate of injection (average 4 mL/s), and the risk of displacement [10]. Although in the laboratory the flow rate and the temperature may appear to have a demonstrable effect, in our case, even after using warmed contrast and a reduced flow rate, the catheter tip still migrated. Furthermore, for imaging studies such as a CTPA, study sensitivity is heavily dependent on good arterial opacification, which requires higher flow rates of 4–5 mL/s [13].

The design of the catheter tip is likely to have an effect on catheter migration rates, but the available literature in this area is sparse. Catheter tips are generally either open-ended, or closed-ended with side holes. In our case, the PowerPICC (Bard Access Systems) had a valveless, distally trimmable, open-ended tip design with no side holes. We suspect that power injection with contrast extrusion through side holes at an angle of incidence of 90° between the catheter tip and the vessel wall may affect the propulsion of the catheter; however, we could not identify any prospective clinical studies directly comparing displacement risk in power-injectable PICC lines with different tip designs. In a large series of 392 PICC line insertions, there were 5 catheter displacements in patients with an open-ended Vaxcel PICC (Navilyst Medical, Marlborough, MA) as compared to 6 displacements in those with a close-ended Groshong PICC (Bard Access Systems) ($P = .769$); however, these catheters were used almost exclusively for antibiotics or chemotherapy, rather than for contrast-enhanced CT scans [14].

Lozano and colleagues found that among 12 patients with misplaced PICCs, the initial catheter tip position relative to the tracheobronchial angle was significantly associated with an increased risk of post-power-contrast displacement (62.5% became displaced if proximal to the tracheobronchial angle compared with 10.14% if distal to the tracheobronchial angle, $P < .006$) [9]. Other authors have also suggested that a left-sided catheter may result in a higher risk of upward catheter tip migration due to the increased maximum lateral velocity at the catheter tip once it has navigated the longer and flatter left brachiocephalic vein [15]. Despite this, our case and others have described the

phenomenon occurring in patients with right-sided PICC access [16]. Finally, variations in the diameter of the superior vena cava or of the central venous anatomy are common and are likely to affect the risk of PICC line migration [17].

Given the available evidence, alternative intravenous access could be considered in cases where the initial scout image demonstrates the catheter tip to be above the tracheobronchial angle. For radiologists evaluating the postcontrast scans, we would advocate routine assessment of the catheter tip location, particularly in cases of suboptimal contrast enhancement. From our experience with CTPAs, suboptimal enhancement is often attributed to patient size, respiratory motion, or inadequate timing; however, transient catheter displacement during the study may be an under-recognized cause of a poor-quality examination as the catheter tip may migrate back to its original position immediately following contrast injection.

Conclusion

The use of PICC lines for the injection of contrast media for imaging studies is a very useful technique that saves time and prevents unnecessary cannulation of patients. However, the literature suggests that this carries the risk of causing catheter migration in up to 15% of cases. Careful identification of line migration will not only lead to improved patient outcomes but also help identify the cause of a poor-quality study.

REFERENCES

- [1] C. R. Bard, Inc. Bard PowerPICC product information; 2010. Available from: http://www.bardaccess.com/assets/literature/MC-0073-02_Nursing_PowerPICC_Brochure_web.pdf. [Accessed 5 July 2017].
- [2] Tan PL, Gibson M. Central venous catheters: the role of radiology. *Clin Radiol* 2006;61(1):13–22.
- [3] Ballard DH, Samra NS, Gifford KM, Roller R, Wolfe BM, Owings JT. Distance of the internal central venous catheter tip from the right atrium is positively correlated with central venous thrombosis. *Emerg Radiol* 2016;23(3):269–73.
- [4] Forauer AR, Theoharis C. Histologic changes in the human vein wall adjacent to indwelling central venous catheters. *J Vasc Interv Radiol* 2003;14(9 Pt 1):1163–8.
- [5] Collier PE, Blocker SH, Graff DM, Doyle P. Cardiac tamponade from central venous catheters. *Am J Surg* 1998;176(2):212–4.
- [6] Song L, Li H. Malposition of peripherally inserted central catheter: experience from 3,012 patients with cancer. *Exp Ther Med* 2013;6(4):891–3.
- [7] Qiu XX, Guo Y, Fan HB, Shao J, Zhang XB. Incidence, risk factors and clinical outcomes of peripherally inserted central catheter spontaneous dislodgment in oncology patients: a prospective cohort study. *Int J Nurs Stud* 2014;51(7):955–63.
- [8] Forauer AR, Alonzo M. Change in peripherally inserted central catheter tip position with abduction and adduction of the upper extremity. *J Vasc Interv Radiol* 2000;11(10):1315–8.
- [9] Lozano LA, Marn C, Goodman LR. Power injectable peripherally inserted central venous catheter lines frequently flip after power injection of contrast. *J Comput Assist Tomogr* 2012;36(4):427–30.
- [10] Morden P, Sokhandon F, Miller L, Savin M, Kirsch M, Farah M, et al. The role of saline flush injection rate in displacement of CT-injectable peripherally inserted central catheter tip during power injection of contrast material. *AJR Am J Roentgenol* 2014;202(1):W13–8.
- [11] Lim BK, Balasubramaniam BS. Dislodgement of a power-injectable peripherally inserted central catheter after power injection: a case report. *J Assoc Vasc Access* 2013;18(1):27–9.
- [12] Carlson JE, Hedlund LJ, Trenkner SW, Ritenour R, Halvorsen RA Jr. Safety considerations in the power injection of contrast media via central venous catheters during computed tomographic examinations. *Invest Radiol* 1992;27(5):337–40.
- [13] Schoepf UJ, Costello P. CT angiography for diagnosis of pulmonary embolism: state of the art. *Radiology* 2004;230(2):329–37.
- [14] Ong CK, Venkatesh SK, Lau GB, Wang SC. Prospective randomized comparative evaluation of proximal valve polyurethane and distal valve silicone peripherally inserted central catheters. *J Vasc Interv Radiol* 2010;21(8):1191–6.
- [15] Marcy PY, Guiffant G, Flaud P. Catheter tip displacements at power PICC CT injection. *AJR Am J Roentgenol* 2014;203(6):W742–3.
- [16] Lambeth L, Goyal A, Tadros A, Asadoorian M, Roberts AC, Karimi A. Peripherally inserted central catheter tip malposition caused by power contrast medium injection. *J Vasc Interv Radiol* 2012;23(7):981–3.
- [17] Gibson F, Bodenham A. Mislplaced central venous catheters: applied anatomy and practical management. *Br J Anaesth* 2013;110(3):333–46.