



Maternal Zika Virus Infection in the First Trimester and Fetal Stigmata in the Third Trimester

Divya Singh¹ Ladbans Kaur¹

¹Department of Radio-diagnosis, Prime Imaging & Prenatal Diagnostics, Chandigarh, India

Address for correspondence Divya Singh, MD DNB, Department of Radio-diagnosis, Prime Imaging & Prenatal Diagnostics, Sector-24 D, Chandigarh 160023, India (e-mail: docdivyas@yahoo.co.in).

Indian J Radiol Imaging 2023;33:400–402.

Abstract

Zika is a flavivirus that is transmitted primarily by the bite of an infected Aedes mosquito. It can also be transmitted by blood transfusion, sexual contact, and from an infected mother to the unborn baby. Zika virus infection is of particular concern in pregnancy as transplacental transmission of the virus has the potential to cause significant fetal morbidity. Ultrasonography plays a pivotal role in the fetal surveillance of a pregnant woman infected with Zika. There have been outbreaks of Zika virus infection in various parts of India, the most recent occurring in Kanpur in November 2021. We report a case of a primigravida who had Zika virus infection during the first trimester of pregnancy but the fetus presented with the sequelae of infection in the third trimester. This report highlights the sonographic red flags for fetal Zika infection and the importance of serial monitoring in pregnant women exposed to Zika virus.

Keywords

- calcification
- fetus
- microcephaly
- ultrasonography
- Zika virus

Introduction

Zika virus was identified in a Rhesus monkey in Uganda in 1947.¹ Infection can remain asymptomatic or produce self-limiting symptoms like low-grade fever, rash, joint pain, and conjunctivitis.² It is of particular concern in pregnancy as it can cause significant fetal morbidity.³ There have been outbreaks of Zika in India, the most recent occurring in Kanpur in November 2021.^{4,5} In this article, we reported a case of a primigravida residing in Kanpur during the first trimester of pregnancy who had Zika virus infection in the first trimester and fetal sequelae manifested in the third trimester.

Case History

A 30-year-old primigravida presented at 32 weeks of gestation with fetal head and abdominal circumference below the 3rd centile and femur length at the 25th centile. She gave a history of fever with rashes on her arms at 8 weeks of

gestation while residing at Kanpur. Maternal TORCH profile was negative. Since there was an outbreak of Zika virus in Kanpur at that time, she underwent reverse-transcription polymerase chain reaction (RT-PCR) testing that confirmed Zika virus infection. Serial sonographic surveillance was advised in view of the potential teratogenic effects of maternal Zika infection in the first trimester of pregnancy. Sonograms at 12, 16, and 20 weeks were unremarkable. Sonogram at 28 weeks was suggestive of fetal growth restriction. Detailed evaluation at 32 weeks revealed fetal head circumference at two standard deviations below the mean. There was mild ventriculomegaly (►Fig. 1A). Multiple foci of calcification with subcortical distribution were seen in bilateral frontal and parietal regions (►Fig. 1B, C). The cerebral sulci were underdeveloped for 32 weeks with pachygyria (►Fig. 1). Rest of the fetal anatomy, liquor, and Dopplers were unremarkable. No teratogenic drug was consumed during the pregnancy. Based on confirmed maternal Zika virus

article published online
January 31, 2023

DOI <https://doi.org/10.1055/s-0043-1761254>.
ISSN 0971-3026.

© 2023. Indian Radiological Association. All rights reserved.

This is an open access article published by Thieme under the terms of the Creative Commons Attribution-NonDerivative-NonCommercial-License, permitting copying and reproduction so long as the original work is given appropriate credit. Contents may not be used for commercial purposes, or adapted, remixed, transformed or built upon. (<https://creativecommons.org/licenses/by-nc-nd/4.0/>)

Thieme Medical and Scientific Publishers Pvt. Ltd., A-12, 2nd Floor, Sector 2, Noida-201301 UP, India

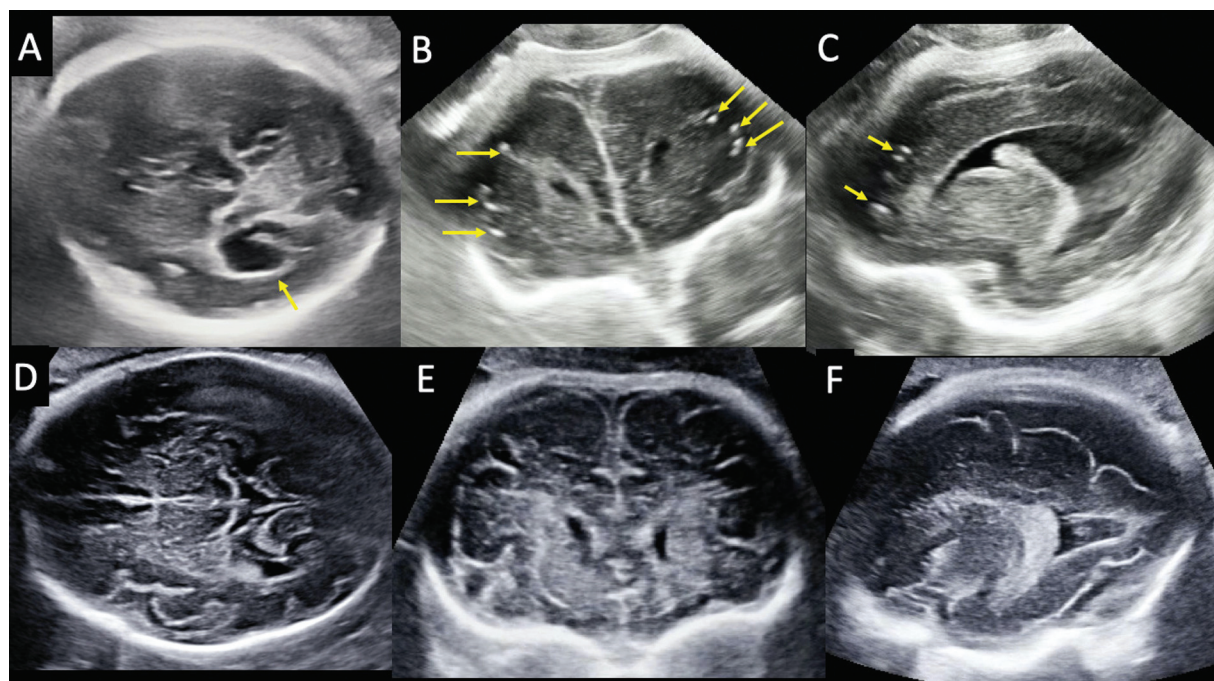


Fig. 1 Multiplanar neurosonogram of the fetus with Zika virus infection (A–C) and a normal fetus at 32 weeks (D–F). Axial image of the head (A) shows dilatation of the lateral ventricle (arrow) with paucity of cerebral sulci in comparison to the control (D). Coronal and parasagittal images (B, C) of the brain of the fetus with Zika virus infection show multiple foci of calcification (arrows) with a subcortical distribution in bilateral frontal and parietal lobes along with cerebral atrophy and paucity of sulci. Coronal and parasagittal images (E, F) of the control illustrate the normal cerebral volume and sulci at 32 weeks of gestation.

infection in the first trimester, the “femur-sparing” profile of growth restriction, and typical neurosonographic features, a diagnosis of fetal Zika virus infection was made. There was intrauterine demise of the fetus at 34 weeks.

Discussion

Zika is a flavivirus that is transmitted primarily by the bite of an infected *Aedes* mosquito. It can also be transmitted by blood transfusion, sexual contact, and transplacentally from an infected mother to the unborn baby.⁴ Studies have shown that nearly 10% of women with perinatal Zika virus infection have fetuses afflicted with congenital Zika virus syndrome (CZS).⁶ CZS encompasses a variety of abnormalities affecting the brain and eyes, arthrogryposis, and congenital deafness.^{7–9} The prenatal diagnosis of Zika infection is fraught with challenges. The mother is often asymptomatic. The virus has a transient presence in maternal blood and urine and there is normalization of the virus in amniotic fluid and fetal blood after some time, thereby providing a narrow window for detection by RT-PCR.¹⁰ Serological testing can result in false-positive and false-negative results. Ultrasonography is an inexpensive, safe, and widely available imaging tool for fetal surveillance in a pregnant woman exposed to Zika.

Zika virus infects the fetal neural progenitor cells preferentially leading to their apoptosis.¹¹ The salient neurosonographic pointers for fetal Zika virus infection include microcephaly, cerebral atrophy, ventriculomegaly, intracranial calcification, malformations of cortical development, abnormalities of corpus callosum, cerebellum, and brain stem.¹² Ventriculomegaly, though nonspecific, is one of the most common and earliest

signs.¹⁰ It can have two patterns: symmetric, moderate ventriculomegaly secondary to cerebral atrophy or asymmetric, severe ventriculomegaly along with brain stem calcification due to aqueduct stenosis.¹³ Intracranial calcifications are fine and arc shaped with a typical distribution at the gray–white matter junction.¹² They appear in the frontal lobe initially and become diffuse later. Periventricular calcification is less common.¹⁴ The extracranial sonographic findings of fetal Zika virus infection include a femur-sparing profile of growth restriction, limb contractures, and cataract.^{15,16} This case highlights the red flags for fetal Zika infection. It underscores the importance of serial fetal surveillance throughout pregnancy in women exposed to Zika virus infection as the sequelae can develop long after maternal infection.

Conflict of Interest

None declared.

References

- Dick GWA, Kitchen SF, Haddock AJ. Zika virus. I. Isolations and serological specificity. *Trans R Soc Trop Med Hyg* 1952;46(05): 509–520
- World Health Organization Zika virus disease: interim case definitions. World Health Organization 2016. Accessed January 9, 2023 at: <https://apps.who.int/iris/handle/10665/204381>
- Oliveira Melo AS, Malinger G, Ximenes R, Szejnfeld PO, Alves Sampaio S, Bispo de Filippis AM. Zika virus intrauterine infection causes fetal brain abnormality and microcephaly: tip of the iceberg? *Ultrasound Obstet Gynecol* 2016;47(01):6–7
- Sharma KA, Sahani B, Praveen TLN, et al. SFM interim practice recommendations for Zika virus infection in pregnancy. *J Foetal Med* 2021;8:257–266

- 5 Singh R, Gupta V, Malhotra B, et al. Cluster containment strategy: addressing Zika virus outbreak in Rajasthan, India. *BMJ Glob Health* 2019;4(05):e001383. Doi: 10.1136/bmjgh-2018-001383
- 6 Pomar L, Malinger G, Benoist G, et al. Association between Zika virus and fetopathy: a prospective cohort study in French Guiana. *Ultrasound Obstet Gynecol* 2017;49(06):729–736
- 7 Rasmussen SA, Jamieson DJ, Honein MA, Petersen LR. Zika virus and birth defects reviewing the evidence for causality. *N Engl J Med* 2016;374(20):1981–1987
- 8 Melo AS, Aguiar RS, Amorim MM, et al. Congenital Zika virus infection: beyond neonatal microcephaly. *JAMA Neurol* 2016;73(12):1407–1416
- 9 Valentine G, Marquez L, Pammi M. Zika-virus associated microcephaly and eye lesions in the newborn. *J Pediatric Infect Dis Soc* 2016;5(03):323–328
- 10 Schaub B, Gueneret M, Jolivet E, et al. Ultrasound imaging for identification of cerebral damage in congenital Zika virus syndrome: a case series. *Lancet Child Adolesc Health* 2017;1(01):45–55
- 11 Tang H, Hammack C, Ogden SC, et al. Zika virus infects human cortical neural progenitors and attenuates their growth. *Cell Stem Cell* 2016;18(05):587–590
- 12 Soares de Oliveira-Szejnfeld P, Levine D, Melo AS, et al. Congenital brain abnormalities and Zika virus: what the radiologist can expect to see prenatally and postnatally. *Radiology* 2016;281(01):203–218
- 13 Chimelli L, Melo ASO, Avvad-Portari E, et al. The spectrum of neuropathological changes associated with congenital Zika virus infection. *Acta Neuropathol* 2017;133(06):983–999
- 14 Vesnaver TV, Tul N, Mehrabi S, et al. Zika virus associated microcephaly/microencephaly-fetal brain imaging in comparison with neuropathology. *BJOG* 2017;124(03):521–525
- 15 Moore CA, Staples JE, Dobyns WB, et al. Characterizing the pattern of anomalies in congenital Zika syndrome for pediatric clinicians. *JAMA Pediatr* 2017;171(03):288–295
- 16 Walker CL, Ehinger N, Mason B, et al. Ultrasound prediction of Zika virus-associated congenital injury using the profile of fetal growth. *PLoS One* 2020;15(05):e0233023. Doi: 10.1371/journal.pone.0233023