

Received: 2020.08.31

Accepted: 2020.11.13

Available online: 2020.12.10

Published: 2020.12.31

Isolated Pulvinar/Hockey Stick Sign in Nonalcoholic Wernicke's Encephalopathy

Authors' Contribution:

Study Design A
Data Collection B
Statistical Analysis C
Data Interpretation D
Manuscript Preparation E
Literature Search F
Funds Collection G

ABCDEF 1,2 **Faisal Khan**
ABCDEF 3 **Neha Sharma**
ABCDEF 3 **Moin Ud Din**
CDE 4 **Vivek Bansal**

1 Department of Neurology, Sugar Land Neurology and Sleep, Sugar Land, TX, U.S.A.


2 Department of Neurology, Sam Houston University College of Osteopathic Medicine, Huntsville, TX, U.S.A.

3 Research Fellow, Houston Medical Clerkship, Sugar Land, TX, U.S.A.

4 Department of Neuroradiology, Radiology Partners Gulf Coast, Houston, TX, U.S.A.

Corresponding Author: Faisal Khan, e-mail: sugarlandneurologist@gmail.com**Conflict of interest:** None declared**Case series****Patients:** Female, 50-year-old • Female, 64-year-old**Final Diagnosis:** Wernicke-Korsakoff syndrome**Symptoms:** Altered mental status • ataxia • dizziness • horizontal nystagmus • nausea • vomiting**Medication:** —**Clinical Procedure:** Lumbar puncture**Specialty:** Neurology**Objective:** Mistake in diagnosis**Background:** Wernicke's encephalopathy (WE), a commonly misdiagnosed and underdiagnosed pathology, presents with altered mental status, ataxia, and ophthalmoplegia. WE is most commonly caused by excessive alcohol use, but also has diverse nonalcoholic etiologies. Here we describe 2 cases of nonalcoholic WE with different etiologies that were initially misdiagnosed due to lack of correlation of magnetic resonance imaging (MRI) findings with clinical information.**Case Reports:** Patient A, a 50-year-old woman with recent gastric sleeve surgery, presented with horizontal gaze-evoked nystagmus, ataxia, and altered mental status. MRI fluid-attenuated inversion recovery (FLAIR) revealed isolated bilateral, symmetrical, thalamic hyperintensities, initially diagnosed as variant Creutzfeldt-Jakob disease. A review of imaging and clinical presentation provided an alternate diagnosis of nonalcoholic WE secondary to nutritional deficiency. Intravenous (IV) thiamine improved symptoms with resolution of MRI findings 6 months later.

Patient B, a 64-year-old woman, presented with nausea, vomiting, dizziness, altered mental status, and weight loss. MRI FLAIR revealed isolated bilateral, symmetrical, thalamic hyperintensities, initially determined to be ischemia, prompting stroke management. A diagnosis of nonalcoholic WE was suggested, given the patient's low thiamine levels and history of malnutrition, and was confirmed by her excellent therapeutic response to IV thiamine.

Conclusions: Nonalcoholic WE remains a challenging diagnosis because of the variable clinical presentation, myriad of underlying etiologies, and lack of standardized diagnostic laboratory tests. A multidisciplinary approach with close collaboration between the radiologist and clinical care team is critical to narrow down the differential and initiate correct management. WE is a reversible disease with catastrophic consequences if it is not recognized and treated promptly.**MeSH Keywords:** Creutzfeldt-Jakob Syndrome • Pulvinar • Thalamic Nuclei • Thiamine Deficiency • Wernicke Encephalopathy**Full-text PDF:** <https://www.amjcaserep.com/abstract/index/idArt/928272>

2554




3



3



2



31



Background

Wernicke's encephalopathy (WE) poses a significant diagnostic challenge, especially when the patient does not have a history of alcohol use. The clinical triad of gait ataxia, ophthalmoplegia, and altered mental status is well established, though it lacks sensitivity (16%) [1,2]. The Caine criteria [3] (Table 1) has been developed to help make an early diagnosis, but a high index of clinical suspicion is still required [4]. Clinicians often rely on ancillary testing, especially neuroimaging, to narrow down the diagnostic possibilities. Magnetic resonance imaging (MRI) has low sensitivity (50%) but high specificity (93%), thus making it the most reliable confirmatory test [5]. However, patients with nonalcoholic WE present with highly variable neuroimaging findings, making the diagnosis even more challenging. In both of our patients, an isolated pulvinar/hockey stick sign was the sole radiological manifestation in the absence of other classic neuroimaging features. Awareness of these radiological signs with an appropriate clinical context is critical to formulate the appropriate differential diagnosis and avoid unnecessary testing and anxiety for the patient and family members.

Here we describe 2 cases of nonalcoholic WE with different etiologies, both of which were initially misdiagnosed because of lack of correlation of MRI findings with clinical information.

Table 1. Caine criteria.

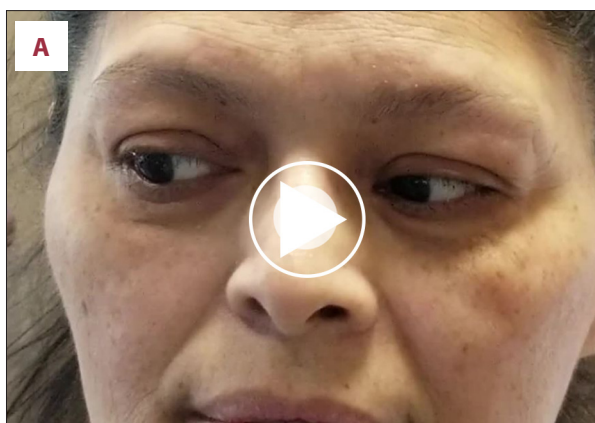
1. Dietary deficiency
2. Eye signs (nystagmus, ophthalmoplegia)
3. Cerebellar dysfunction (ataxia)
4. Altered mental status or mild memory impairment

Must have 2 of 4 signs to diagnose Wernicke's encephalopathy.

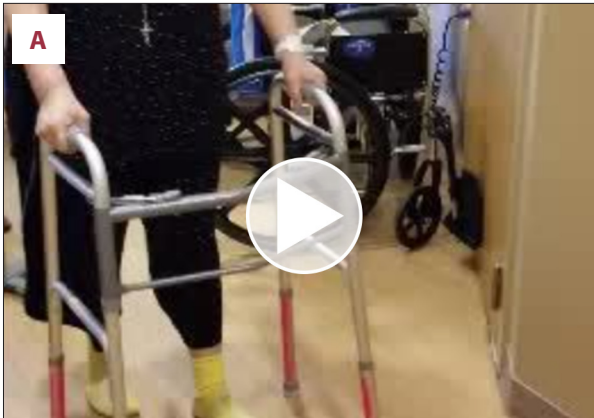
Case Reports

Patient A

Patient A, a 50-year-old woman with a history of morbid obesity, gastric sleeve surgery (GSS) 3 months prior, and cholecystectomy 2 months prior presented with horizontal gaze-evoked nystagmus, ataxia, and altered mental status (Videos 1A, 2A). She reported no history of drug or alcohol abuse. Lab workup revealed the following results: white blood cell (WBC) count 11, hemoglobin (Hb) 16.3, platelets 346, sodium 152, glucose 109, lactate 4.5, aspartate transaminase (AST) 54, alanine aminotransferase (ALT) 95, albumin 4.5, creatinine 1.1, blood urea nitrogen (BUN) 16, thyroid stimulating hormone (TSH) 3.09, B₁₂ 975, ammonia 29, copper 108, and zinc 102. Antidouble stranded DNA, anti-RNP, and anti-Smith antibody panels were negative. The thiamine level for this patient was not available because of hospital policy. Analysis of cerebrospinal fluid (CSF) revealed no pleocytosis, glucose 53, or protein 113 and was positive for oligoclonal bands and negative for syphilis. An electroencephalogram (EEG) showed mild diffuse slowing (7Hz) intermixed with low-voltage fast activity, signifying mild encephalopathy. A computed tomography (CT) scan did not show any signs of acute intracranial abnormalities. MRI fluid-attenuated inversion recovery (FLAIR) revealed isolated bilateral symmetrical thalamic hyperintensities (pulvinar/double hockey stick sign) (Figure 1A), without diffusion restriction. No contrast enhancement was seen on gadolinium T1-weighted imaging and on FLAIR sequencing, white matter hyperintensities potentially reflecting chronic microvascular disease were seen (Figure 1B). No signal changes were seen in the mammillary bodies, the wall of the third ventricle, periaqueductal gray matter, floor of the fourth ventricle, or the tectal plate. The radiologist raised the possibility of variant Creutzfeldt-Jakob disease (vCJD), given the isolated finding of pulvinar/hockey stick sign. Magnetic resonance angiography of the head and neck did not reveal stenosis or vascular malformations.



Video 1. (A) Patient A, presenting with horizontal gaze-evoked nystagmus. (B) After thiamine treatment, Patient A's horizontal gaze-evoked nystagmus has resolved.



Video 2. (A) Patient A, presenting with gait ataxia. (B) After thiamine treatment, Patient A's gait ataxia has resolved.

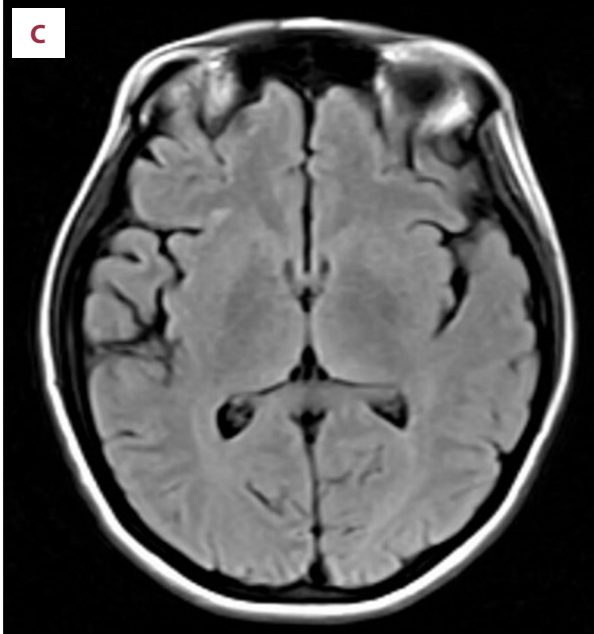
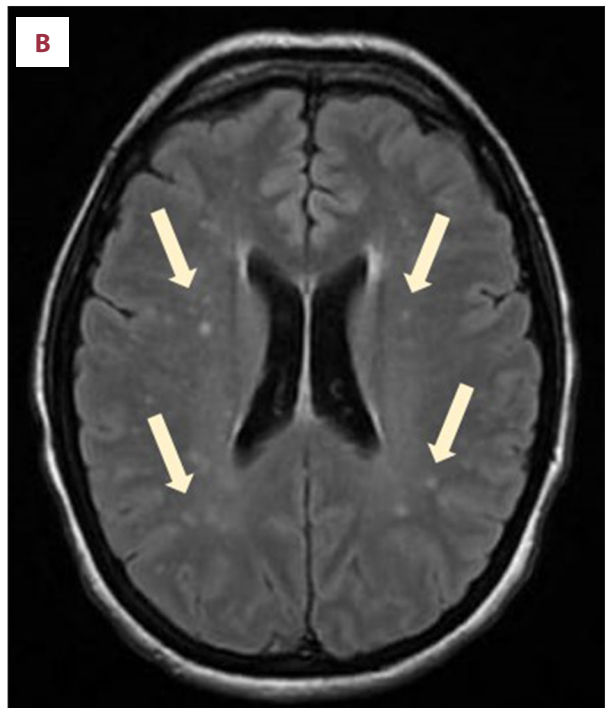
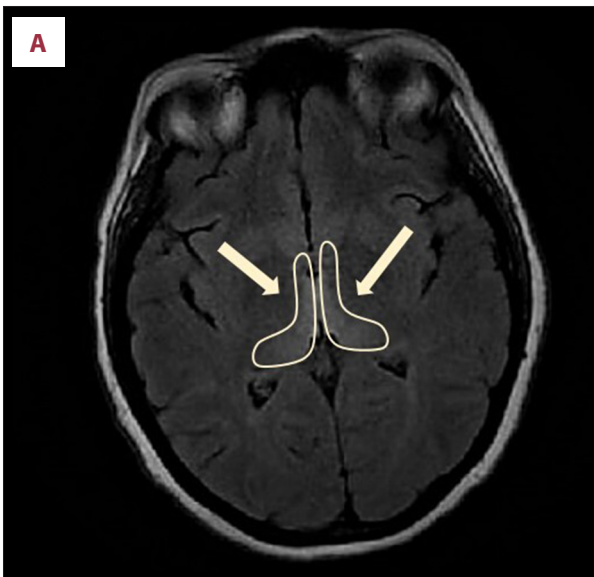


Figure 1. (A) Patient A. Magnetic resonance imaging T2- fluid-attenuated inversion recovery reveals hyperintensities involving the pulvinar and dorsomedial nuclei of the thalamus, which form a double hockey stick sign in nonalcoholic Wernicke's encephalopathy. (B) Magnetic resonance imaging T2- fluid-attenuated inversion recovery reveals minimal white matter hyperintensities, potentially reflecting chronic microvascular changes in Patient A. (C) After parenteral thiamine, magnetic resonance imaging T2- fluid-attenuated inversion recovery reveals normal thalamic nuclei in Patient A.

The patient was started empirically on IV thiamine (500 mg TID). Her horizontal gaze-evoked nystagmus improved within 2 to 3 days. The mild encephalopathy resolved within 4 to 5 days and she returned to her normal cognitive baseline. The patients' gait remained ataxic, but she was able to ambulate with a walker while working with a physical therapist. A diagnosis was made of nonalcoholic WE due to nutritional deficiency (secondary to GSS). The diagnosis was supported by clinical improvement following initiation of parenteral thiamine. Further insight into the history revealed that the patient was prescribed oral vitamin supplementation but was noncompliant. vCJD was ruled out with a negative CSF real-time quaking-induced conversion assay. She was discharged to an inpatient rehabilitation facility on high-dose IV thiamine (500 mg TID) for persistent ataxic symptoms. Her gait continued to improve with intensive physical therapy. She was discharged home, and due to her increased risk of chronic thiamine deficiency, was given a lifelong prescription for thiamine supplementation (100 mg/d orally). Three months later, follow-up at an outpatient neurology clinic revealed drastic clinical improvement with resolution of nystagmus and ataxia (Videos 1B, 2B). The patient's thiamine level was measured and found to be within the therapeutic range (171.8 nmol/L). An outpatient MRI done 6 months after that revealed resolution of the thalamic FLAIR abnormality/hockey stick sign (Figure 1C).

Patient B

Patient B is a 64-year-old woman with a history of hypertension, rheumatoid arthritis, and primary hyperparathyroidism status post parathyroidectomy who presented with nausea, vomiting, dizziness, altered mental status, and weight loss. Over the past few weeks, she had been exposed to insecticides and bug sprays that were used to try to eradicate a bed bug infestation and she did not connect this exposure with her symptoms. She reported no history of drug or alcohol abuse. Lab workup revealed the following results: WBC 6.1, Hb 13.9, platelets 119, international normalized ratio 1.3, sodium 153, glucose 90, creatinine 1.7, BUN 31, AST 60, ALT 42, albumin 2.8, TSH 2.090, B₁₂ 2496, ammonia 37, copper 86, zinc 66, and thiamine <7. An EEG showed 7Hz diffuse slowing, signifying mild encephalopathy, with no epileptic discharges. A CT scan showed no acute intracranial abnormalities. MRI FLAIR revealed isolated bilateral symmetrical thalamic hyperintensities. Diffusion-weighted imaging did not show any restricted diffusion. No contrast enhancement was seen on a gadolinium chelate-enhanced T1-weighted image. No signal changes were seen in the mammillary bodies, tectal plate, wall of the third ventricle, periaqueductal gray matter, or the floor of the fourth ventricle. Ischemic changes (artery of Percheron stroke) were originally suggested in the differential, but on review by a neuroradiologist, the symmetrical thalamic hyperintensities were recognized as the hockey stick sign (Figure 2). A diagnosis

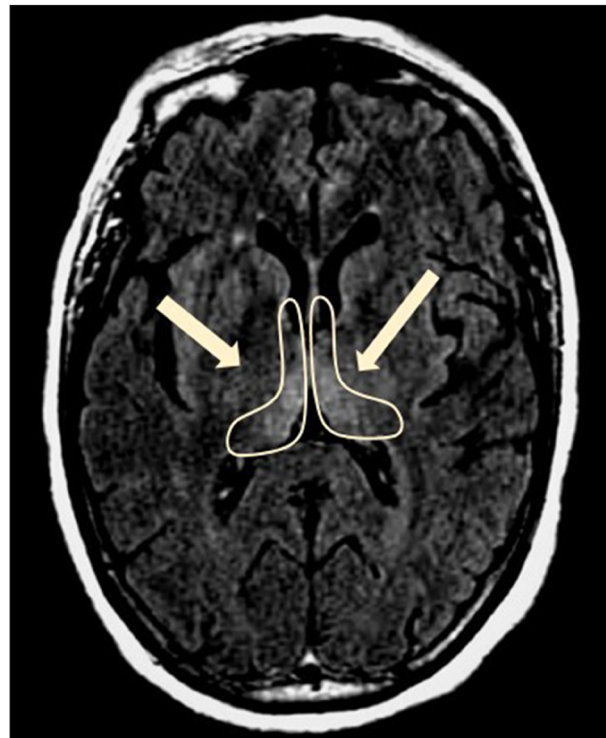


Figure 2. In Patient B, magnetic resonance imaging T2- fluid-attenuated inversion recovery reveals hyperintensities involving the pulvinar and dorsomedial nuclei of the thalamus, forming a double hockey stick sign in nonalcoholic Wernicke's encephalopathy.

of nonalcoholic WE was considered, given the patient's history of malnutrition, significant weight loss with low thiamine levels, and radiological findings. She was started empirically on IV thiamine (500 mg TID), and within 2 to 3 days, her altered mental status and dizziness dramatically improved. She was discharged home within 3 days, on a regimen of oral thiamine (100 mg/d). Unfortunately, no post-treatment thiamine levels or neuroimaging were available because the patient was lost to follow-up.

Discussion

A broad differential diagnosis needs to be considered when a patient presents with rapidly progressive cognitive impairment. These include infection (HSV-1, Whipple disease), metabolic syndromes (thiamine deficiency, hypothyroidism), autoimmune conditions (Hashimoto's thyroiditis, anti-VGKC encephalitis), vascular disorders (artery of Percheron stroke, top of the basilar artery syndrome), neurodegenerative conditions (CJD), and neoplastic etiologies (glioblastoma multiforme and cerebral metastases) [6,7]. A patient's clinical features, associated laboratory findings and radiological markers serve as diagnostic clues. In our cases, predisposing factors and accompanying

Table 2. Nonalcoholic etiologies of Wernicke's encephalopathy.

Malnutrition (anorexia nervosa, poverty, homelessness, old age, parenteral therapy)
Postoperative complication of gastric bypass surgeries (gastrectomy/duodenectomy)
Systemic diseases (AIDS, Crohn's disease)
Hyperemesis gravidarum
Tumors (gastrointestinal, leukemia)
Chemotherapy
Chronic uremia and hemodialysis
Burns

features of ataxia, horizontal gaze-evoked nystagmus, and altered mental status, plus presence of a pulvinar/double hockey stick sign were suggestive of nonalcoholic WE. The diagnosis was confirmed with an excellent therapeutic response to parenteral thiamine and resolution of radiological signs.

WE is reversible and commonly misdiagnosed because of underrecognition of nonalcoholic etiologies [8]. It has a male predominance, with a female-to-male ratio of 1: 1.7 [9]. Excessive alcohol use remains the most common etiology of WE, with Wernicke-Korsakoff syndrome being prevalent in 12.5% of alcohol abusers [10]. Nonalcoholic etiologies (Table 2) are increasingly being recognized.

GSS is increasingly becoming the preferred restrictive bariatric procedure for morbid obesity, given that success rates are higher compared to malabsorptive surgeries such as Roux-en-Y gastric bypass and the side effects are minimal [11,12]. The incidence of chronic thiamine deficiency associated with malabsorptive procedures is 49%, as compared to 18.75% for GSS [11,13]. The classic WE triad (ophthalmoplegia, ataxia, and encephalopathy), is seen in a substantially higher percentage of patients (54.2%) after bariatric surgery than with an alcoholic etiology (16%) [1,2,12,13]. This was also seen in our Patient A, who presented with the classic WE triad after undergoing GSS.

Patients with GSS have lower thiamine levels owing to multiple factors. GSS results in decreased hydrochloric acid production [14], which affects absorption of water-soluble vitamins such as thiamine in the proximal small intestine [15]. Furthermore, GSS involves removal of the fundus and corpus, which contain the interstitial cells of Cajal that are responsible for controlling stomach motility [14]. Resection of these segments induces pathological hypermotility, thus affecting nutrient absorption and contributing to thiamine deficiency [14]. In addition, lack of insight into the risk of developing WE, along with inadequate nutritional education, leads

to 10.3% of post-bariatric surgery patients being noncompliant with oral vitamin supplementation [12]. Persistent vomiting (87.3%) is the most common postoperative cause of WE and physicians should be conscious of this correlation and supplement with thiamine via the parenteral route [11–13]. Our Patient A, however, did not experience postoperative emesis

The European Federation of Neurological Societies and the Royal College of Physicians have recommended IV thiamine (500 mg TID) for acute treatment until WE symptoms resolve [12]. The American Society for Metabolic and Bariatric Surgery states that patients who have undergone bariatric surgery should receive supplemental IV thiamine 200 mg TID to 500 mg QD/BID for 3 to 5 days, followed by 250 mg/d for 3 to 5 days or until symptoms resolve [16]. Then consider treatment with 100 mg/d orally, until risk factors resolve, although usually, indefinite treatment is required [16]. However, there is no consensus as to the ideal dosage and duration of thiamine supplementation [17].

Patient B's nutritional deficiency was due to long-term exposure to insecticides (3 weeks), which induced persistent vomiting with a consequent loss of thiamine storage. We hypothesize that her sex and a potentially low thiamine level (before exposure to insecticides) may have contributed to the onset of WE. Women are at risk of losing thiamine stores at a higher rate than men [12]. In addition, it is imperative for physicians to know that individuals with low body weight are also at risk of easily losing thiamine stores [12].

Clinical features of WE can be correlated with lesions seen on MRI. Involvement of the brainstem cranial nerve nuclei (III & VI), cerebellar vermis and vestibular nuclei, midline reticular activating system of the thalamus and mammillary bodies correlates with presentation of ophthalmoplegia, ataxia, and altered mental status, respectively [5]. The radiological findings associated with mental status changes can be seen as isolated features on MRI [12], whereas regions corresponding to vestibular and ocular symptoms can be subradiographic, as noticed in both of our patients [12,18]. The most prevalent sign of thiamine deficiency is horizontal gaze-evoked nystagmus [18–21]. Brainstem nuclei are highly susceptible to thiamine deficiency due to higher metabolic demand and disruption of the blood-brain barrier [1,2,19]. This contributes to the development of horizontal gaze-evoked nystagmus as the earliest manifestation of WE [19–21]. Late signs such as altered mental status (memory impairment, delirium, coma) occur when diencephalic and cortical neurons are affected [19]. Caine's criteria of dietary deficiency along with horizontal gaze-evoked nystagmus and ataxia should be recognized as early manifestations of WE, whereas encephalopathy is identified as a late clinical sign [3,18,19].

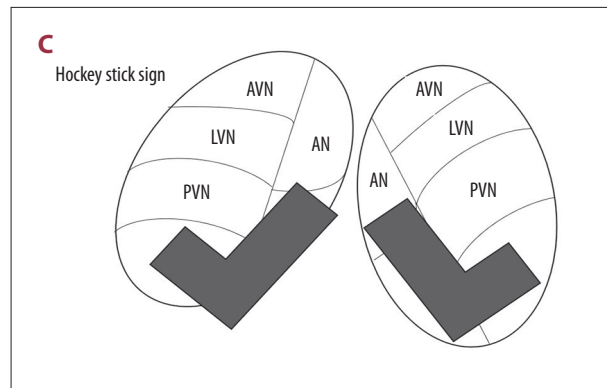
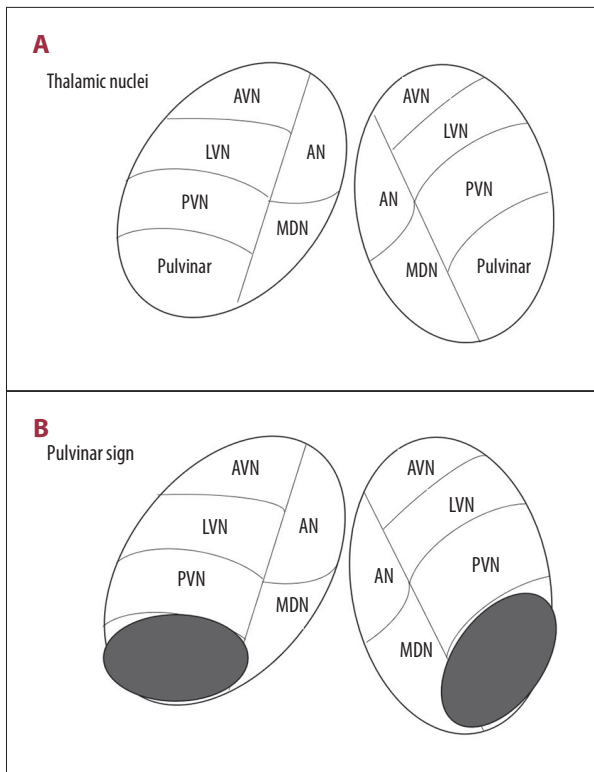


Figure 3. (A) Illustration of the thalamic nuclei. (B) Illustration of the thalamic nuclei depicting the pulvinar sign. (C) Illustration of the thalamic nuclei depicting the hockey stick sign.

Thiamine deficiency is the cornerstone pathological mechanism of WE. Patients who have a deficiency for more than 17 days require exogenous thiamine supplementation [19], while 4 or more weeks of deficiency leads to the onset of WE symptoms [2]. Patient A started to experience symptoms approximately 2 months post-GSS. Patient B presented with WE symptoms secondary to 3 to 4 weeks of continuous exposure to insecticides and intractable nausea and vomiting. Thiamine is involved in multiple biochemical pathways that affect production of adenosine triphosphate (ATP), such as the Krebs cycle and the pentose phosphate pathway [22]. ATP deficiency causes cytotoxic or vasogenic edema while pyruvate accumulation leads to lactic acidosis in susceptible areas in the brain [22]. These include the medial thalami (85%), third ventricle (80%), periaqueductal gray matter (59%), mammillary bodies (45%), and the tectal plate (36%). Less commonly affected areas include the cranial nerve nuclei (18%), periventricular gray matter anterior to the fourth ventricle (7%), cerebellum (5%), vermis (4%), dentate nuclei (1.8%), and the precentral and postcentral cortices (1.8%) [1,2,5,23]. However, in both of our cases, the medial thalami were the only structures involved, thus adding to the diagnostic dilemma.

The thalamus acts as a relay center for sensorineural pathways and is divided into different nuclei (Figure 3A). The pulvinar nucleus is the largest and plays a role in visual attention and modification of behavioral responses [24,25]. The dorsomedial nucleus, the largest medial nucleus, is involved in memory,

learning, and other cognitive functions [25]. The pulvinar sign is defined as a symmetrical hyperintensity of only the pulvinar thalamic nuclei (Figure 3B). A hockey stick sign is defined as concurrent symmetric hyperintensity of the dorsomedial thalami and pulvinar nuclei (Figure 3C). Pulvinar/hockey stick signs have high specificity for vCJD [26] but can be seen in various other pathologies (Table 3). Appropriate identification of these signs on MRI in combination with a patient's clinical presentation is critical for appropriate diagnosis and treatment [23]. Patient A was diagnosed with vCJD because of the isolated pulvinar sign. This caused panic for her family and could have delayed therapeutic intervention. Patient B initially had a differential diagnosis of ischemic changes on MRI, which resulted in initiation of a stroke management pathway.

Left untreated, WE is potentially life-threatening, with a mortality rate up to 20% [7,17]. It can proceed to irreversible Korsakoff syndrome, characterized by severe global amnesia (retrograde, anterograde, episodic) and confabulation [12,27]. Chronic thiamine deficiency also can lead to several different types of beriberi (cardiac and neuropathic). Although cardiac (systolic heart failure) and neuropathic (axonal sensory polyneuropathy) beriberi classically occur chronically, the latter can present acutely with flaccid paralysis mimicking acute inflammatory demyelinating polyneuropathy [28]. Shoshin beriberi, a subtype of cardiac beriberi, presents as severe refractory hypotension, tachycardia, hypothermia, leukocytosis, acute kidney injury, and lactic acidosis, leading to acute cardiovascular collapse, as described by Tan et al. [17,29].

We recognize that our report has a few limitations. Thiamine levels were not measured during Patient A's hospital course. Testing for thiamine largely depends upon institutional policies. Measurement of serum thiamine is not widely available due to lack of standardization and has a poor correlation with clinical symptomatology [30]; thus, diagnosing WE is even

Table 3. Diseases with MRI findings that reveal a pulvinar sign.

MRI T2-FLAIR hyperintensity	Pathology
Metabolic	Nonalcoholic Wernicke's encephalopathy
	Osmotic myelinolysis
Infectious	Variant Creutzfeldt-Jakob disease
	Cytomegalovirus
	Cat-scratch disease
	HIV
	Post-infectious encephalitis
	West Nile virus
	Rabies virus
	Cerebral malaria (<i>Plasmodium falciparum</i>)
	Thalamic abscess (toxoplasmosis)
	Japanese encephalitis
Vascular	Artery of Percheron stroke
	Deep cerebral vein thrombosis
	Posterior reversible encephalopathy
	Top of the basilar artery syndrome
Autoimmune	Acute disseminated encephalomyelitis
	Neurosarcoidosis
	Vacuolar leukoencephalopathy (celiac disease)
	Paraneoplastic limbic encephalitis (non-Hodgkin lymphoma)
Genetic	Alpers disease
	Leigh syndrome
Neoplastic	Bilateral thalamic gliomas
MRI T1 hyperintensity	Fabry disease
	Krabbe disease
	Profound hypoxia of the newborn
	Fahr disease
DWI hyperintensity	Mesial temporal lobe epilepsy (status epilepticus)

MRI – magnetic resonance imaging; DWI – diffusion-weighted imaging.

more challenging. Another limitation to diagnosis of WE in both of our patients was an oversight in performing the head impulse test. This test signifies damage to the brainstem nuclei (nucleus prepositus hypoglossi and medial vestibular nucleus) [18,19]. Loss of bilateral horizontal vestibulo-ocular reflex (VOR) with intact vertical VOR has been proposed to be a highly specific predictor of WE [18]. It is important to note that covert saccades are difficult to visualize on physical examination; therefore, the video head impulse test has been developed to ease diagnosis [31].

Conclusions

Nonalcoholic WE remains a challenging diagnosis because of its diverse clinical presentations, myriad underlying etiologies, and a lack of standardized diagnostic laboratory tests. As reported, approximately 80% of cases of nonalcoholic WE are recognized only at autopsy [27]. MRI signs in conjunction with clinical context can help clinicians make the correct diagnosis promptly and initiate appropriate management. Clinicians and radiologists should be aware of the fact that isolated involvement of the medial thalami (pulvinar/hockey stick sign) can be the sole manifestation of WE. Therefore, prompt administration of high-dose parenteral thiamine is required to

avoid permanent neurological sequelae. A multidisciplinary approach with close collaboration between the radiologist and the clinical care team is critical to narrow the differential diagnosis and initiate the correct management.

References:

1. Narra R, Jehendran M, Kamaraju S: Wernicke's encephalopathy: MRI features. *Int J Anat Radiol Surg*, 2015; 4(2): 14–15
2. Zucconi G, Santa Cruz D, Bertolini M et al: MR imaging findings in 56 patients with Wernicke encephalopathy: Nonalcoholics may differ from alcoholics. *Am J Neuroradiol*, 2009; 30(1): 171–76
3. Caine D, Halliday GM, Kril JJ et al: Operational criteria for the classification of chronic alcoholics: Ddentification of Wernicke's encephalopathy. *J Neurol Neurosurg Psychiatry*, 1997; 62(1): 51–60
4. Jan K: Wernicke encephalopathy: (MRI) picture worth a thousand words. *Oxf Med Case Reports*, 2018; 2018(5): omy013
5. Ota Y, Capizzano AA, Moritani T et al: Comprehensive review of Wernicke encephalopathy: Pathophysiology, clinical symptoms and imaging findings. *Jpn J Radiol*, 2020; 38(9): 809–20
6. Geschwind MD, Shu H, Haman A et al: Rapidly progressive dementia. *Ann Neurol*, 2008; 64(1): 97–108
7. Sechi G, Serra A: Wernicke's encephalopathy: New clinical settings and recent advances in diagnosis and management. *Lancet Neurol*, 2007; 6(5): 442–55
8. Aminoff M: *Neurology and general medicine*. New York: Churchill Livingstone, 2008; 280–81
9. Vasan S, Kumar A: Wernicke encephalopathy. 2020. In: *StatPearls* [Internet]. Treasure Island (FL): StatPearls Publishing, 2020
10. Flynn A, Macaluso M, D'Empaire I et al: Wernicke's encephalopathy: Increasing clinician awareness of this serious, enigmatic, yet treatable disease. *Prim Care Companion CNS Disord*, 2015; 17(3): 10.4088/PCC.14r01738
11. Milone M, Di Minno MN, Lupoli R et al: Wernicke encephalopathy in subjects undergoing restrictive weight loss surgery: A systematic review of literature data. *Eur Eat Disord Rev*, 2014; 22(4): 223–29
12. Oudman E, Wijnia JW, van Dam M et al: Preventing Wernicke encephalopathy after bariatric surgery. *Obes Surg*, 2018; 28(7): 2060–68
13. Truong J, Shalchian S, Myressiotis S et al: About a case of Wernicke's encephalopathy after sleeve gastrectomy. *Eat Weight Disord*, 2016; 21(4): 721–23
14. Csendes A, Braghetto I: Changes in the anatomy and physiology of the distal esophagus and stomach after sleeve gastrectomy. *J Obes Weight Loss Ther*, 2016; Corpus ID: 58890192
15. Said HM, Nexo E: Gastrointestinal handling of water-soluble vitamins. *Compr Physiol*, 2018; 8(4): 1291–311
16. Parrott J, Frank L, Rabena R et al: American Society for Metabolic and Bariatric Surgery Integrated Health Nutritional Guidelines for the Surgical Weight Loss Patient 2016 Update: Micronutrients. *Surg Obes Relat Dis*, 2017; 13(5): 727–41
17. Tan TXZ, Lim KC, Chan Chung C et al: Starvation-induced diplopia and weakness: A case of beriberi and Wernicke's encephalopathy. *BMJ Case Rep*, 2019; 12(1): e227412
18. Kattah JC, Dhanani SS, Pula JH et al: Vestibular signs of thiamine deficiency during the early phase of suspected Wernicke encephalopathy. *Neurol Clin Pract*, 2013; 3(6): 460–68
19. Kattah JC: Early signs of thiamine deficiency: A case report. *Ann Intern Med*, 2020; 173(1): 72–73
20. De Wardener H, Lennox B: Cerebral Beriberi (Wernicke's encephalopathy); Review of 52 cases in Singapore prisoner-of-war hospital. *Lancet*, 1947; 249(6436): 11–17
21. Victor M, Adams R, Collins G: *The Wernicke-Korsakoff syndrome*. 1st ed. Philadelphia: F.A. Davis, 1971
22. Manzo G, De Gennaro A, Cozzolino A et al: MR imaging findings in alcoholic and nonalcoholic acute Wernicke's encephalopathy: A review. *Biomed Res Int*, 2014; 2014: 503596
23. Yin H, Xu Q, Cao Y et al: Nonalcoholic Wernicke's encephalopathy: A retrospective study of 17 cases. *J Int Med Res*, 2019; 47(10): 4886–94
24. Benarroch EE: Pulvinar: Associative role in cortical function and clinical correlations. *Neurology*, 2015; 84(7): 738–47
25. Linn J, Hoffmann LA, Danek A et al: [Differential diagnosis of bilateral thalamic lesions]. *Rofo*, 2007; 179(3): 234–45 [in German]
26. Collie DA, Summers DM, Sellar RJ et al: Diagnosing variant Creutzfeldt-Jakob disease with the pulvinar sign: MR imaging findings in 86 neuropathologically confirmed cases. *AJNR Am J Neuroradiol*, 2003; 24(8): 1560–69
27. Covell T, Siddiqui W: Korsakoff Syndrome. 2020 Jul 10. In: *StatPearls* [Internet]. Treasure Island (FL): StatPearls Publishing; 2020
28. Mantero V, Rifino N, Costantino G et al: Non-alcoholic beriberi, Wernicke encephalopathy and long-term eating disorder: Case report and a mini-review. *Eat Weight Disord*, 2020 [Online ahead of print]
29. Dabar G, Harmouche C, Habr B et al: Shoshin beriberi in critically-ill patients: Case series. *Nutr J*, 2015; 14: 51
30. Whitfield KC, Bourassa MW, Adamolekun B et al: Thiamine deficiency disorders: Diagnosis, prevalence, and a roadmap for global control programs. *Ann NY Acad Sci*, 2018; 1430(1): 3–43
31. MacDougall HG, Weber KP, McGarvie LA et al: The video head impulse test: Diagnostic accuracy in peripheral vestibulopathy. *Neurology*, 2009; 73(14): 1134–41

Conflict of interest

None.