

The different association of allocentric and egocentric neglect with dorsal and ventral pathways

A case report

Sung Ho Jang, MD^a, Woo Hyuk Jang, PhD^{b,*}

Abstract

Rationale: Egocentric neglect is characterized by responses missing on the contralateral side with respect to the viewer, while allocentric neglect is characterized in responses missing on the contralateral side with respect to the object. However, little has been reported about the neural tracts associated with egocentric and allocentric neglect. We investigated which neural tracts were involved in two types of neglect (egocentric and allocentric) in a stroke patient who showed allocentric neglect by using the Apple Cancellation test, a specialized test to distinguish between egocentric and allocentric neglect.

Patient concerns: He showed good cognitive function but presented with severe neglect on the left side (A 42-year-old, right-handed male patient). He was unable to undergo even the pencil and paper test for evaluation of the severity of neglect.

Diagnoses: He was diagnosed as spontaneous intracerebral hemorrhage at the right basal ganglia and underwent conservative management at the neurosurgery department of a university hospital.

Interventions: Two weeks after onset, he began rehabilitation at the rehabilitation department of the same university hospital. During a seven month rehabilitation, the patient showed significant improvement of his severe left neglect.

Outcomes: We used the Apple Cancellation test to distinguish between egocentric and allocentric neglect; the results failed to reveal egocentric neglect, however, they did reveal severe allocentric neglect. In addition, on diffusion tensor tractography (DTT) at 2 weeks after onset, the right superior longitudinal fasciculus (SLF) showed partial injury and narrowing in the parietal lobe compared to that of the left SLF. In addition, the right inferior fronto-occipital fasciculus (IFOF) was not reconstructed. By contrast, on 7-month post-onset DTT, the right SLF revealed elongation and thickening in the parietal lobe that approached similarity to that for the left SLF. However, the right IFOF was still not reconstructed.

Lessons: The associations of egocentric neglect with the dorsal pathway (SLF) and the association of allocentric neglect with the ventral pathway (IFOF) in the right hemisphere were demonstrated in a stroke patient. It appears that DTT can be helpful in demonstrating both the affected pathway and the neglect type in patients with neglect.

Abbreviations: CST = corticospinal tract, DTI = diffusion tensor imaging, DTT = diffusion tensor tractography, EPI = echo planar imaging, FA = fractional anisotropy, IFOF = inferior fronto-occipital fasciculus, NEX = number of excitations, ROIs = regions of interest, SLF = superior longitudinal fasciculus, TE = echo time, TR = repetition time.

Keywords: apple cancellation test, diffusion tensor tractography, inferior fronto-occipital fasciculus, neglect, superior longitudinal fasciculus

Editor: Woo Hyuk Jang.

This work was supported by the DGIST R&D Program of the Ministry of Science, ICT and Future Planning (18-BD-0401).

The authors have no conflicts of interest to disclose.

^a Department of Physical Medicine and Rehabilitation, College of Medicine, Yeungnam University, Daemyung-dong, Nam-ku, Daegu, ^b Department of Occupational Therapy, College of Health Science, Kangwon National University, Hwangjo-gil, Dogye-eup, Samcheok-si, Gangwon-do, Republic of Korea.

* Correspondence: Woo Hyuk Jang, Department of Occupational Therapy, College of Health Science, Kangwon National University, 346, Hwangjo-gil, Dogye-eup, Samcheok-si, Gangwon-do 25949, Republic of Korea (e-mail: wlqtksek@hanmail.net).

Copyright © 2018 the Author(s). Published by Wolters Kluwer Health, Inc. This is an open access article distributed under the terms of the Creative Commons Attribution-Non Commercial-No Derivatives License 4.0 (CCBY-NC-ND), where it is permissible to download and share the work provided it is properly cited. The work cannot be changed in any way or used commercially without permission from the journal.

Medicine (2018) 97:37(e12394)

Received: 8 May 2018 / Accepted: 23 August 2018

<http://dx.doi.org/10.1097/MD.00000000000012394>

1. Introduction

Neglect is a common sequela in which there is failure to attend to stimuli presented on the contralateral side after right hemisphere injury, and neglect is classified into 2 types: egocentric and allocentric.^[1,2] Egocentric neglect is characterized by responses missing on the contralateral side with respect to the viewer (subject-centered), while allocentric neglect is characterized in responses missing on the contralateral side with respect to the object (object-centered).^[3]

The spatial coding system is reported to consist of a dorsal visual pathway (the “where” pathway) and the ventral visual pathway (the “what” pathway).^[4] Several previous studies have demonstrated that various neural tracts including the 2 above-mentioned pathways are involved in neglect.^[5–10] Furthermore, some studies have suggested that egocentric and allocentric neglect types are closely related to the dorsal and ventral visual pathways, respectively.^[4,11] The recently developed diffusion tensor tractography (DTT) method, results of which are reconstructed from diffusion tensor imaging (DTI) data, have allowed reconstruction

of the neural tracts in the spatial coding system that are related with neglect; that is, the superior longitudinal fasciculus (SLF) in the dorsal visual pathway and the inferior fronto-occipital fasciculus (IFOF) in the ventral visual pathway.^[12–16] Recently, a patient who exhibited allocentric neglect due to injury of the IFOF was reported.^[17] However, little has been reported about the neural tracts associated with egocentric and allocentric.

In this study, we investigated which neural tracts were involved in 2 types of neglect (egocentric and allocentric) in a stroke patient by using the Apple Cancellation test, which is reported to be specialized for distinguishing between egocentric and allocentric neglect.^[5,18]

2. Case report

A 42-year-old, right-handed male patient was diagnosed as spontaneous intracerebral hemorrhage at the right basal ganglia and underwent conservative management at the neurosurgery department of a university hospital (Fig. 1A and B). At 2 weeks after onset, he began rehabilitation at the rehabilitation department of the same university hospital. He presented with severe weakness of the left upper and lower extremities and could move only proximal parts of the left shoulder and hip joint (Manual Muscle Test result=2).^[19] He showed good cognitive function (Mini-Mental State Examination score=29 [full score=30]).^[20] However, he presented with severe neglect in the left side

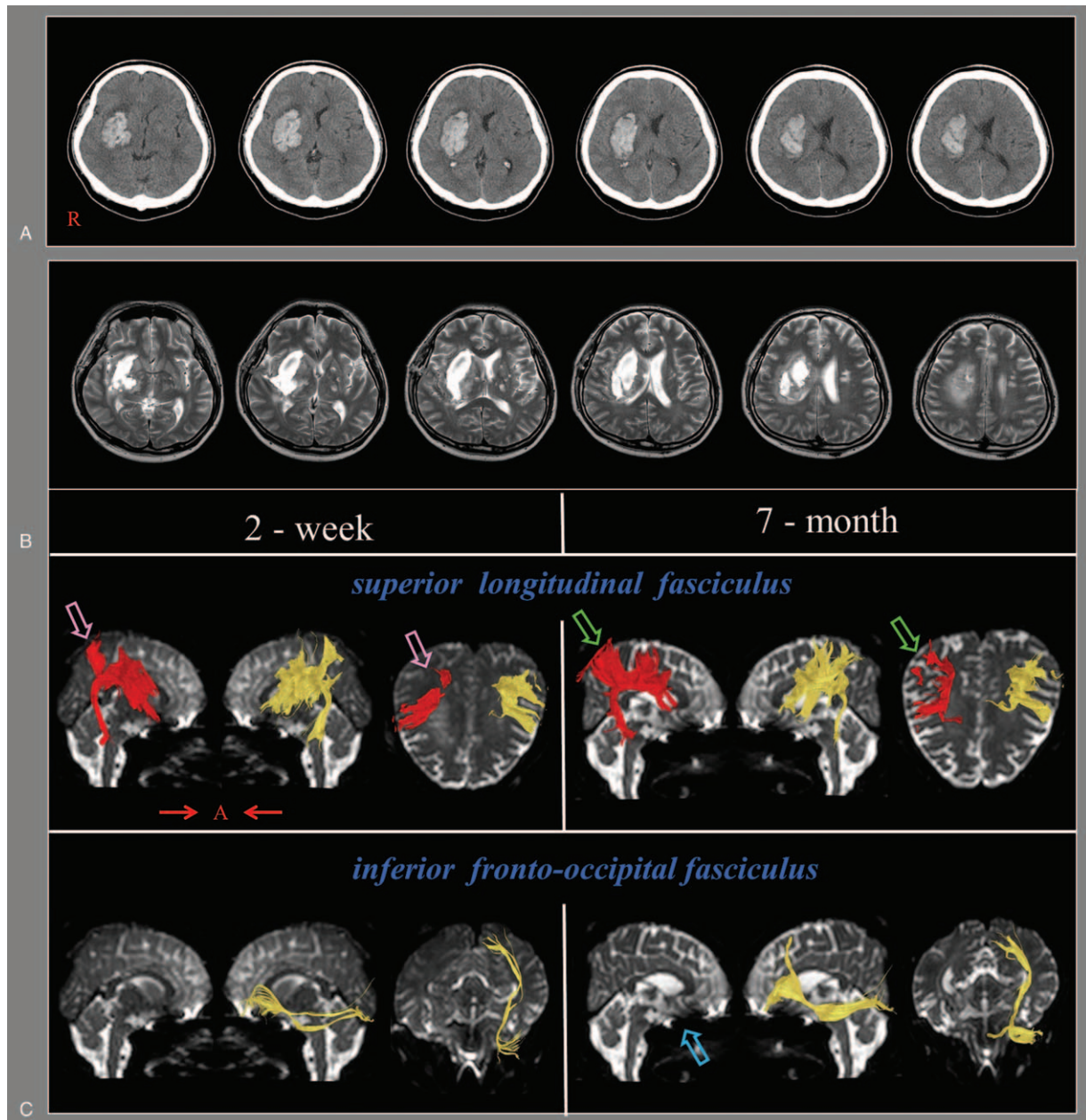


Figure 1. (A) Brain computed tomography images at the onset show evidence of intracerebral hemorrhage on the right basal ganglia. (B) T2-weighted brain magnetic resonance images at 2 weeks after onset show a leukomalactic lesion in the right basal ganglia and the centrum semiovale. (C) Diffusion tensor tractography (DTT). On 2-week DTT, the right superior longitudinal fasciculus showed partial injury and narrowing in the parietal lobe (pink arrow). The inferior fronto-occipital fasciculus was not reconstructed. On 7-month DTT, the right superior longitudinal fasciculus (green arrow) revealed elongation and thickening in the parietal lobe compared to that on 2-week DTT. However, the inferior fronto-occipital fasciculus (sky blue arrow) remained not reconstructed. DTT = diffusion tensor tractography.

and was unable to undergo even the pencil and paper test for evaluation of the severity of neglect. In addition, he had to perform most daily living activities with maximum assist (modified Barthel index=24 [full score=100]).^[21] During 7 months of rehabilitation, the patient showed significant improvement in his severe left neglect and became able to undergo various neglect tests. For example, the motor-free visual perception test that he could not perform at 2 weeks was improved to a score of 33 points at 7 months (full score=36).^[22] After 7 months of rehabilitation, we used the Apple Cancellation test to distinguish between egocentric and allocentric neglect. That test consisted of 150 apple-shaped images (50 target images [full apples] and 100 distractor images [left or right open apple]) on A4 paper.^[18,23] The test page was divided into 5 areas (2 left, 1 middle, and 2 right areas) by an invisible grid and 150 apple images were pseudorandomly scattered over the page (30 apples per area). Test scoring for egocentric neglect was based on the difference between the numbers of right area and left area (excluding the middle area), whereas scoring for allocentric neglect was based on the difference between the numbers of left area and right area open apples (including those in the middle area). The cutoff scores for the presence of left side neglect by neglect type were: egocentric neglect >2, allocentric neglect >1 (a minus score indicates right side neglect).^[18] The Apple Cancellation test has been validated for clinical usefulness via the Star Cancellation test^[18] and recently standardized for both English^[24] and Italian^[23] populations.

After 7 months of rehabilitation, the results of Apple Cancellation test did not indicate the presence of egocentric neglect (score=0, cutoff >2); however, they did reveal the presence of severe allocentric neglect (score=10, cutoff >1).^[18,25]

2.1. Diffusion tensor imaging

The DTI data for the patient were acquired twice (at 2 weeks and 7 months after intracerebral hemorrhage onset) by using a 6-channel head coil on a 1.5 T Philips Gyroscan Intera (Philips, Best, the Netherlands) with single-shot echo-planar imaging. For each of the 32 noncollinear diffusion sensitizing gradients, we acquired 70 contiguous slices parallel to the anterior commissure–posterior commissure line. Imaging parameters were as follows: acquisition matrix=96 × 96, reconstructed to matrix=192 × 192 matrix, field of view=240 mm × 240 mm, TR=10,398 ms, TE=72 ms, parallel imaging reduction factor (SENSE factor)=2, EPI factor=59, $b=1000 \text{ s/mm}^2$, NEX=1, and slice thickness=2.5 mm.

Fiber tracking was performed by using the fiber assignment continuous tracking (FACT) algorithm implemented within DTI task card software (Philips Extended MR Workspace 2.6.3, Philips Healthcare, Best, the Netherlands). Each of the DTI replications was intraregistered to the baseline “ b_0 ” images to correct for residual eddy-current image distortions and head motion effects by using a diffusion registration package (Philips Medical Systems, Best, the Netherlands). All tract analyses used 2 regions of interest (ROIs) on the obtained color map. The ROIs for the SLF analysis formed a triangular shape just lateral to the corticospinal tract (CST) near the anterior horn of the lateral ventricle and a second triangular shape near the posterior horn of the lateral ventricle.^[26–28] The ROIs of the IFOF were the ventral and medial parts of the occipital and orbitofrontal regions in the green-colored fibers on the sagittal plane.^[29,30] Fiber tracking was performed based on a fractional anisotropy (FA) threshold of >0.15 and a direction threshold of <27°.

On the patient’s 2-week DTT, the right SLF showed partial injury and narrowing in the parietal lobe compared to that of the left SLF. The right IFOF was not reconstructed. By contrast, on 7-month DTT, the right SLF revealed elongation and thickening in the parietal lobe, attaining near-similarity to that of the left SLF. However, there was still no reconstruction of the right IFOF (Fig. 1C).

3. Discussion

In this study, we investigated the changes in DTT results for the SLF and IFOF in a stroke patient and related them to the patient’s neglect type. On 2-week DTT, the partial injury and narrowing of the SLF in the parietal lobe and the absence of reconstruction of the IFOF neural tracts indicated neural injury. By contrast, on 7-month DTT, elongation and thickening in the parietal lobe region of the right SLF indicated recovery of the injured right SLF; however, the persistence of non-reconstruction of the right IFOF suggested no change in the injured right IFOF. Regarding the clinical changes in neglect during the same period, egocentric neglect had recovered without significant recovery of allocentric neglect. As a result, we assumed that the recovery of egocentric neglect was related to the recovery of the SLF. By contrast, the non-recovery of the patient’s allocentric neglect was ascribed to non-recovery of the injured IFOF.

Since the introduction of DTI, several studies have reported that the SLF in the dorsal pathway and the IFOF in the ventral pathway have important roles in neglect.^[12–17] In 2005, Thiebaut de Schotten et al^[14] demonstrated that the right SLF was responsible for the neglect observed in a patient with brain tumor. In 2009, Shinoura et al^[12] reported that the right SLF had a critical role in 2 neglect patients with brain tumors. In 2008 and 2011, Urbanski et al^[15,16] reported on stroke patients with neglect and concluded that the IFOF and the fronto-parietal connection, respectively, were the major reasons for the observed neglect. In 2014, Thiebaut de Schotten et al^[13] investigated 58 stroke patients with middle cerebral artery injury and reported that SLF II (among SLFs I, II, and III) was best predictor of left neglect. However, the aforementioned studies did not use specialized tests to distinguish between egocentric and allocentric neglect. In addition, traditional neglect tests such as the line bisection and previous cancellation tests cannot reflect the exact neglect type or its severity.^[5] Recently, Jang and Jang^[17] reported that the IFOF was the main region involved in the allocentric neglect of a patient with intracerebral hemorrhage. To the best of our knowledge, this is the first study to demonstrate the relationship between neglect type (egocentric and allocentric) and pathway (dorsal and ventral) by using both Apple Cancellation testing and DTT.

However, limitations of this study should be considered: first, the small number of patients; second, no exact identification of the neural tract causing neglect in the ventral pathway; third, inherent limitations of DTT analysis as the DTT technique may be operator dependent and regions of fiber complexity and fiber crossing may cause underestimation during reconstruction of a neural tract.^[31,32] Therefore, further studies aimed at overcoming these limitations should be encouraged.

In conclusion, an association of left side egocentric neglect with the SLF in the dorsal pathway of the right hemisphere and an association of left side allocentric neglect with the IFOF in the ventral pathway of the right hemisphere were demonstrated in a stroke patient. It appears that DTT can be helpful in demonstrating both the neural pathways involved in neglect and the type of neglect in patients with neglect. Understanding the

difference of the neural tracts which are related to allocentric and egocentric neglect is clinically important because therapeutic strategy is different between 2 types of neglect. As a result, our results can be useful for proper rehabilitative therapy in stroke patients with neglect. Ethical approval for this study was provided by Yeungnam University hospital Institutional Review Board (YUMC-2017-06-020) and the written informed consent was obtained from the patient.

Author contributions

Conceptualization: Sung Ho Jang.

Funding acquisition: Woo Hyuk Jang.

Investigation: Woo Hyuk Jang.

Methodology: Sung Ho Jang.

Project administration: Woo Hyuk Jang.

Writing – original draft: Woo Hyuk Jang.

References

- Rorden C, Hjalton H, Fillmore P, et al. Allocentric neglect strongly associated with egocentric neglect. *Neuropsychologia* 2012;50:1151–7.
- Iachini T, Ruggiero G, Conson M, et al. Lateralization of egocentric and allocentric spatial processing after parietal brain lesions. *Brain Cogn* 2009;69:514–20.
- Gainotti G, Ciaraffa F. Is 'object-centred neglect' a homogeneous entity? *Brain Cogn* 2013;81:18–23.
- Vallar G, Bottini G, Paulesu E. Neglect syndromes: the role of the parietal cortex. *Adv Neurol* 2003;93:293–319.
- Chechlacz M, Rotshtein P, Bickerton WL, et al. Separating neural correlates of allocentric and egocentric neglect: distinct cortical sites and common white matter disconnections. *Cogn Neuropsychol* 2010;27:277–303.
- Doricchi F, Tomaiuolo F. The anatomy of neglect without hemianopia: a key role for parietal-frontal disconnection? *Neuroreport* 2003;14:2239–43.
- Karnath HO, Rorden C, Ticini LF. Damage to white matter fiber tracts in acute spatial neglect. *Cereb Cortex* 2009;19:2331–7.
- He BJ, Snyder AZ, Vincent JL, et al. Breakdown of functional connectivity in frontoparietal networks underlies behavioral deficits in spatial neglect. *Neuron* 2007;53:905–18.
- Riddoch MJ, Chechlacz M, Mevorach C, et al. The neural mechanisms of visual selection: the view from neuropsychology. *Ann N Y Acad Sci* 2010;1191:156–81.
- Verdon V, Schwartz S, Lovblad KO, et al. Neuroanatomy of hemispatial neglect and its functional components: a study using voxel-based lesion-symptom mapping. *Brain* 2010;133:880–94.
- Grimsen C, Hildebrandt H, Fahle M. Dissociation of egocentric and allocentric coding of space in visual search after right middle cerebral artery stroke. *Neuropsychologia* 2008;46:902–14.
- Shinoura N, Suzuki Y, Yamada R, et al. Damage to the right superior longitudinal fasciculus in the inferior parietal lobe plays a role in spatial neglect. *Neuropsychologia* 2009;47:2600–3.
- Thiebaut de Schotten M, Tomaiuolo F, Aiello M, et al. Damage to white matter pathways in subacute and chronic spatial neglect: a group study and 2 single-case studies with complete virtual “in vivo” tractography dissection. *Cereb Cortex* 2014;24:691–706.
- Thiebaut de Schotten M, Urbanski M, Duffau H, et al. Direct evidence for a parietal-frontal pathway subserving spatial awareness in humans. *Science* 2005;309:2226–8.
- Urbanski M, Thiebaut de Schotten M, Rodrigo S, et al. Brain networks of spatial awareness: evidence from diffusion tensor imaging tractography. *J Neurol Neurosurg Psychiatry* 2008;79:598–601.
- Urbanski M, Thiebaut de Schotten M, Rodrigo S, et al. DTI-MR tractography of white matter damage in stroke patients with neglect. *Exp Brain Res* 2011;208:491–505.
- Jang SH, Jang WH. The allocentric neglect due to injury of the inferior fronto-occipital fasciculus in a stroke patient: a case report. *Medicine (Baltimore)* 2018;97:e9295.
- Bickerton WL, Samson D, Williamson J, et al. Separating forms of neglect using the Apples Test: validation and functional prediction in chronic and acute stroke. *Neuropsychology* 2011;25:567–80.
- Wadsworth CT, Krishnan R, Sear M, et al. Intrarater reliability of manual muscle testing and hand-held dynamometric muscle testing. *Phys Ther* 1987;67:1342–7.
- Jung HY, Yoon JS, Park BS. Recovery of proximal and distal arm weakness in the ipsilateral upper limb after stroke. *NeuroRehabilitation* 2002;17:153–9.
- Shah S, Vanclay F, Cooper B. Improving the sensitivity of the Barthel Index for stroke rehabilitation. *J Clin Epidemiol* 1989;42:703–9.
- Bouska MJ, Kwatny E. Manual for Application of the Motor-free Visual Perception Test to the Adult Population. 6th ed. 1983; Moss Rehabilitation Hospital.
- Mancuso M, Rosadoni S, Capitani D, et al. Italian standardization of the Apples Cancellation Test. *Neurol Sci* 2015;36:1233–40.
- Bickerton WL, Demeyere N, Francis D, et al. The BCoS cognitive profile screen: utility and predictive value for stroke. *Neuropsychology* 2015;29:638–48.
- Shah PP, Spaldo N, Barrett AM, et al. Assessment and functional impact of allocentric neglect: a reminder from a case study. *Clin Neuropsychol* 2013;27:840–63.
- Mayka MA, Corcos DM, Leurgans SE, et al. Three-dimensional locations and boundaries of motor and premotor cortices as defined by functional brain imaging: a meta-analysis. *Neuroimage* 2006;31:1453–74.
- Newton JM, Ward NS, Parker GJ, et al. Non-invasive mapping of corticofugal fibres from multiple motor areas—relevance to stroke recovery. *Brain* 2006;129:1844–58.
- Rushworth MF, Behrens TE, Johansen-Berg H. Connection patterns distinguish 3 regions of human parietal cortex. *Cereb Cortex* 2006;16:1418–30.
- Sasson E, Doniger GM, Pasternak O, et al. White matter correlates of cognitive domains in normal aging with diffusion tensor imaging. *Front Neurosci* 2013;7:32.
- Catani M, Thiebaut de Schotten M. A diffusion tensor imaging tractography atlas for virtual in vivo dissections. *Cortex* 2008;44:1105–32.
- Lee SK, Kim DI, Kim J, et al. Diffusion-tensor MR imaging and fiber tractography: a new method of describing aberrant fiber connections in developmental CNS anomalies. *Radiographics* 2005;25:53–65. discussion 66–58.
- Yamada K, Sakai K, Akazawa K, et al. MR tractography: a review of its clinical applications. *Magn Reson Med Sci* 2009;8:165–74.