



Effect on hemostasis of an absorbable hemostatic gelatin sponge after transrectal prostate needle biopsy

Kohei Kobatake ¹, Koji Mita ¹, Masao Kato ¹

¹ Department of Urology, Hiroshima City Asa Hospital, Japan

ABSTRACT

Objectives: To examine the usefulness of an absorbable hemostatic gelatin sponge for hemostasis after transrectal prostate needle biopsy.

Subjects and Methods: The subjects comprised 278 participants who underwent transrectal prostate needle biopsy. They were randomly allocated to the gelatin sponge insertion group (group A: 148 participants) and to the non-insertion group (group B: 130 participants). In group A, the gelatin sponge was inserted into the rectum immediately after biopsy. A biopsy-induced hemorrhage was defined as a case in which a subject complained of bleeding from the rectum, and excretion of blood clots was confirmed. A blood test was performed before and after biopsy, and a questionnaire survey was given after the biopsy.

Results: Significantly fewer participants in group A required hemostasis after biopsy compared to group B (3 (2.0%) vs. 11 (8.5%), $P=0.029$). The results of the blood tests and the responses from the questionnaire did not differ significantly between the two groups. In multivariate analysis, only "insertion of a gelatin sponge into the rectum" emerged as a significant predictor of hemostasis.

Conclusion: Insertion of a gelatin sponge into the rectum after transrectal prostate needle biopsy significantly increases hemostasis without increasing patient symptoms, such as pain and a sense of discomfort.

ARTICLE INFO

Key words:

prostate, biopsy, hemostasis, gelatin sponge; Gelatin Sponge, Absorbable

Int Braz J Urol. 2015; 41: 337-43

Submitted for publication:
March 22, 2014

Accepted after revision:
July 28, 2014

INTRODUCTION

Transrectal ultrasound (TRUS)-guided prostate biopsy is a standard procedure for the diagnosis of prostate cancer. It is generally a safe procedure with minimal complications including rectal and genitourinary lesions. Rectal bleeding is one of the most common side effects of TRUS-guided prostate biopsy. Although excessive bleeding is rare, it can occur and hemostasis is essential. The utility of the absorbable hemostatic gelatin sponge for hemostasis in anorectal surgery has been reported (1, 2). While the gelatin sponge can be expected to promote hemostasis in rectal bleeding, there are no studies evaluating its efficacy

on hemostasis in transrectal ultrasound-guided prostate biopsy.

OBJECTIVE

To clarify the efficacy on hemostasis of the gelatin sponge for rectal bleeding in transrectal ultrasound-guided prostate biopsy in a randomized controlled prospective study.

MATERIALS AND METHODS

This prospective study was approved by the ethical committee at Hiroshima City Asa Hospital. From October 2011 to November 2012, after

informed consent, a total of 278 participants were submitted to a transrectal ultrasound-guided prostate biopsy with an 18G×200mm biopsy needle under local anesthesia (chloride 1% lidocaine in the rectal membrane) by the same surgeon (K.K). For those participants taking antiplatelet agents, the medication was discontinued before the biopsy for an appropriate period until the antiplatelet drug was eliminated from the body, e.g. 14 days for clopidogrel bisulfate and 4 days for warfarin.

Before the biopsy, all the participants were randomly assigned to two groups by the envelope method; gelatin sponge (SPONGOSTAN™ Anal, Ethicon, Inc., Johnson & Johnson, USA, Figure-1) insertion immediately after the biopsy (group A, n=148) and no insertion (group B, n=130). In both groups, no medical procedures, such as a digital rectal examination (DRE), were done. The patients stayed in the hospital at least one day for observation of their postsurgical course by the medical staff, and this 24 hour observation period excluded as much as possible any bias in this study. The hematological value, IPSS (International Prostate Symptom Score), QoL (Quality of Life) score, OABSS (Over Active Bladder Symptom Score), and a questionnaire that was composed of 6 items with 5 levels of response (Appendix) were evaluated in both groups. Figure-2 shows the flowchart of this study.

For both groups, when blood was observed on the underwear or in the bedpan after the biopsy, the DRE was performed to confirm the degree of bleeding. If attached blood on the DRE was marginal and the color was pink or dilute red, we decided that additional measures were unnecessary. If there was considerable attached blood or blood clots, we defined it as significant rectal bleeding. We categorized significant rectal bleeding into two grades for hemostasis management, including mild (slight or moderate bleeding) and severe (profuse bleeding that required endoscopic clipping). When the bleeding was classified as mild, we inserted the gelatin sponge into the participants in either group B or reinserted it into those participants in group A. If the bleeding could not be stopped by this approach, we additionally used index finger pressure for ten minutes or more to promote hemostasis. In the severe cases, an endoscopic clipping was performed to control the bleeding because arterial bleeding was suspected. Those severe cases were given bed rest until the next morning after the prescript hemostatic approach.

The difference in background factors between groups A and B was assessed by the unpaired t-test, Mann-Whitney's U test, and chi-square test. To identify the independent predictive factors for rectal bleeding for all participants, 7 factors,

Figure 1 - The absorbable hemostatic gelatin sponge (SPONGOSTAN™ Anal) made of gelatin is cylindrical-shaped of 3 cm (diameter) X 8 cm. In the center, it has a cylindrical hollow region of 0.8 cm in diameter.


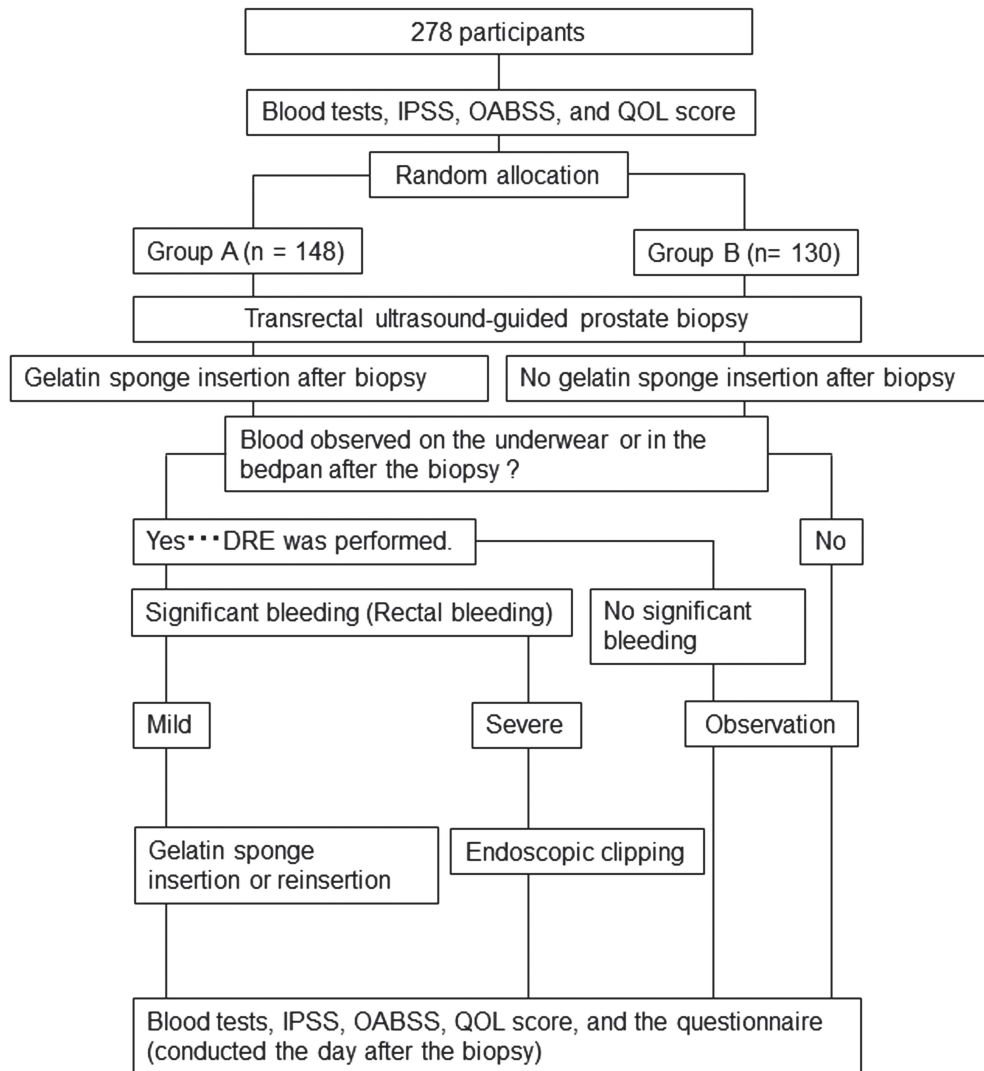


Figure 2 - Flowchart of this study.



including gelatin sponge insertion, age, PSA, prostate volume, antiplatelet drug usage, the number of biopsy samples per procedure, and number of times biopsies were performed, were analyzed by logistic regression analysis. In all analyses, a P value <0.05 was defined as significant.

RESULTS

1) Participants' background

For the 278 participants, the median age, median PSA, and median prostate volume were

71y/o (50-97), 8.4 ng/dL (1.3-4519.7), and 27.4 mL (5.2-129.3), respectively. Two hundred twenty eight of all participants (82.0%) were biopsied for the first time. In our study, 1 participant (0.4%) received 4 core biopsies, 144 participants (51.8%) received 6 core biopsies, 110 participants (39.6%) received 10 core biopsies, and 23 participants (8.3%) received 12 core biopsies. Fifty-five of the participants (19.8%) were taking antiplatelet drugs and were only biopsied after an appropriate washout period. Seven of the participants received heparin before the biopsy. Prostate adenocarcino-

ma was detected in 147 participants (52.9%) and their Gleason scores were 6 (18 patients), 7 (56 patients), and ≥ 8 (73 patients). The participants' background of groups A and B is shown in Table-1. For each item, there was no significant difference between the two groups.

2) Rectal bleeding

The frequency of major complications after prostate biopsy in all cases was 5.0% (n=14) for rectal bleeding, 33.8% (n=94) for gross hematuria, and 0.7% (n=2) for transitory urinary retention. Though the frequency of rectal bleeding in group A was significantly lower than in group B (P=0.029), there was no significant difference be-

tween the frequency of gross hematuria and transitory urinary retention between groups A and B (Table-2). The number of participants experiencing each grade of rectal bleeding was as follows: 3 mild and 0 severe in group A, and 10 mild and 1 severe in group B, respectively. Three cases in group A (100%) and 6 cases in group B (60%) in the mild grade ceased bleeding after reinsertion or insertion of the gelatin sponge. Four cases in the mild grade in group B were submitted to finger pressure for 10 minutes before the insertion of the gelatin sponge. Nevertheless, 2 of those 4 cases in the mild grade in group B had additional finger pressure for ten minutes to completely stop the bleeding. No participant received a blood transfusion.

Table 1 - Participants' background and hematological values in groups A and B.

	Group A	Group B	p-value
Participants	148	130	
Age (year)*	71 (55-97)	71 (50-89)	0.843
PSA (ng/ml)*	8.3 (1.3-1977.3)	8.4 (2.2-4519.7)	0.548
Prostate volume (ml)*	27.4 (5.2-129.3)	27.4 (10.9-105.0)	0.676
Biopsy			
Number of times			
1st	120	108	
2nd	17	14	0.972
3rd	6	4	
4th or more	5	4	
Number of samples			
4	1	0	
6	85	59	0.080
10	50	60	
12	12	11	
Detection of carcinoma	78	67	0.941
Antiplatelet drugs	34	21	0.202
Hematological value*			
Hb (g/dL)	14.2 \pm 1.7	15.1 \pm 4.4	0.102
Plt ($\times 10^4/\mu\text{L}$)	21.0 \pm 5.5	22.8 \pm 6.5	0.061

* Median value

The p values were calculated using the t test (age, PSA, prostate volume, hematological value), chi-square test (detection of carcinoma, antiplatelet drugs), and Mann-Whitney's U test (number of times and samples).

Table 2 - Frequency of main complications after the prostate biopsy.

	Total (n=278)	Group A (n=148)	Group B (n=130)	p value
Rectal bleeding	14 (5.0%)	3 (2.0%)	11 (8.5%)	0.029
Mild		3	10	
Severe		0	1	
Gross hematuria	94 (33.8%)	47 (31.8%)	47 (36.2%)	0.439
Urinary retention	2 (0.7 %)	1 (0.7%)	1 (0.8%)	0.926

*Chi-square test

There were no significant differences between the 2 groups for the following six factors: age, PSA value (ng/mL), prostate volume (mL), taking antiplatelet drugs usage (yes), number of biopsy samples per procedure (≥ 10 places vs. < 10 places), and number of times of biopsies (≥ 2 times vs. first time). The gelatin sponge insertion was the only significantly independent predictive factor that suppressed the rectal bleeding in prostate biopsy as determined by univariable analysis and by multivariate analysis (Table-3).

3) Blood tests and the questionnaires

The findings in the blood tests before and after prostate biopsy were comparable in 149 cases. There were no significant changes found in the blood tests, including hemoglobin and platelet counts between the two groups before the biopsy (table-1). There were no significant differences in

the responses to each item in our questionnaire between group A and group B (Q1; Average score 1.7 vs.1.6, $p=0.21$, Q2; Average score 1.8 vs.1.7, $p=0.41$, Q3; Average score 1.6 vs.1.5, $p=0.58$, Q4; Average score 1.5 vs.1.6, $p=0.30$, Q5; Average score 1.5 vs.1.4, $p=0.26$, and Q6; Average score 2.2 vs.2.0, $p=0.63$), respectively. Moreover, there were no significant differences in IPSS, OABSS, and QOL scores before and after biopsy.

DISCUSSION

To our knowledge, this is the first report to show that the absorbable hemostatic gelatin sponge provides significant hemostasis for rectal bleeding in TRUS-guided prostate biopsies. Based on our results, the immediate insertion of an absorbable hemostatic gelatin sponge can reduce the frequency of rectal bleeding without physical bur-

Table 3 - Logistic regression analysis.

	Univariable analysis		Multivariable analysis	
	p value	OR (95%CI)	p value	OR (95%CI)
Gelatin sponge insertion (Yes)	0.024	0.223 (0.061-0.821)	0.016	0.185 (0.047-0.732)
Age (year old)	0.776	0.989 (0.923-1.061)	0.956	0.998 (0.923-1.078)
Antiplatelet agents (Yes)	0.358	1.755 (0.528-5.820)	0.195	2.416 (0.636-9.183)
PSA (ng/ml)	0.368	0.975 (0.921-1.031)	0.430	0.973 (0.912-1.040)
Prostate volume (ml)	0.303	0.982 (0.948-1.017)	0.257	0.976 (0.935-1.018)
Number of times of biopsies (≥ 2)	0.947	0.980 (0.538-1.784)	0.791	1.220 (0.278-5.372)
Number of biopsy samples per procedure (≥ 10)	0.215	2.032 (0.633-6.226)	0.316	1.989 (0.518-7.640)

den for the participants. Furthermore, even when rectal bleeding occurs, it can be stopped in many of the cases by only inserting the gelatin sponge (in mild grade participants: 100% of group A and 60% of group B).

Rectal bleeding in a transrectal prostatic biopsy has an incidence that ranges from 0.9-37% (3-7), because the definition of rectal bleeding is defined differently depending on the institution where it was performed. Based on a large-scale retrospective analysis for 202,065 cases in Japan, the incidence of rectal bleeding in transrectal prostatic biopsy was reported as 5.6% (8). Though clinically serious bleeding is rare, sometimes rectal bleeding requires hemostasis. To date, many methods for hemostasis have been reported, such as pressure by tampon insertion, urethral catheter placement, condom expansion (9-11), and endoscopic clipping at the bleeding points (12), and endoscopic injection of epinephrine and polidocanol in cases of severe bleeding (6).

SPONGOSTAN™ Anal is an absorbable hemostatic gelatin sponge made of neutral purified gelatin (pig origin) with uniform porosity, a cylindrical shape 3 cm (diameter) X 8 cm, and a central hollow region of 0.8 cm in diameter. It has a non-water-soluble property, attaches to the bleeding tissue, and absorbs considerable amounts of blood equal to approximately 35 times the product weight. Furthermore, it provides pressure to the bleeding site while conforming to the shape of the anal canal, and platelets are trapped within the pores and form an insoluble fibrin clot that controls bleeding. In addition, after insertion in the anus, the sponge is absorbed and excreted with the stool within 1-2 days (13).

In the rectal region, there are three veins, including superior, middle, and inferior rectal veins that comprise a dense anastomosis and form the rectal venous plexus. Most rectal bleeding in transrectal prostate biopsy is thought to originate in the rectal venous plexus and can be controlled with comparative ease (9).

In this study, the gelatin sponge was placed on the needle puncture site located at approximately 3-5 cm from the anus. Unlike conventional usage, this site was located near the rectal ampulla rather than at the anal canal. The effect of the

gelatin sponge on inducing hemostasis in part by pressure is not expected in the rectal ampulla because this site has considerable elasticity though there are individual patient differences. Our study suggested that the gelatin sponge when applied to the bleeding site absorbed blood and might provide a hemostatic effect. However, in severe cases and in a few mild cases, the gelatin sponge apparently could not be applied to the bleeding site directly and did not establish hemostasis because the rectal ampulla expanded due to blood retention. The branch of the inferior rectal artery forms a vascular bed among inferior vesical arteries. Severe bleeding cases requiring endoscopy may be due to arterial bleeding. In such cases, the gelatin sponge may not work, and thus, endoscopic clipping is necessary as soon as severe bleeding is observed. Evaluation of the severity of bleeding was essential for selecting the hemostatic approach, such as whether to use an endoscopic approach, to apply pressure to the site, to insert the gelatin sponge, or to only monitor the bleeding.

For those taking antiplatelet drugs, though the bleeding risk was considered low (15, 16), we discontinued the use of these drugs prior to the biopsy in order to exclude that variable. As for other factors, several reports showed that the incidence of complications did not correlate in prostate biopsy when considering the size of the biopsy needle or the number of biopsies (17, 18). In cases of patients with hemorrhoids, they did have a bleeding risk because the rectal venous plexus was enlarged (12). In this study, none of the participants had hemorrhoids in the 14 rectal bleeding cases.

This study has some limitations, such as the data being based on a relatively small number of participants and the lack of selection for the best candidates. Based on our results, although we demonstrated that the immediate insertion of a gelatin sponge into the rectum after transrectal prostate needle biopsy was probably useful, simple, effective, and safe, it was difficult to prove the 'true' benefit of the gelatin sponge in comparison with other hemostatic procedures. We demonstrate that use of the gelatin sponge for those who have bleeding after a biopsy can be an option. Further study is required to clarify these issues.

CONCLUSIONS

Immediate insertion of the absorbable hemostatic gelatin sponge into the rectum after transrectal ultrasound-guided prostate needle biopsy significantly decreases rectal bleeding without increasing patient symptoms, such as pain and a sense of discomfort.

CONFLICT OF INTEREST

None declared.

REFERENCES

1. Agbo SP. Surgical management of hemorrhoids. *J Surg Tech Case Rep.* 2011;3:68-75.
2. Gaj F, Trecca A, Crispino P. Proctological surgery: use of an absorbable haemostatic sponge. *Chir Ital.* 2008;60:125-9.
3. Rietbergen JB, Kruger AE, Kranse R, Schröder FH. Complications of transrectal ultrasound-guided systematic sextant biopsies of the prostate: evaluation of complication rates and risk factors within a population-based screening program. *Urology.* 1997;49:875-80.
4. Petroski RA, Griewe GL, Schenkman NS. Delayed life-threatening hemorrhage after transrectal prostate needle biopsy. *Prostate Cancer Prostatic Dis.* 2003;6:190-2.
5. Collins GN, Lloyd SN, Hehir M, McKelvie GB. Multiple transrectal ultrasound-guided prostatic biopsies--true morbidity and patient acceptance. *Br J Urol.* 1993;71:460-3.
6. Brullet E, Guevara MC, Campo R, Falcó J, Puig J, Prera A, et al. Massive rectal bleeding following transrectal ultrasound-guided prostate biopsy. *Endoscopy.* 2000;32:792-5. Review.
7. Djavan B, Waldert M, Zlotta A, Dobronski P, Seitz C, Remzi M, et al. Safety and morbidity of first and repeat transrectal ultrasound guided prostate needle biopsies: results of a prospective European prostate cancer detection study. *J Urol.* 2001;166:856-60.
8. Kakehi Y, Naito S; Japanese Urological Association. Complication rates of ultrasound-guided prostate biopsy: a nation-wide survey in Japan. *Int J Urol.* 2008;15:319-21.
9. Maatman TJ, Bigham D, Stirling B. Simplified management of post-prostate biopsy rectal bleeding. *Urology.* 2002;60:508.
10. Kilciler M, Erdemir F, Demir E, Güven O, Avci A. The effect of rectal Foley catheterization on rectal bleeding rates after transrectal ultrasound-guided prostate biopsy. *J Vasc Interv Radiol.* 2008 ;19:1344-6.
11. Gonen M, Resim S. Simplified treatment of massive rectal bleeding following prostate needle biopsy. *Int J Urol.* 2004;11:570-2.
12. Katsinelos P, Kountouras J, Dimitriadis G, Chatzimavroudis G, Zavos C, Pilpilidis I, et al. Endoclippping treatment of life-threatening rectal bleeding after prostate biopsy. *World J Gastroenterol.* 2009 7;15:1130-3.
13. Spongostan: Information available at. <http://www.ethicon.jp/products/hemostat/spongstan.html>
14. Thorlakson RH. Pain and bleeding after anorectal operations with special reference to anal dressings. *Surg Gynecol Obstet.* 1963;117:56-60.
15. Chowdhury R, Abbas A, Idriz S, Hoy A, Rutherford EE, Smart JM. Should warfarin or aspirin be stopped prior to prostate biopsy? An analysis of bleeding complications related to increasing sample number regimes. *Clin Radiol.* 2012;67:e64-70.
16. Ihezue CU, Smart J, Dewbury KC, Mehta R, Burgess L. Biopsy of the prostate guided by transrectal ultrasound: relation between warfarin use and incidence of bleeding complications. *Clin Radiol.* 2005;60:459-63; discussion 457-8.
17. Berger AP, Gozzi C, Steiner H, Frauscher F, Varkarakis J, Rogatsch H, et al. Complication rate of transrectal ultrasound guided prostate biopsy: a comparison among 3 protocols with 6, 10 and 15 cores. *J Urol.* 2004;171:1478-80; discussion 1480-1.
18. Cicione A, Cantiello F, De Nunzio C, Tubaro A, Damiano R. Prostate biopsy quality is independent of needle size: a randomized single-center prospective study. *Urol Int.* 2012;89:57-60.

Correspondence address:

Koji Mita, MD
 Department of Urology
 Hiroshima City Asa Hospital, Hiroshima, Japan
 2-1-1, Kabe-Minami, Asakita-Ku,
 Hiroshima City, Japan 731-0293
 Fax: +81 82 814-1791
 E-mail: mita@plum.ocn.ne.jp