

# Educational Case: Invasive Ductal Carcinoma of the Breast

Ashley Rose Scholl, MSc<sup>1</sup>  and Melina B. Flanagan, MD, MSPH<sup>1</sup>

*The following fictional case is intended as a learning tool within the Pathology Competencies for Medical Education (PCME), a set of national standards for teaching pathology. These are divided into three basic competencies: Disease Mechanisms and Processes, Organ System Pathology, and Diagnostic Medicine and Therapeutic Pathology. For additional information, and a full list of learning objectives for all three competencies, see <http://journals.sagepub.com/doi/10.1177/2374289519897390>.<sup>1</sup>*

## Keywords

pathology competencies, organ system pathology, breast, palpable breast mass, types of breast neoplasia, invasive ductal carcinoma, prognostic factors, molecular basis

Received June 10, 2019. Received revised September 30, 2019. Accepted for publication November 2, 2019.

## Primary Objective

*Objective BR2.6: Categories of Breast Cancer.* Construct a table to compare and contrast invasive ductal carcinoma (NOS), invasive lobular carcinoma, medullary carcinoma, colloid (mucinous) carcinoma, tubular carcinoma, and metaplastic carcinoma of the breast in terms of incidence, age predilection, etiology, pathogenesis, clinical presentation, gross and microscopic morphology, grade, molecular classification, patterns of spread, clinical course, prognostic indicators, treatment options, and survival rates, and indicate which are more common in males versus females.

Competency 2: Organ System Pathology; Topic BR: Breast; Learning Goal 2: Molecular Basis of Breast Neoplasms.

## Secondary Objectives

*Objective BR2.5: Gene Expression in Breast Cancer.* Explain the major molecular classes of invasive ductal carcinoma of the breast identified by gene expression profiling, and describe how each correlates with prognosis and response to therapy.

Competency 2: Organ System Pathology; Topic BR: Breast; Learning Goal 2: Molecular Basis of Breast Neoplasms.

*Objective N3.1: Morphologic Features of Neoplasia.* Describe the essential morphologic features of neoplasms and indicate how these can be used to diagnose, classify, and predict biological behavior of cancers.

Competency 1: Disease Mechanisms and Processes; Topic N: Neoplasia; Learning Goal 3: Characteristics of Neoplasia.

## Patient Presentation

A 65-year-old woman presents to her physician with a palpable right breast mass that she discovered while showering. The patient lives by herself on a farm and does not go to doctors aside from emergencies. She does not take any medications and is nulliparous.

<sup>1</sup> Department of Pathology, Anatomy and Laboratory Medicine, West Virginia University, Morgantown, WV, USA

## Corresponding Author:

Ashley Rose Scholl, Department of Pathology, Anatomy and Laboratory Medicine, West Virginia University, 64 Medical Center Drive, Morgantown, WV 26506, USA.

Email: [ars0049@mix.wvu.edu](mailto:ars0049@mix.wvu.edu)



## Diagnostic Findings, Part 1

The patient appears anxious. Clinical breast examination reveals a palpable mass in the right breast of approximately 2 cm in size that is located 3 cm lateral to the nipple. The nipple is retracted, and there is no nipple discharge. There are no palpable abnormalities in the left breast. The remainder of the physical examination is unremarkable.

## Questions/Discussion Points, Part 1

*Given the Clinical Presentation of a Palpable Breast Mass, What Is the Most Likely Diagnosis, and How Does This Vary at Different Ages?*

In postmenopausal women, 60% of palpable breast masses are malignant. In women less than 40 years old, about 10% of palpable masses are malignant; in this younger population, the most likely diagnosis of a breast mass is either a fibroadenoma or fibrocystic change. A breast mass becomes palpable and amenable to detection by self-breast examinations only once it has grown to approximately 2 to 3 cm. At that point, many breast carcinomas will have already metastasized.<sup>2</sup>

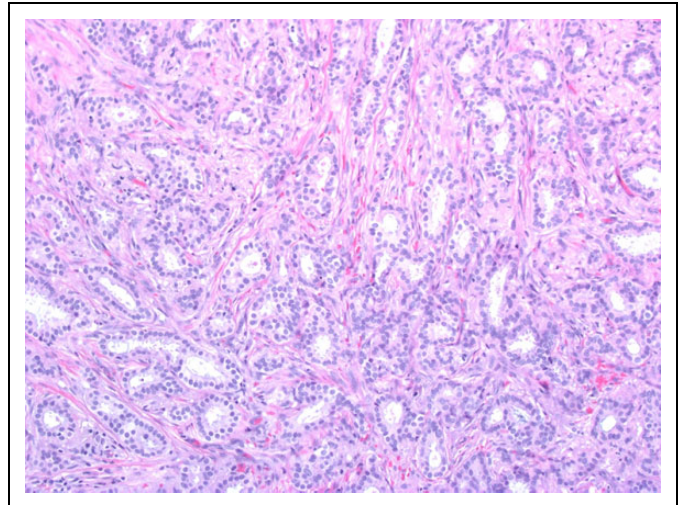
*What Questions Should be Asked as Part of the Patient's History and Why?*

1. When was her last mammogram?

Regular mammographic screening detects breast cancers at an earlier stage than they would be otherwise, at a point that they are more easily treatable.<sup>3</sup> Several professional organizations provide recommendations regarding mammography for breast cancer screening, including the US Preventive Services Task Force, the American Cancer Society, the American College of Obstetricians and Gynecologists, and the American College of Radiology. Screening mammograms may be initiated in women starting at age 40, on an annual basis. Some organizations suggest that screening may wait until the age of 50. All basic guidelines apply to women of average risk, while those women with higher risk of developing breast cancer may start screening earlier and be screened more frequently.<sup>4</sup> A breast cancer that grows between annual mammograms (so-called "interval breast carcinoma") is likely to be an aggressive tumor.<sup>5</sup> In this case, the patient's last mammogram was 5 years ago.

2. Is there a family history of any malignancies? If so, what type of cancer, and in which relatives?

Most breast cancers are sporadic, while about 12% are familial. A family history of breast or ovarian cancer in a first-degree relative diagnosed at a premenopausal age raises the possibility of a genetic mutation. The most common mutations involved in breast cancers are BRCA1 and BRCA2 (80%-90% of familial cases). Patients with either of these mutations have a higher lifetime risk of developing breast cancer, and



**Figure 1.** Breast core needle biopsy, H&E, ×100.

these breast cancers tend to occur at a younger age and be more aggressive than sporadic breast cancers. BRCA mutations are also associated with ovarian surface epithelial malignancies most notably, as well as other tumors. Other genes known to be involved in breast cancer include TP53, CHEK2, PTEN, STK11, and ATM. These mutated genes account for less than 10% of hereditary breast cancer. Most genes that increase susceptibility for breast cancer are tumor suppressor genes that normally function to in DNA repair and maintenance of genomic integrity.<sup>2,6</sup> In this case, the patient has no known family history of breast cancer.

*What Is the Next Step?*

Standard of care for a newly discovered breast mass is to obtain tissue via a minimally invasive biopsy technique such as core needle biopsy. This can discern a benign versus malignant mass. In the event of malignant or premalignant diagnosis, early tissue diagnosis guides preoperative management, allowing for potential additional imaging, neoadjuvant chemotherapy, and surgical decision-making.<sup>7</sup>

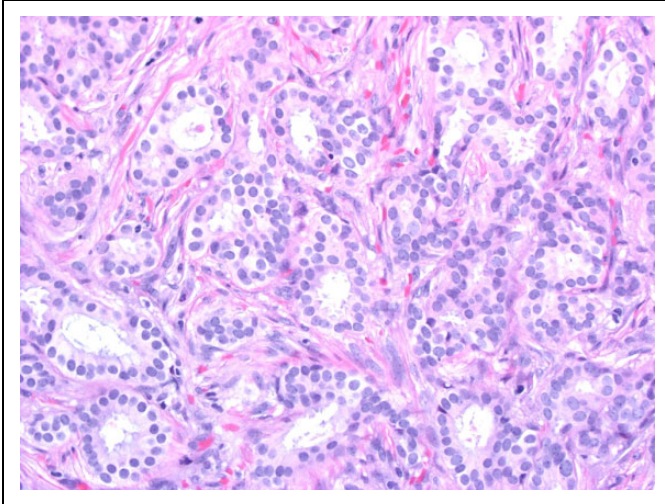
## Diagnostic Findings, Part 2

The patient undergoes an ultrasound-guided core needle biopsy, shown in Figures 1 and 2 (H&E) and Figure 3 (immunostain for myoepithelial cells, p63).

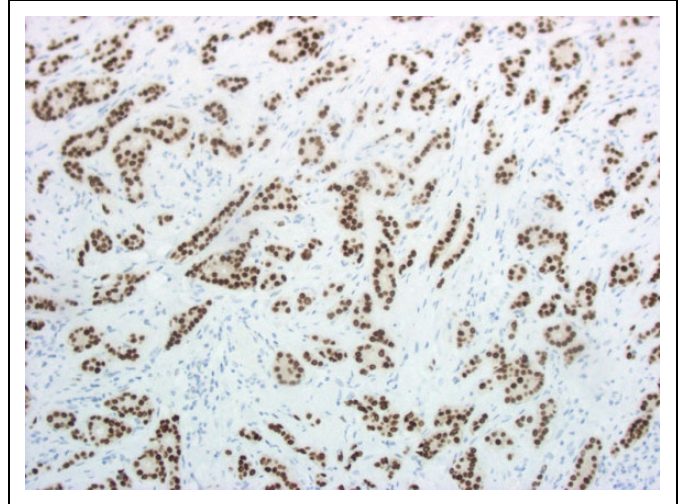
## Questions/Discussion Points, Part 2

*What Are the Biopsy Findings and Diagnosis?*

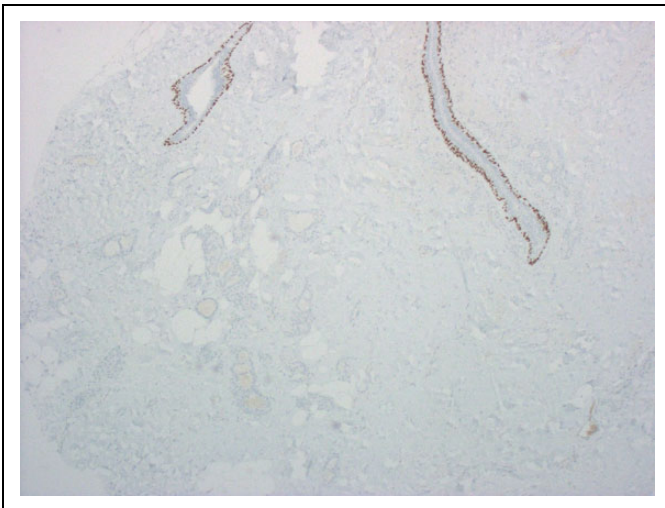
Biopsies show cores of breast tissue with atypical glands infiltrating the stroma in an irregular pattern. P63, an immunohistochemical stain for myoepithelial cells, is negative around tumor cells, while positive around benign ducts. Based upon the morphology and immunohistochemical staining, this is an invasive ductal carcinoma of the breast.



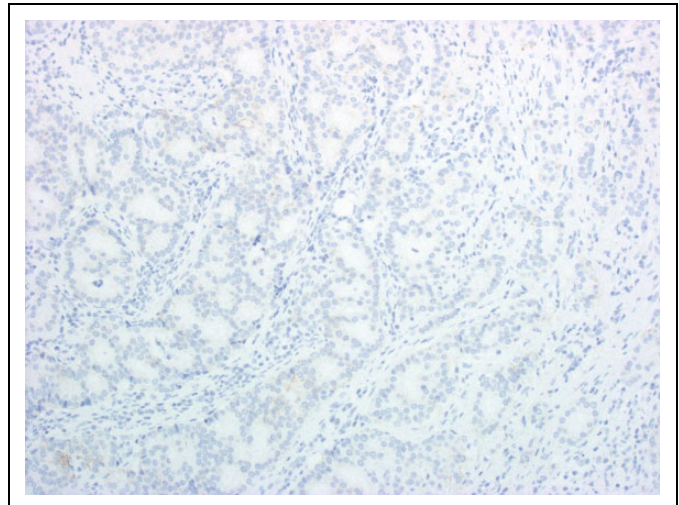
**Figure 2.** Breast core needle biopsy, H&E, ×200.



**Figure 4.** Estrogen receptor (ER) immunohistochemical stain shows strong nuclear staining, ×100.



**Figure 3.** p63 immunohistochemical stain for myoepithelial cells, ×50.



**Figure 5.** HER-2/neu immunohistochemical stain is negative, ×100.

Ductal carcinomas have a wide range of appearances and are thus also referred to as “no special type.” Classically, well-differentiated tumors show an infiltration of glands through the breast stroma; however, the more poorly differentiated the tumor is, the less tubules it shows, with more solid sheets of tumors. In fact, grading of breast carcinomas takes into account the extent of glandular differentiation, degree of nuclear pleomorphism, and the mitotic rate; these 3 variables are combined into a grade ranging from 1 (well differentiated) to 3 (poorly differentiated). The grade is one of the many prognostic factors for breast carcinomas.<sup>2</sup>

#### *What Additional Testing Is Required for Predictive/Prognostic Purposes?*

All new cases of invasive breast adenocarcinomas are tested for estrogen receptors (ERs), progesterone receptors (PRs), and

human epidermal growth factor receptor (HER2) status.<sup>8</sup> Estrogen receptor and PR are tested by immunohistochemistry; HER2 can be tested by either immunohistochemistry or in situ hybridization (usually fluorescent or FISH). Estrogen receptor and/or PR positivity is predictive for successful treatment with tamoxifen or aromatase inhibitors. Human epidermal growth factor receptor positivity is predictive for successful treatment with Trastuzumab. These are also all prognostic and can be used in the molecular classification of breast adenocarcinomas.<sup>9</sup>

#### **Diagnostic Findings, Part 3**

In this patient’s case, ER shows strong nuclear staining in almost all tumor cells (Figure 4), and HER2 is negative (Figure 5). Thus, the patient has an invasive ductal carcinoma that is ER-positive and HER-2/neu-negative.

### Questions/Discussion Points, Part 3

#### How Are Types of Invasive Breast Carcinoma Categorized?

The vast majority of breast malignancies are adenocarcinomas arising from the ducts or lobules. Traditionally, these were categorized by morphology. The most common histologic type of breast cancer is invasive ductal carcinoma or carcinoma of no special type (40%-75%). The remainder of carcinomas is classified as specialized types. These include but are not limited to lobular carcinoma (5%-15%), mucinous carcinoma (2%), tubular carcinoma (2%), medullary carcinoma (<1%), and metaplastic carcinoma (0.2%-5%).<sup>2,10</sup>

Molecular gene expression profiling studies heralded a new era in the classification of breast carcinomas. In addition to morphology, breast carcinomas now are categorized into 1 of 3 subtypes based on the tumor's expression of HER2 and ERs. Although testing is almost always performed for PR as well as ER, descriptions of molecular classifications generally use ER status as a surrogate marker for PR as well. The 3 subtypes are:

- ER-positive/HER2-negative (50%-65% of tumors).
- HER2-positive (10%-20% of tumors).
- ER-negative/HER2-negative (10%-20% of tumors).

These subtypes have different pathological features, treatments, and outcomes.<sup>2</sup>

#### Describe the Mechanisms of Disease, Prognosis, and Therapy for ER-Positive/HER2-Negative Invasive Carcinomas

The ER-positive/HER2-negative breast cancers are often associated with losses of chromosome 16q and gains in chromosome 1q, as well as activating mutations in PIK3CA, a growth factor receptor signaling molecule. This type of breast carcinoma often progresses through a sequence that can include flat epithelial atypia, atypical ductal hyperplasia, ductal carcinoma in situ (DCIS), and eventually invasive ductal carcinoma. The ER-positive/HER2-negative invasive ductal carcinoma can be further categorized by whether it shows a low or high proliferation rate. Low proliferation tumors are more common. Many of these are detected early and are often cured by surgery because they take several years to metastasize. This subtype is primarily treated with hormone therapy instead of chemotherapy because very few of these carcinomas respond to chemotherapeutic drugs. The high proliferation subtype composes approximately 10% of cancers and has a 10% complete response to chemotherapy. This type tends to carry a much higher mutational burden than the low proliferation subtype. This subtype is associated with BRCA2 mutations. Well-differentiated tumors tend to fall into the ER-positive/HER2-negative category. Many different histologic types of tumors may be ER-positive/HER2-negative, including ductal, mucinous, and lobular.<sup>2</sup>

#### Describe the Mechanisms of Disease, Prognosis, and Therapy for HER2-Positive Invasive Carcinomas

These tumors are defined by HER-2 positivity, regardless of ER status. The HER2-positive carcinomas are characterized by mutations in tumor suppressor TP53, which allow amplification of HER2 on chromosome 17q. The suggested precursor lesion for this type of carcinoma is atypical apocrine adenosis that progresses to DCIS. This subtype is more common in nonwhite and young women and in patients with Li-Fraumeni syndrome (hereditary TP53 mutation). These cancers can metastasize early, often to the brain and viscera, and even when small in size. The drug trastuzumab (Herceptin) is a monoclonal antibody that inhibits HER2 and vastly improves survival. Once metastasized, survival is uncommon. These tend to be poorly differentiated, and there is no association with a specific morphologic type of breast carcinoma.<sup>2</sup>

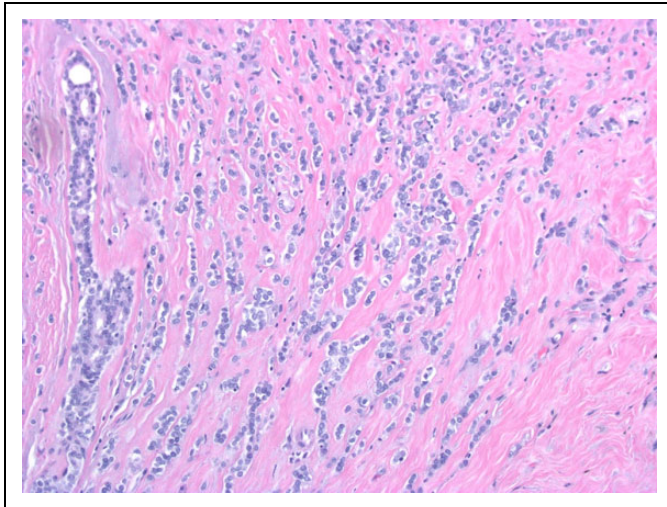
#### Describe the Mechanisms of Disease, Prognosis, and Therapy for ER-Negative/HER2-Negative Invasive Breast Carcinomas

The ER-negative/HER2-negative cancers, also known as triple negative as PR is also negative, are the least understood of the subtypes of invasive ductal carcinoma. This subtype arises through a pathway independent from changes in HER-2 and ERs. A precursor lesion has not been identified other than DCIS. Most carcinomas in women with BRCA1 mutations are triple negative. These are also seen in young often premenopausal women and African-American women. These cancers grow and metastasize quickly to the brain and viscera. Approximately 30% respond to chemotherapy and they tend to recur within 5 years. Triple-negative breast carcinomas (TNBCs) tend to be poorly differentiated. Although these may be associated with several histologic patterns, many of them show poorly differentiated cells with a surrounding lymphoplasmacytic infiltrate and are described as having medullary features.<sup>2</sup>

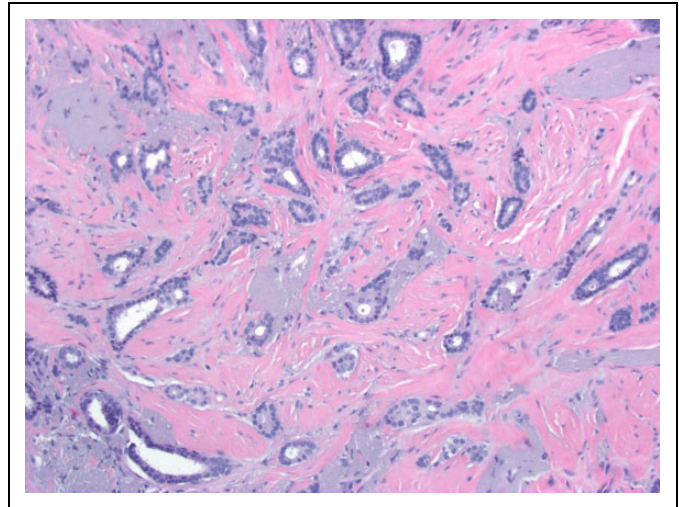
#### Describe the Pathogenesis, Microscopic Morphology, Molecular Classification, and Clinical Features of the Most Common Specialized Types of Breast Carcinoma

Lobular carcinoma is the most common type of breast cancer following ductal carcinoma and is composed of dyscohesive monomorphic cells that lack tubule formation (see Figure 6).<sup>2</sup> The dyscohesion is due to inactivation of the cell adhesion molecule E-cadherin. These tumors are invariably ER-positive in 60% to 70% of tumors, and generally negative for HER2. The prognosis of this tumor is favorable; however, this type is associated with a worse long-term outcome relative to ductal carcinoma in terms of higher incidences of mortality, recurrence, and distant metastasis.<sup>10</sup>

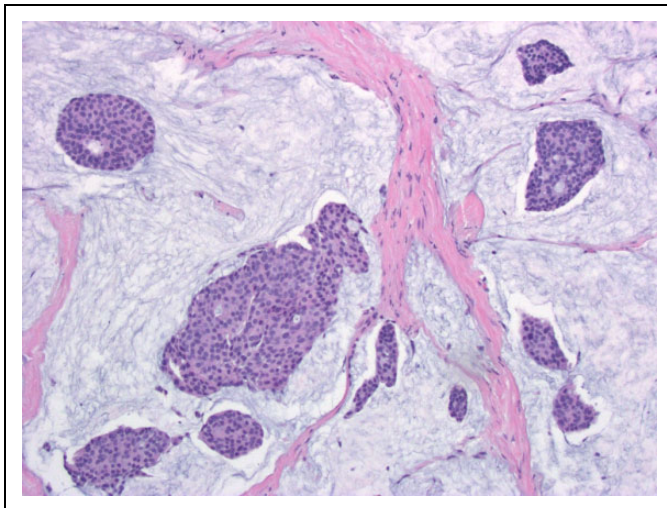
In mucinous carcinoma, well to moderately differentiated neoplastic cells are clustered in small groups within large pools of mucin (see Figure 7).<sup>2</sup> This type of carcinoma is typically ER-positive and HER2-negative. Mucinous carcinoma has an



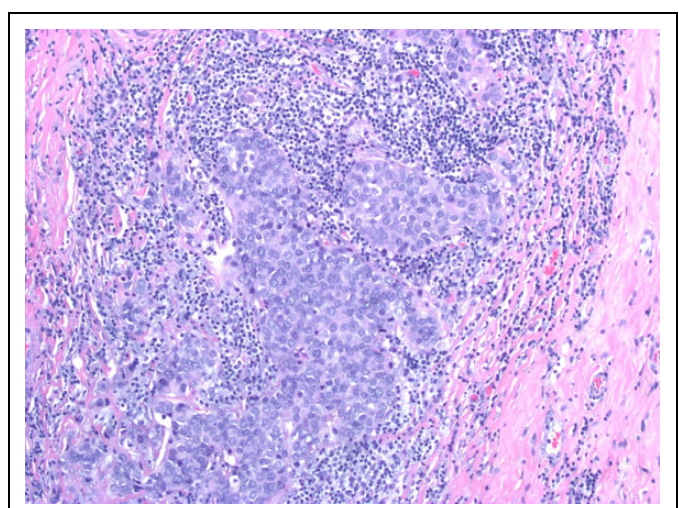
**Figure 6.** Invasive lobular carcinoma,  $\times 100$ .



**Figure 8.** Tubular carcinoma,  $\times 100$ .



**Figure 7.** Mucinous carcinoma,  $\times 100$ .



**Figure 9.** Medullary carcinoma,  $\times 100$ .

excellent 5-year survival rate and low rate of distant and local recurrence.<sup>10</sup>

Tubular carcinoma is composed of well-formed tubules, often shaped like teardrops (see Figure 8).<sup>2</sup> This type of carcinoma is uncommon, at only 2% of invasive breast carcinomas, and is associated with an excellent prognosis. Tubular carcinoma is generally ER-positive/HER2-negative.<sup>10</sup>

Metaplastic carcinoma is a heterogeneous category of neoplasms that have differentiated into squamous or mesenchymal cells. Greater than 90% of metaplastic carcinomas are ER-negative/HER2-negative. When compared with other TNBCs, metaplastic carcinoma has a worse clinical outcome and lower chemotherapy response rate.<sup>10</sup>

Medullary carcinoma is comprised of solid syncytial sheets of pleomorphic cells with prominent nucleoli, a lymphoplasmacytic infiltrate, numerous mitoses, and a pushing border (see Figure 9).<sup>2</sup> These tumors are typically triple negative and often associated with BRCA mutations. Traditionally, these tumors

were reported to have a relatively favorable prognosis; however, due to low level for reproducibility for the diagnosis as well as the poor prognosis associated with TNBCs, these tumors are now termed “carcinomas with medullary features” and treated with aggressive therapy.<sup>10</sup> These special types of tumors are summarized in Table 1.

### Teaching Points

- Mammography is the recommended screening technique for breast carcinomas and can be started in women after the age of 40.
- A palpable nodule in a postmenopausal woman is statistically most likely to be an invasive carcinoma.
- Invasive ductal carcinoma, also known as “no special type,” is the most common type of breast cancer. The morphologic features are variable but generally show malignant ducts invading surrounding stroma.

**Table 1.** Comparison of Major Histologic Types of Breast Carcinoma.<sup>1</sup>

Tumor Type	Incidence	Gross Morphology	Microscopic Morphology	Molecular Classification	Patterns of Spread	Prognosis
Invasive ductal carcinoma (NOS)	40%-75%	Hard, irregular mass associated with a desmoplastic stromal reaction.	Glands infiltrating stroma with variable extent of tubule formation and a range of nuclear pleomorphism.	Depends on ER, PR, and HER2 status (see text).	May spread locally to skin or skeletal muscle. May metastasize to axillary lymph nodes or distant sites.	Reference (prognosis of other types given in relation to ductal).
Invasive lobular carcinoma	5%-15%	May form mass (like ductal) or be infiltrative with no distinct mass.	Dyscohesive monomorphic cells without tubule formation, sometimes with signet ring cells with intracytoplasmic mucin droplets.	Biallelic loss of expression of <i>CDH1</i> (gene that encodes E-cadherin). Usually ER-positive, HER2-negative.	Metastasis often involves peritoneum, retroperitoneum, leptomeninges, gastrointestinal tract, ovaries, and uterus.	Better than ductal.
Mucinous carcinoma	2%	Soft/rubbery, pale gray-blue gelatin.	Well to moderately differentiated neoplastic cells in small clusters within pools of mucin.	Usually ER-positive, HER2-negative.	Similar to ductal.	Better than ductal.
Tubular carcinoma	2%	Mass forming.	Well-formed, often teardrop-shaped tubules.	Usually ER-positive, HER2-negative.	Similar to ductal.	Better than ductal.
Metaplastic carcinoma	0.2%-5%	Mass forming.	Heterogeneous category with many different appearances.	Usually ER-negative, HER2-negative.	Similar to ductal.	Poorer than ductal.
Medullary carcinoma	<1%	Well-circumscribed mass.	Solid syncytial sheets of pleomorphic cells with prominent nucleoli, a lymphoplasmacytic infiltrate, numerous mitoses and a pushing border.	Often association with BRCA mutations, and often triple negative.	Similar to ductal.	Better than ductal.

Abbreviations: ER, estrogen receptor; HER2, human epidermal growth factor receptor; NOS, not otherwise specified; PR, progesterone receptor.

- There are 3 major molecular subtypes of invasive ductal carcinoma—ER/HER-2 negative, HER-2-positive, and ER-positive/HER-2-negative. Each is characterized by a different pathogenesis and has unique treatment and prognosis.
- Specialized types of breast carcinoma include but are not limited to lobular, mucinous, tubular, metaplastic, and medullary. These each have distinct histomorphologic features, molecular classifications, and prognoses that vary from ductal carcinoma.


### Declaration of Conflicting Interests

The author(s) declared no potential conflicts of interest with respect to the research, authorship, and/or publication of this article.

### Funding

The author(s) disclosed receipt of the following financial support for the research, authorship, and/or publication of this article: The article processing fee for this article was funded by an Open Access Award given by the Society of '67, which supports the mission of the Association of Pathology Chairs to produce the next generation of outstanding investigators and educational scholars in the field of pathology. This award helps to promote the publication of high-quality original scholarship in *Academic Pathology* by authors at an early stage of academic development.

### ORCID iD

Ashley Rose Scholl  <https://orcid.org/0000-0001-8809-9276>

### References

1. Knollmann-Ritschel BEC, Regula DP, Borowitz MJ, Conran R, Prystowsky MB. Pathology competencies for medical education and educational cases. *Acad Pathol.* 2017;4. doi:10.1177/2374289517715040.
2. Lester S. The breast. In: Kumar V, Abbas AK, Aster JC, eds. *Robbins and Cotran Pathologic Basis of Disease*. 9th ed. Philadelphia, PA: Elsevier/Saunders; 2015:1043-1072.
3. Fuller MS, Lee CI, Elmore JG. Breast cancer screening: an evidence-based update. *Med Clin North Am.* 2015;99:451-468.
4. Center for Disease Control: Breast cancer screening guidelines for women. 2016. <https://www.cdc.gov/cancer/breast/pdf/BreastCancerScreeningGuidelines.pdf>. Accessed May 19, 2019.
5. Kirsh VA, Chiarelli AM, Edwards SA, et al. Tumor characteristics associated with mammographic detection of breast cancer in the Ontario breast screening program. *J Natl Cancer Inst.* 2011;103:942-950.
6. Kleibl Z, Kristensen VN. Women at high risk of breast cancer: molecular characteristics, clinical presentation and management. *Breast.* 2016;28:136-144.

7. American Society of Breast Surgeons: Consensus Guideline on Image-Guided Percutaneous Biopsy of Palpable and Nonpalpable Breast Lesions. *Official Statement*. 2017; <https://www.breastsurgeons.org/docs/statements/Consensus-Guideline-on-Image-Guided-Percutaneous-Biopsy-of-Palpable-and-Nonpalpable-Breast-Lesions.pdf>. Accessed May 19, 2019.
8. National Comprehensive Cancer Network (NCCN) Clinical practice guideline in oncology, Version 3. 2017. [www.nccn.org/professionals/physician\\_gls/PDF/breast.pdf](http://www.nccn.org/professionals/physician_gls/PDF/breast.pdf). Accessed May 29, 2019.
9. College of American Pathologists: Template for reporting results of biomarker testing of specimens from patients with carcinoma of the breast. 2018. <https://documents.cap.org/protocols/cp-breast-18biomarker-1201.pdf>. Accessed May 29, 2019.
10. Lakhani SR, Ellis IO, Schnitt SJ, Tan PH, van de Vijver MJ. WHO classification of tumours of the breast. Vol 4. In: *WHO Series on Histological and Genetic Typing of Human Tumours*, 4th ed. Geneva, Switzerland: International Agency for Research on Cancer/World Health Organization; 2012.