

## Case Report

## Teriparatide and vertebral fracture healing in Ankylosing Spondylitis

Izolda Biro<sup>a,\*</sup>, Judith Bubbear<sup>b</sup>, Simon Donnelly<sup>b</sup>, Zozik Fattah<sup>b</sup>, James Sarkodie<sup>b</sup>, Arun Ranganathan<sup>b</sup>, Hasan Tahir<sup>b</sup><sup>a</sup> Clinical Research Unit, Department of Rheumatology, Whipps Cross University Hospital, Barts Health NHS Trust, London, UK<sup>b</sup> Whipps Cross University Hospital, Barts Health NHS Trust, London, UK

## ARTICLE INFO

## Keywords:

Teriparatide  
Recombinant parathyroid hormone  
Trauma  
Cervical fracture  
Ankylosing Spondylitis

## ABSTRACT

**Summary:** Patients with Ankylosing Spondylitis (AS) are four times more likely to sustain spinal fractures. Due to the associated risk of neurological complications treatment is complex.

We present the case of a 56-year-old Caucasian gentleman with AS who sustained a fracture of T2 vertebra following a traumatic hyperextension injury. He declined surgery in fear of complications and started treatment with subcutaneous Teriparatide at a dose of 20 mg daily for six months.

There was complete healing of the vertebral fracture at 6 months without any complications.

This case is unique as complete healing was achieved without preceding surgical intervention. Further exploration of the use of Teriparatide in spinal fractures in patients with AS is recommended to support the theories generated by this and other existing cases in the literature.

## Introduction

Ankylosing Spondylitis (AS) is a chronic inflammatory condition typically affecting the joints of the axial spine and less commonly the peripheral skeleton. Typical features of advanced disease is fusion of the sacroiliac joints and vertebral bodies leading to generalized stiffness and irreversible loss of spinal movement[1].

The biomechanical instability secondary to multilevel bony fusion and osseous spurring can lead to vertebral fractures[2]. These fractures can be unstable due to ossification of the supportive soft tissue and may lead to primary or secondary neurological deficit [3]. The majority of fractures in AS are the result of low grade traumatic events. The cervical and lumbar spine are predominantly affected[4].

Management of cervical fractures in AS is often complex with associated risks of neurological complications and radiographs may be difficult to interpret due to pre-existing osseous changes, kyphosis and high-riding shoulders[5].

A systematic review of the literature showed that delayed diagnosis can lead to 67.2% of AS patients sustaining neurological deficit and surgical complication rates can be as high as 51.1%. Overall mortality was 17.7% at three months and considerably worse compared to the general population[6]. AS patients are 11 times more likely to sustain a spinal cord injury following a vertebral fracture[7]. Despite these complications the recommended treatment is surgical fixation to achieve fracture reduction and healing with minimal loss of mobility. Choosing conservative management as an alternative with halo orthosis immobilisation also carries a high risk of pseudo-arthritis. Moreover regardless of the approach the possibility for non-union remains significant.

A novel conservative management for bone fractures is Teriparatide (Forsteo, Eli Lilly & Co Ltd, Liverpool, England), a

\* Corresponding author at: Whipps Cross University Hospital, Barth Health NHS Trust, Whipps Cross Road, London E11 1NR, UK.

E-mail address: [izolda.biro@bartshealth.nhs.uk](mailto:izolda.biro@bartshealth.nhs.uk) (I. Biro).

recombinant human parathyroid hormone (PTH 1-34)[8]. It is a subcutaneous injection that at a daily dose of 20 micrograms is indicated for the treatment of osteoporosis in postmenopausal women[9]. It has also been approved by the National Institute for Health and Care Excellence as primary prophylaxis in high-risk male population and corticosteroid induced osteoporosis. There are reported cases of Teriparatide healing osteoporotic fractures. Accelerated bone healing was observed in patients with bilateral sacral stress fractures [10] and lower leg fractures [11]. It has also shown beneficial effects in a patient with AS following a failed surgical intervention [12].

### Clinical case

We present the case of a 56 year-old Caucasian man diagnosed with AS in his early thirties. He was born in the UK and lived in the Philippines for five years before returning to the UK. He works as a fabricator welder which involves a significant amount of manual work. He first presented to our Rheumatology Outpatient Clinic in 2011 with a 20 year history of Ankylosing Spondylitis. At the age of 17 he suffered a motorcycle accident and sustained skull, right femoral fractures and pneumothorax. He had a 10-pack-year smoking history, no significant alcohol or drug consumption and a medical history that was unremarkable for chronic medical conditions. At his initial visit he had a Bath Ankylosing Spondylitis Activity Index (BASDAI) score of 8.0, a Spinal Pain VAS score of 8 and reported two episodes of uveitis. He failed three anti-inflammatory medication, namely Indomethacin, Naproxen and Etoricoxib at recommended doses for the management of inflammatory spondylarthropathies. He was then initiated on an IL-17 inhibitor, as biological therapy started to become a recognised and safe treatment option for patients with inflammatory arthropathies.

He had a good therapeutic response to the anti-IL-17 monoclonal antibody, Secukinumab (Cosentyx, Novartis Pharmaceuticals,

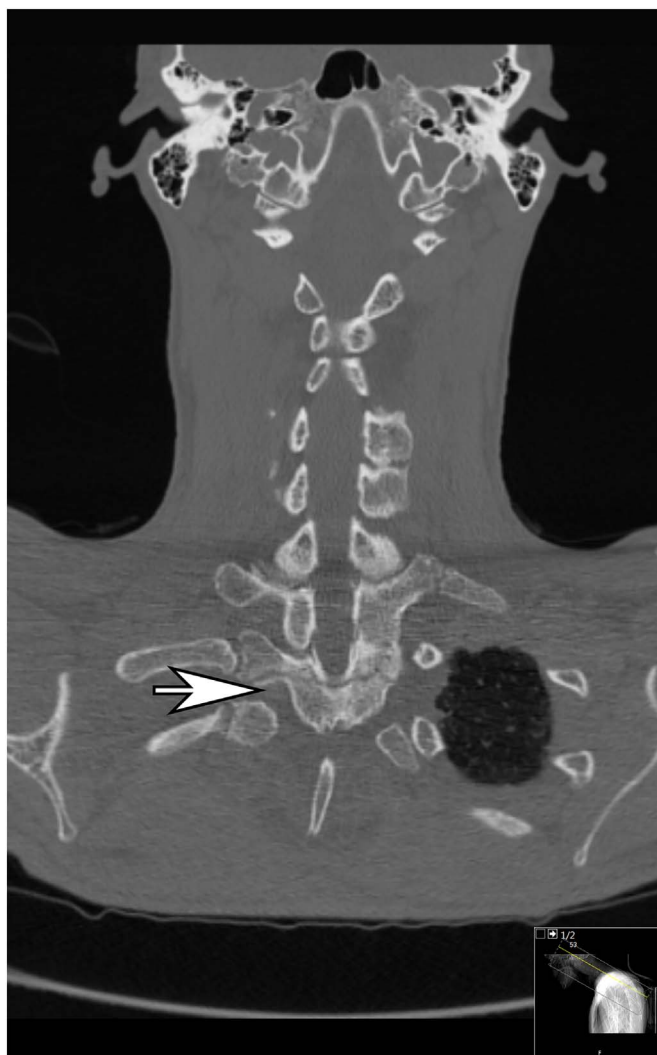


Fig. 1. Three column fracture of T2 vertebra in Ankylosing Spondylitis. Coronal view.  
T2 vertebral fracture in a patient with Ankylosing Spondylitis. Sagittal view.

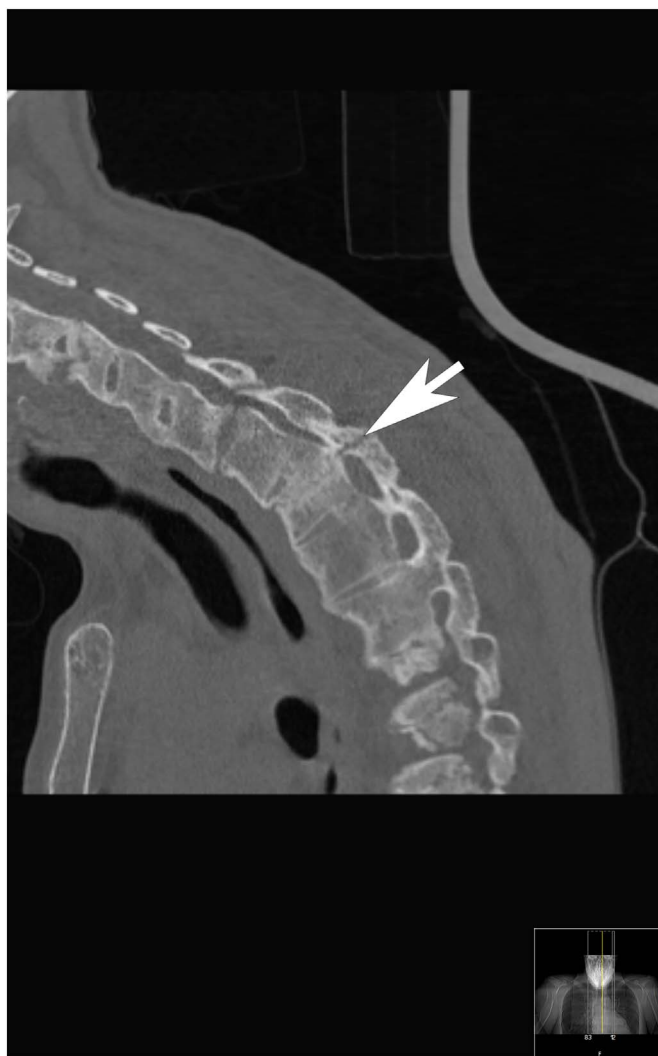


Fig. 1. (continued)

Basel, Switzerland) with a BASDAI score of 3.07 and a Spinal VAS score of 2.8 after one year. In 2012 he suffered a traumatic hyperextension injury after a metal plate fell on his head at work.

He sustained an undisplaced fracture of the C5 vertebral body and a transverse fracture of T2 vertebral body. The initial report of his CT scan was reviewed by a radiologist with special interest in musculoskeletal disorders who did not confirm fracture at C5 level based on the available images however he did support the diagnosis of a new three column fracture of T2. (Fig. 1 - Coronal) The T2 fracture extended into both pedicles and laminae. (Fig. 1 - Sagittal) Urgent fixation surgery was recommended. The consulting surgeon believed surgery was highly indicated as the fracture was unstable and posed significant risk of neurological damage. Following informed consent and risk and benefit assessment of both surgical and medical approaches the patient opted for a conservative treatment. He declined elective procedure as well in fear of complications (i.e. paralysis and death) and was placed in halo-orthosis immobilisation. A bone densitometry scan showed mild femoral neck osteopenia (total T-score:  $-0.9$ ) but no evidence of osteoporosis at this site nor at the level of the lumbar spine (spinal total T score:  $0.1$ ). He was commenced on subcutaneous Teriparatide (PTH 1-34) 20 mg daily for six months and physiotherapy.

The patient gradually mobilised and was pain free within two months of starting Teriparatide.

Following six months of treatment with Teriparatide a repeat CT scan showed complete healing of the T2 fracture. (Fig. 2 - Coronal, Fig. 2 - Sagittal).

## Discussion

Teriparatide is a well-established treatment for severe post-menopausal osteoporosis. It is an anabolic agent promoting bone metabolism through the enhancement of osteoblast proliferation [13].

Accelerated healing following failed surgical intervention of cervical [14] and femoral fractures in non-AS subjects [15] was reported after treatment with Teriparatide. Sacral insufficiency fractures were also healed following “off-label” use of Teriparatide [16].

A reduction in the rate of new-onset adjacent vertebral compression fracture following percutaneous vertebroplasty [17], and improvement in bone quality and healing of atypical femoral fractures associated with bisphosphonate therapy [18] were also attributed to consequent Teriparatide therapy.

The use of Teriparatide in an AS patients with cervical fracture following unsuccessful surgical intervention has been reported recently [19].

This case report is unique as complete fracture healing was achieved without complications and without preceding surgical fixation.

To note is that our patient was also receiving Secukinumab during his treatment with Teriparatide. Randomised placebo controlled trials show good clinical improvement in AS with Secukinumab [20] however there is no evidence supporting its role in fracture healing.

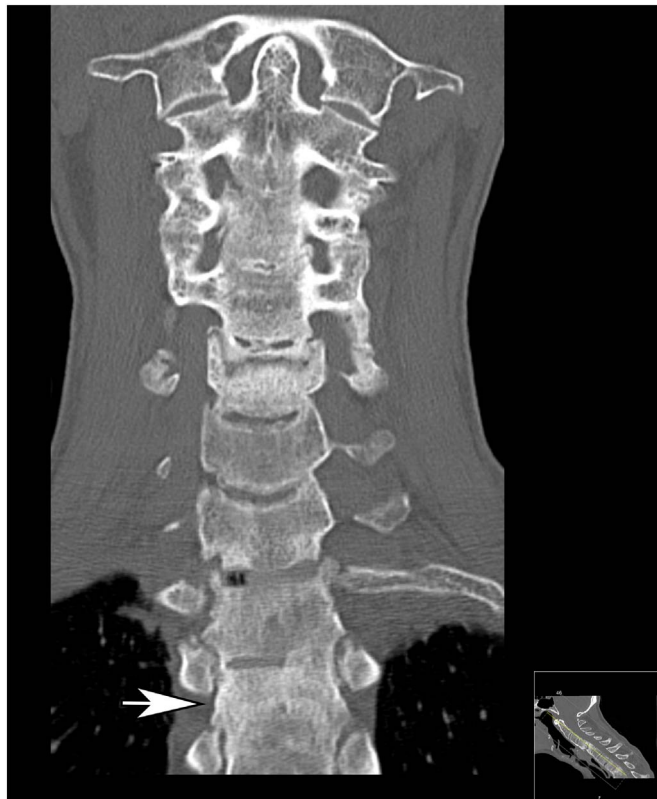

Fig. 2. Healed T2 vertebra. Coronal view.  
Healed T2 vertebra. Sagittal view.

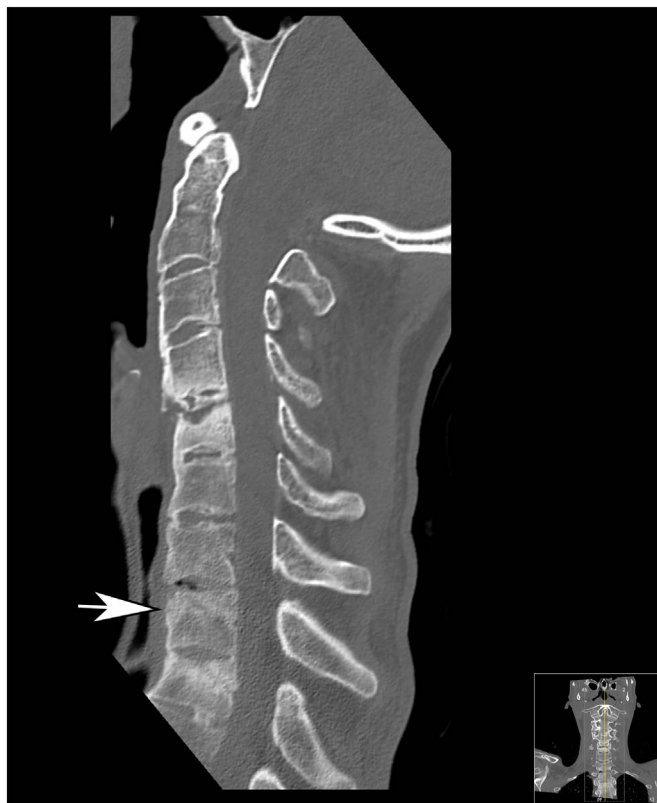

Fig. 2. (continued)

## Conclusion

This report provides further evidence of Teriparatide accelerating bone healing in AS related vertebral fractures. Structured evidence of its beneficial effects and safety is required in order to allow its full implementation in general practice.

As it represents an alternative non-surgical treatment an open label comparison study with surgical treatment methods is equally justified.

## References

- [1] J. Braun, J. Sieper, Ankylosing spondylitis, *Lancet* 369 (2007) 1379–1390, [http://dx.doi.org/10.1016/S0140-6736\(07\)60635-7](http://dx.doi.org/10.1016/S0140-6736(07)60635-7).
- [2] B.A. Winkelstein, B.S. Myers, The biomechanics of cervical spine injury and implications for injury prevention, *Med. Sci. Sports Exerc.* 29 (1997) S246–S255, <http://dx.doi.org/10.1097/00005768-1997-07001-00007>.
- [3] T. Caron, R. Bransford, Q. Nguyen, et al., Spine fractures in patients with ankylosing spinal disorders, *Spine* 35 (2010) 11.
- [4] T. Einsiedel, A. Schmelz, M. Arand, et al., Injuries of the cervical spine in patients with ankylosing spondylitis: experience at two trauma centers, *J. Neurosurg. Spine* 5 (2006) 33–45.
- [5] Saad B. Chaudhary, Heidi Hullinger, Michael J. Vives, Management of acute spinal fractures in ankylosing spondylitis. International Scholarly Research Network, *ISRN Rheumatol.* (2011), <http://dx.doi.org/10.5402/2011/150484> (Article ID 150484, 9 pp.).
- [6] L.A. Westerveld, J.J. Verlaan, F.C. Oner, Spinal fractures in patients with ankylosing spinal disorders: a systematic review of the literature on treatment, neurological status and complications, *Eur. Spine J.* 18 (2009) 145–156.
- [7] P. Kouyoumdjian, P. Guerin, C. Schaeferle, et al., Fracture of the lower cervical spine in patients with ankylosing spondylitis: retrospective study of 19 cases, *Orthop. Traumatol. Surg. Res.* 98 (5) (2012) 543–551.
- [8] British National Formulary, Calcitonin and parathyroid hormone, Teriparatide, (2013), pp. 490–491.
- [9] NICE guidelines, Alendronate, Etidronate, Risedronate, Raloxifene, Strontium Ranelate and Teriparatide for the Secondary Prevention of Osteoporotic Fragility Fractures in Postmenopausal Women, (2011).
- [10] S. Baillieux, M. Guinot, C. Dubois, A. Prunier, F. Mahler, P. Gaudin, Set the pace of bone healing - treatment of a bilateral sacral stress fracture using teriparatide in a long-distance runner, *Joint Bone Spine* (2016), <http://dx.doi.org/10.1016/j.jbsp.2016.07.001> (pii: S1297-319X(16)30114-2. 2016 Jul 28).
- [11] Ilko Kastir, Sebastian Radmer, Reimer Andresen, Hans-Christof Schober, Osseous consolidation of an aseptic delayed union of a lower leg fracture after parathyroid hormone therapy – a case report, *J. Clin. Diagn. Res.* 10 (7) (2016) RD03–RD05 (2016 Jul).
- [12] F.S. Cortés, M.A. Lorente, B.P. Perez, et al., Surgical failure in patient with cervical fracture and ankylosing spondylitis treated with teriparatide to try to augment consolidation, *Acta Neurochir.* 155 (10) (2013) 1955–1956.
- [13] N.S. Datta, Osteoporotic fracture and parathyroid hormone, *World J. Orthop.* 2 (8) (2011) 67–74.
- [14] P.T. Rubery, S.V. Bukata, Teriparatide may accelerate healing in delayed unions of type III odontoid fractures: a report of 3 cases, *J. Spinal Disord. Tech.* 23 (2) (2010) 151–155.
- [15] Y.M. Alkhiary, L.C. Gerstenfeld, E. Krall E Krall, et al., Enhancement of experimental fracture-healing by systemic administration of recombinant human parathyroid hormone (PTH 1-34), *J. Bone Joint Surg.* 87 (4) (2005) 731–741.
- [16] C.C. Wu, J.C. Wei, C.P. Hsieh, et al., Enhanced healing of sacral and pubic insufficiency fractures by teriparatide, *J. Rheumatol.* 39 (2012) 1306–1307.

- [17] Y.Y. Tseng, C.H. Su, T.N. Lui, et al., Prospective comparison of the therapeutic effect of teriparatide with that of combined vertebroplasty with antiresorptive agents for the treatment of new-onset adjacent vertebral compression fracture after percutaneous vertebroplasty, *Osteoporos. Int.* 23 (2012) 1613–1622.
- [18] C.Y. Chiang, R.M. Zebaze, A. Ghasem-Zadeh, et al., Teriparatide improves bone quality and healing of atypical femoral fractures associated with bisphosphonate therapy, *Bone* 52 (1) (2013) 360–365.
- [19] F.S. Cortés, M.A. Lorente, B.P. Perez, et al., Surgical failure in patient with cervical fracture and ankylosing spondylitis treated with teriparatide to try to augment consolidation, *Acta Neurochir.* 155 (10) (2013) 1955.
- [20] D. Baeten, J. Sieper, J. Braun, X. Baraliakos, et al., Secukinumab, an interleukin-17A inhibitor, in ankylosing spondylitis, *N. Engl. J. Med.* 373 (26) (2015) 2534–2548 (doi: 10.1056. 2015 Dec 24).