

Case Report

Mandibular intraosseous schwannoma in a child: Report of a rare case

Neda Kargahi¹, Seyed Mohammad Razavi¹, Darioush Hasheminia¹, Forouz Keshani¹, Mehran Safaei², Zahra Hashemzadeh¹

¹Torabinejad Dental Research Center and Department of Oral and Maxillofacial Pathology, School of Dentistry, Isfahan University of Medical Science, Isfahan, ²Department of Dental Radiography, School of Dentistry, Rafsanjan University of Medical Science, Kerman, Iran

Received: January 2012

Accepted: June 2012

Address for correspondence:
Dr. Zahra Hashemzadeh,
Torabinejad Dental Research
Center and Department
of Oral and Maxillofacial
Pathology, Isfahan University
of Medical Sciences, Isfahan,
Iran.
E-mail: dr.hashemzade@
yahoo.com

ABSTRACT

Intraosseous schwannomas is a very rare neoplasm, and less than 50 cases have been reported in the medical literature. In this article, the clinical, radiographic and histopathologic appearances of a rare case of intraosseous schwannomas are presented. The importance of this case is that other benign central lesions such as odontogenic tumors and cysts might be included in differential diagnosis. This case was recognized in a 9-year-old child, which is a very rare occurrence. The diagnosis was confirmed by immunohistochemical staining with S100 protein.

Key Words: Immunohistochemistry, intraosseous schwannoma, mandible, S100 protein

INTRODUCTION

Schwannoma is a benign nerve sheath tumor originating from Schwann cells, and is known as neurilemmoma and neurinoma.^[1,2] Although the head and neck region is a rather common site for these benign lesions, intraoral schwannomas, especially the intraosseous types, are very rare, and can account for less than 1% of the benign intraosseous neoplasms.^[1,3,4] The clinical and radiographic findings of intraosseous schwannoma may be similar to many other lesions such as odontogenic cysts and other benign tumors.^[2] Therefore, various differential diagnoses have been proposed, which may lead to some sort of confusion in its diagnosis. According to the observation in the literature, these lesions are more common in the mandible and among females, which are mostly observed in the 2nd and 3rd decades of life.^[1-4]

Here, along with a review of the related literature, we try to present a case of intraosseous schwannomas that has been recognized in a 9-year-old boy.

CASE REPORT

The patient was a 9-year-old boy who was referred to the Department of Oral and Maxillofacial Pathology of the Isfahan University of Medical Science 5 months ago, while complaining about a swelling in the inferior border of the right mandible. There were no associated symptoms like pain and paresthesia. Deviation of anterior teeth and looseness of teeth (D, E) were seen.

In the panoramic radiograph, radiolucency with sclerotic border from mesial of tooth 36 to distal of 3C and transposition of first and second impacted premolar was observable [Figure 1].

Axial computed tomography scan revealed a unilacunar lesion in the left mandibular body, 2.5 × 3 cm in size, with a well-defined border, marked expansion and thinning of the buccal and lingual cortical plates [Figure 2].

First, on the basis of clinical and radiographic features, we can suggest the following lesions: Keratocystic odontogenic tumor, central giant cell granuloma, unicystic ameloblastoma and ameloblastic fibroma.

Access this article online



Website: www.drj.ir

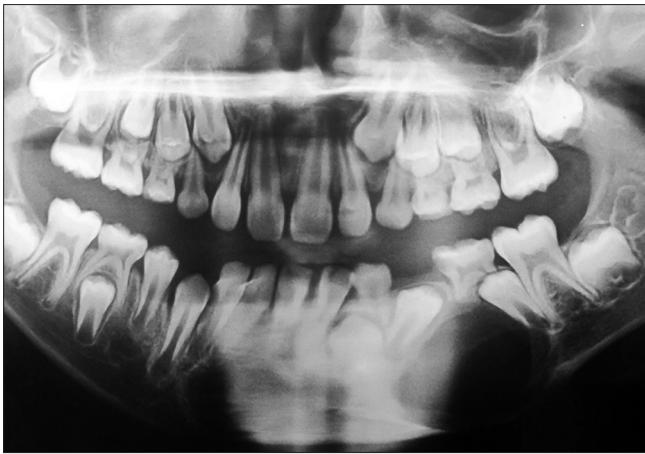

Figure 1: Radiolucency with sclerotic border from mesial of tooth 36 to distal of 3C in the panoramic radiograph

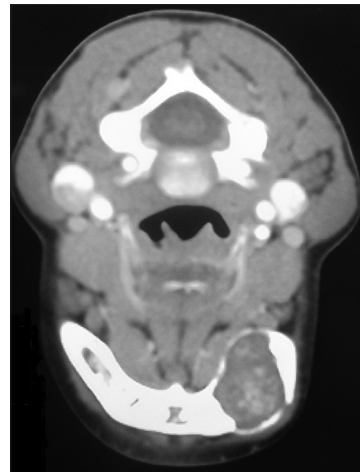


Figure 2: Unilocular lesion in the left mandibular body, 2.5 x 3 cm in size, with well-defined border in axial CT scan

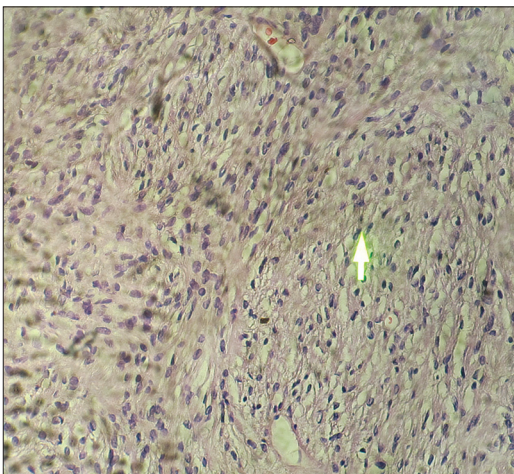


Figure 3: Histologic features of the lesion. Antoni A: Palisading arrangement of spindle cell, Verocay body, Antoni B: Spindle cells haphazardly distributed in a delicate fibrillar matrix. H and E: Original magnification (x40)

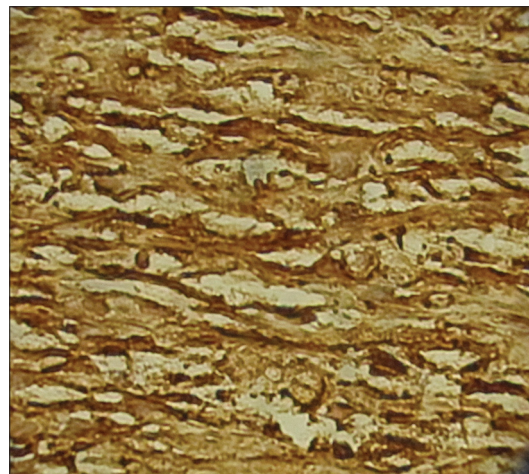


Figure 4: Immunohistochemical (IHC) staining: Strongly expression of S100 protein in Schwann cell. Original magnification (x400)

No any special problem in both family history and routine hematologic tests was observed. Excisional biopsy was performed and irregular masses of solid tissues were observable during biopsy.

In the histopathology features, ovoid to spindle shape and epithelioid cells were identified, some of which indicated slight pleomorphism and hyperchromatism. The cells showed, in some of the regions, a palisading arrangement. Besides, some regions showed intracellular edema and degenerative changes. In some parts, numerous blood vessels and perivascular hyalinization were identified, and typical capsule was not evident [Figure 3].

Based on histopathologic features, several differential diagnoses were first taken into account: Benign

fibroblastic tumor, benign neural tumors and neoplastic vascular lesions.

In order to reach final diagnosis, immunohistochemical staining was carried out. The findings revealed that the intensity of S100 staining was 4+ and those of Ki67 was weak and 10% at most [Figure 4]. According to these studies and immunohistochemistry, and regarding clinical and radiographic features and hematoxylin and eosin, in which there were some regions similar to Antoni A with palisading cells and similarities of some regions to Antoni B, we reached the final and definite diagnosis of the lesion.

After 4 months, the patient was evaluated by taking panoramic radiography, and it seems that reparative

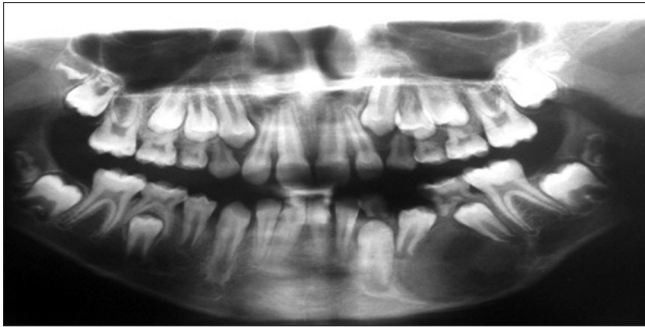


Figure 5: Panoramic radiography feature after 4 months: Healing process observed

process is running within the lesion [Figure 5].

DISCUSSION

Schwannoma was first described as neurinoma by Verocay in 1910.^[3] Stout in 1935 proposed the term neurilemmoma instead.^[4] Today, these terms are used to name benign encapsulated nerve sheath tumors.^[2,3] Although schwannoma is a benign and slow growing tumor, and it is usually an asymptomatic one, almost 50% of the cases have been reported with pain.^[1] The most common site of this tumor in the head and neck region is the tongue. Moreover, the intraosseous type is extremely rare, and accounts for less than 1% of all primary bone tumors.^[1-4] The most common clinical manifestation is swelling. Average age of the people afflicted is 34 years, and the male to female ratio is 1:1.5.^[1,2,4]

Lesions are more common in the mandible than in the maxilla, and the swelling usually involves the body of the mandible. So far, fewer than 50 cases have been recorded in the related literature, of which 44 cases have been reported by Chi *et al.*^[5] In this report, the clinical features of these cases have been described, and only one case was younger than 10 years old.^[5] Our case is a 9-year-old boy, which appears to be extremely rare. Schwannoma can be originating from all cranial nerves, with the exception of the olfactory and optic nerves. This is partly because the olfactory and optic nerves lack Schwann's cells.^[6] The tumor presents an expansive growth pattern, which may cause dislocation of teeth and may also involve the nerves.^[3] There is no pathognomonic radiological feature for intraosseous schwannoma. It shows a well-defined, unilocular radiolucency with a thin sclerotic border.^[4] These above-mentioned features were also observed in the case under investigation in this study. But, the

problem was that due to the scarcity of such cases, it was not possible for us to predict the schwannoma in differential diagnosis at first. In microscopic features, schwannoma is an encapsulated tumor that shows two microscopic patterns: Antoni A and Antoni B. Streaming fascicles of spindle-shaped Schwann cells characterize Antoni A tissue. These cells often form a palisaded arrangement around the central acellular, eosinophilic areas, identified as Verocay bodies.^[2,4,7]

Antoni B pattern is less cellular and the spindle cells are randomly arranged within a loose, myxomatous stroma. Schwannoma indicates the positivity of S100, CD34 and EMA only in capsules of the tumor.

In our case, the initial clinical-radiographic diagnoses were totally rejected after identifying histopathologic features. The lesion showed tumoral appearance, which was completely different from the characteristic structures of odontogenic cysts or tumors. Also, specific types of cell, such as giant cells, were not obvious. The lesion showed spindle cell pattern in most of the places, which was similar to fibroblastic or neural cells. Immunohistochemistry revealed the tumor to be positive for the S100 protein, confirming nerve origin.^[1-4]

On the basis of schwannoma, two characteristic patterns: Observing typical limited area similar to Antoni A despite verocay body was not clearly seen, and other regions akin to Antoni B pattern, the diagnosis of schwannoma was made.

The present of these two important histopathologic patterns, lack of mast cells, which is one of the most helpful features in neurofibroma and also diffuse, strongly positively tumoral cells S100 expression in IHC slides, the diagnosis of neurofibroma was rejected.^[8]

Neurofibroma shows sparsely S100 positive pattern.^[8]

It is probable that some malignant changes in schwannoma may happen, even though some malignant cases have been reported.^[2,4] Ancient schwannoma is a rare chronic type in which degenerative changes can noted. It was first introduced by Ackerman and Taylor in 1951.^[9] These changes consist of cyst formation, necrosis, hyalinization, hemorrhage, hemosiderin deposits, inflammation, fibrosis and nuclear atypia.^[10] Nonetheless, these tumors are benign and atypical mitosis are never seen, and the pathologist must be cautious not to mistake these changes for evidence of a malignancy.^[11]

Treatment of intraosseous schwannoma is surgical excision with periodical follow-up. Also, it is possible to remove the involved nerve in order to decrease the risk of recurrence.^[2,4,5]

CONCLUSION

Because this lesion can be misdiagnosed clinically, radiographically and microscopically as periapical lesion, ameloblastoma, myxoma and central giant cell granuloma, careful attention should be directed toward reaching the diagnosis. Only then can the appropriate treatment can be obtained.

REFERENCES

1. Bansal AK, Bindal R, Shetty DC, Dua M. Rare occurrence of intraosseous schwannoma in a young child, its review and its pathogenesis. *J Oral Maxillofac Pathol* 2012;16:91-6.
2. Minowa K, Sakakibara N, Yoshikawa K, Ohmori K, Kitagawa Y, Inoue N, *et al.* CT and MRI findings of intraosseous schwannoma of the mandible: A case report. *Dentomaxillofacial Radiology* 2007;36:113-6.
3. Martins MD, Taghloubi SA, Bussadori SK, Fernandes KP, Palo RM, Martins MA. Intraosseous schwannoma mimicking a periapical lesion on the adjacent tooth: Case report. *Int Endod J* 2007;40:72-8.
4. Patil K, Mahima V, Srikanth H, Saikrishna D. Central schwannoma of mandible. *J Oral Maxillofac Pathol* 2009;13:23-6.
5. Chi AC, Carey J, Muller S. Intraosseous schwannoma of the mandible: A case report and review of the literature. *Oral Surg Oral Med Oral Pathol Oral Radiol Endod* 2003;96:54-65.
6. Wakoh M, Yonezu H, Otonari T, Sano T, Matsuzaka K, Inoue T, *et al.* Two cases of schwannoma with marked cystic changes. *Dentomaxillofac Radiol* 2005;34:44-50.
7. de Lacerda SA, Brentegani LG, Rosa AL, Vespúcio MV, Salata LA. Intraosseous schwannoma of mandibular symphysis: Case report. *Braz Dent J* 2006;17:255-8.
8. Neville B, Damm D, Allen C, Bouquot J. *Oral and Maxillofacial Pathology*. 2nd ed. Philadelphia: WB Saunders Co; 2009. p. 526-9.
9. Nakano CG, Massarollo LC, Volpi EM, Barbosa Junior JG, Arias V, Ueda RY. Ancient schwannoma of the vagus nerve, resection with continuous monitoring of the inferior laryngeal nerve. *Braz J Otorhinolaryngol* 2008;74:316.
10. Choudry HA, Nikfarjam M, Liang JJ, Kimchi ET, Conter R, Gusani NJ, *et al.* Diagnosis and management of retroperitoneal ancient schwannomas. *World J Surg Oncol* 2009;7:12.
11. Jahanshahi G, Haghghat A, Azmoodeh F. Intraosseous neurilemmoma of the mandible: Report of a rare ancient type. *Dent Res J (Isfahan)* 2011;8:150-3.

How to cite this article: Kargahi N, Razavi SM, Hasheminia D, Keshani F, Safaei M, Hashemzadeh Z. Mandibular intraosseous schwannoma in a child: Report of a rare case. *Dent Res J* 2012;9:119-22.

Source of Support: Nil. **Conflict of Interest:** None declared.