



# A Limb-Saving Procedure for Treatment of Arterial Cement Embolism during Lumbar Percutaneous Vertebroplasty: A Case Report

Seyed Hashem Sezavar Seyed Jandaghi, MD<sup>1\*</sup>, Hesam Abdolhoseinpour, MD<sup>2</sup>, Afshin Ghofraniha, MD<sup>3</sup>, Navid Tofghirad, MD<sup>4</sup>, Enseyeh Dogmehchi, MD<sup>1</sup>, Hamidreza Goodarzynejad, MD<sup>5</sup>

<sup>1</sup>Hazrat Rasool Hospital, Tehran University of Medical Sciences, Tehran, Iran.

<sup>2</sup>Bou Ali Hospital, Tehran Medical Branch of Islamic Azad University, Tehran, Iran.

<sup>3</sup>Laleh Hospital, Tehran, Iran.

<sup>4</sup>Amir-Al-Momenin Hospital, Tehran Medical Branch of Islamic Azad University, Tehran, Iran.

<sup>5</sup>Tehran Heart Center, Tehran University of Medical Sciences, Tehran, Iran.

Received 31 October 2011; Accepted 27 June 2012

## Abstract

As the major hazard of percutaneous vertebroplasty (PV), cement extravasation into the venous system, systemic embolism, and spinal canal has been previously reported. However, to our knowledge, only one case of the arterial migration of cement has been previously reported that is directly associated with this technique without any symptom in the immediate post-intervention and in the follow-up period. An arterial embolus of cement occurred in a 46-year-old woman undergoing lumbar PV for breast cancer metastasis. Less than one hour later, the patient complained of severe pain and numbness in her left leg. A diagnosis of acute left leg ischemia due to the acute occlusion of the infrapopliteal arteries by the cement was made. Transluminal angioplasty (PTA) for the infrapopliteal arteries was recommended because there were diffuse and long vessel involvements, leaving no distal targets for bypass vascular surgery. The patient's postoperative course was uncomplicated; the extremity tenderness and mottled skin were improved. A follow-up ultrasound 2 months later revealed an acceptable distal flow in the arteries of the affected limb, and the patient remained asymptomatic (except for a mild leg pain on exertion) at the one-year follow-up examination. In conclusion, PTA may save the limb from amputation in case of peripheral arterial embolism caused by cement during PV.

*J Teh Univ Heart Ctr 2013;8(1):61-64*

**This paper should be cited as:** Sezavar Seyed Jandaghi SH, Abdolhoseinpour H, Ghofraniha A, Tofghirad N, Dogmehchi E, Goodarzynejad H. A Limb-Saving Procedure for Treatment of Arterial Cement Embolism during Lumbar Percutaneous Vertebroplasty: A Case Report. *J Teh Univ Heart Ctr 2013;8(1):61-64.*

**Keywords:** Vertebroplasty • Angioplasty • Polymethyl methacrylate

## Introduction

**P**ercutaneous vertebroplasty (PV) is a mini-invasive popular

technique for stabilization and relief of pain in compression fracture of the vertebra.<sup>1,2</sup> It involves the injection of polymethyl methacrylate (PMMA) cement into the vertebral body. The nature of this procedure

\*Corresponding Author: Seyed Hashem Sezavar Seyed Jandaghi, Laleh Hospital, Simaye Iran Street, Phase 5, Shahrake Gharb, Tehran, Iran. 14676  
Tel: +98 21 88369862. Fax: +98 21 88571081. E-mail: sezavarsh@yahoo.com.

offers lower risks compared to open surgery; however, although generally minor, complication rates range from 1 to 10%, with a higher rate of complications in metastatic patients as compared to osteoporotic or traumatic patients.<sup>3</sup>

The risk of cement extravasation into the venous system, systemic embolism, and spinal canal has been previously reported as the major hazard of PV.<sup>4-6</sup> Nevertheless, to the best of our knowledge, there is only one case of the arterial migration of cement during PV directly associated with this technique.<sup>7</sup> We report the first case of acute leg ischemia due to the arterial embolism of PMMA during PV, and describe our management.

## Case Report

The patient was a 46-year-old woman with a history of breast cancer 3 years earlier. She presented with a pathologic compression fracture in body and both pedicles of the third lumbar vertebra (L3), verified by bone scan and lumbar magnetic resonance imaging (MRI). The patient underwent PV with PMMA on July 27, 2009.

A vertebral body biopsy prior to cement injection was done, and the procedure was subsequently completed uneventfully using the bilateral transpedicular approach guided by C-arm fluoroscopy.

Within the first hour post-procedural period, while the patient was in the recovery room, she complained of abdominal pain, which improved within minutes, followed by severe pain and numbness in the left leg. The left foot of the patient was found to be pale and cold with the sign of developing mottling and cyanosis from the knee level down. The calf muscles were also tender on examination. She had no detectable arterial pulses below her left knee by palpitation, which was confirmed by an emergency Doppler examination revealing the complete lack of blood flow in both dorsalis pedis and posterior tibial arteries.

Consequently, the patient underwent the computed tomographic (CT) scan of the lower limbs and abdomen, which showed hyperdense foci (cement) in the anatomic site of the popliteal, anterior tibial, posterior tibial, and peroneal arteries as well as in the left L3 lumbar artery extending into the abdominal aorta situated above its bifurcation (Figure 1).

The diagnosis of acute left leg ischemia due to the acute occlusion of the 3 infrapopliteal arteries by cement was considered. A loading dose of 300 mg Aspirin and 450 mg Clopidogrel was given, intravenous (IV) heparin was chosen as a foundation anticoagulant, and lower limb angiography was immediately performed with vascular access obtained in the right femoral artery. The angiogram revealed scattered opacity in the otherwise normal left iliac and superficial femoral arteries. The proximal portions of the popliteal arteries had also acceptable blood flow but thereafter a cement cast existed causing a poor run-off from the popliteal

*fossa distally (Figure 2).*

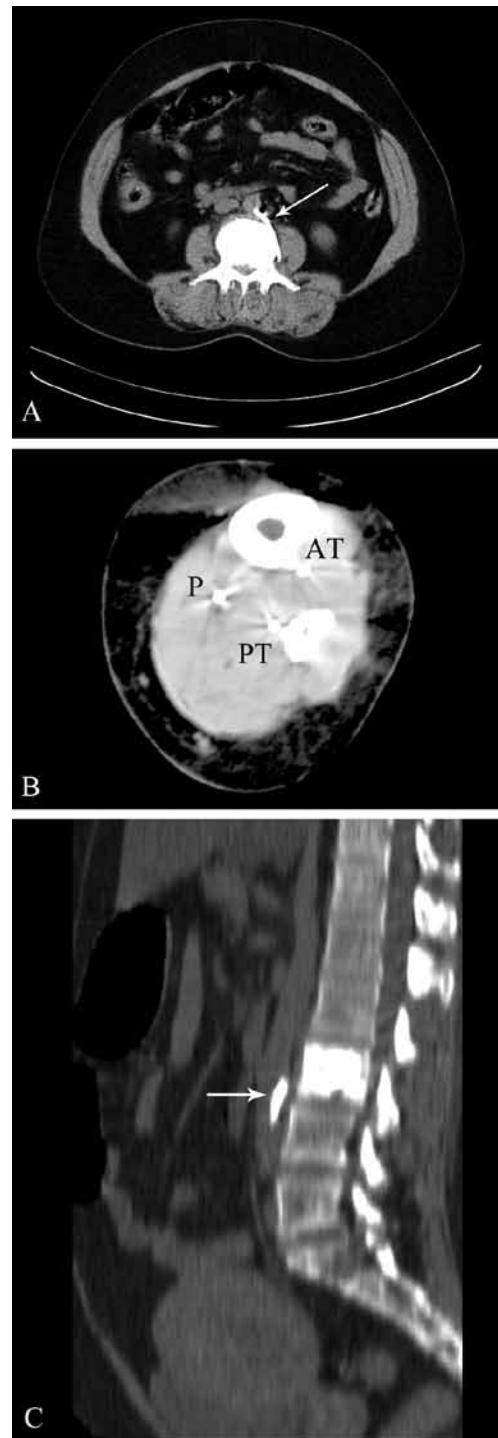


Figure 1. Abdominal and left leg CT scan without contrast: A, axial view with the bone setting at the level of the vertebroplasty demonstrates a leakage of acrylic cement in the lumbar artery supply to the aorta (long arrow); B, left lower limb CT reveals the cement embolus in the peroneal artery (P), anterior tibial artery (AT), and posterior tibial artery (PT); C, the thoracolumbar spine CT (sagittal view) shows the cement in the aorta (short arrow)

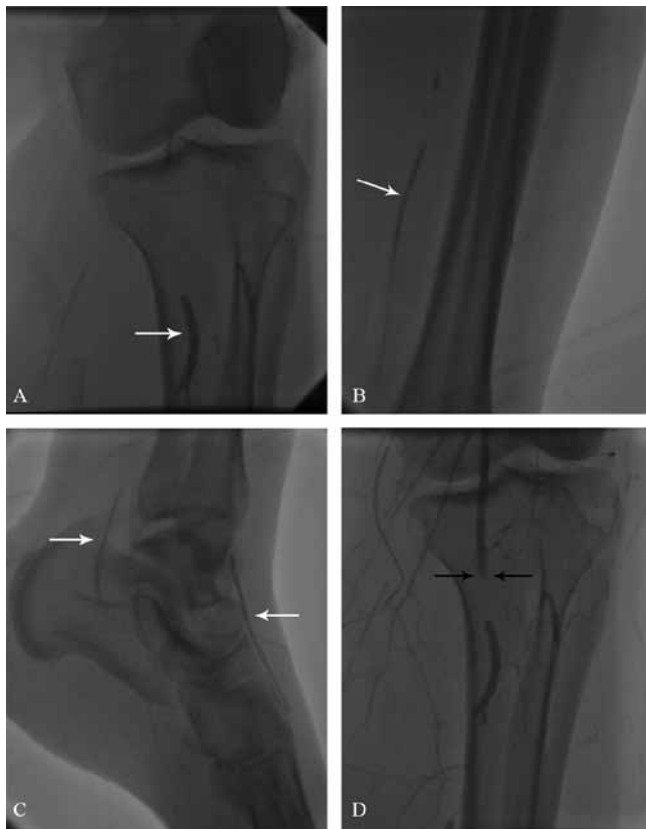
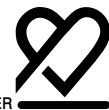
Figure 2. Angiogram before contrast medium injection, showing scattered opacity (cement) in the popliteal fossa (A), leg (B), and foot (C) on the left side (white arrows). After the injection of the contrast medium (D), no blood flow was observed from the popliteal fossa distally with an abrupt occlusion of the popliteal artery (black arrows)

After discussing the case with the vascular consultant, since there were diffuse and long vessel involvements and there were no distal targets for by-pass vascular surgery, we opted for transluminal angioplasty (PTA) of the infrapopliteal arteries. We used the crossover approach via the contralateral common femoral artery to access the infrapopliteal arteries. Multilevel intervention was performed through a long 6-F Shuttle sheath (Cook Medical), and total occlusions were traversed with 0.014-inch hydrophilic wires (Shinobi, Cordis, Miami, Florida).

We were able to dilate the lesions of the anterior tibial artery at its origin, proximal, and mid parts by utilizing a 2.5 mm × 120.0 mm Pacific Xtrime (Invatec, Rocandelle, BS, Italy) balloon, while the distal portions of this artery and the dorsalis pedis artery were repeatedly inflated with a 2.5 mm × 30 mm Sprinter balloon catheter (Medtronic, Inc., Minneapolis, Minnesota) (Figure 3A). Then in an effort to dilate the totally occluded posterior tibial artery at the bifurcation of tibioperoneal trunk, the balloon was attached to the cement lining in the artery wall, and part of its distal fragment remained in this vessel (Figure 3A). Finally, utilizing a 2.0 mm × 80.0 mm Amphirion Deep (Invatec,

Rocandelle, BS, Italy), balloon, angioplasty was performed for the peroneal artery with good results. The final imaging showed an acceptable blood flow in the anterior tibial artery, and in the tibioperoneal artery (Figure 3B). Although finally the occluded parts of the dorsalis pedis and peroneal arteries did not respond to balloon dilation, the flow to the distal bed seemed to have been improved significantly mainly by the collaterals from the proximal and mid parts of the anterior tibial artery and the peroneal arteries. The overall time in the Catheter Laboratory was about 3 hours. The patient's postoperative course was uncomplicated; the extremity tenderness and mottled skin were improved. An arterial duplex scan performed on postoperative day 5 showed normal velocities with mild stenosis in the 1/3 distal portions of the anterior and posterior tibial arteries. Also, no flow was observed in the dorsalis pedis artery. She was discharged on postoperative day 10 on Clopidogrel (75 mg/day) and Aspirin (80 mg/day). A follow-up ultrasound 2 months later revealed an acceptable distal flow in the arteries of the affected limb, and the patient remained asymptomatic (except for a mild leg pain on exertion) at the 1-year follow-up examination.

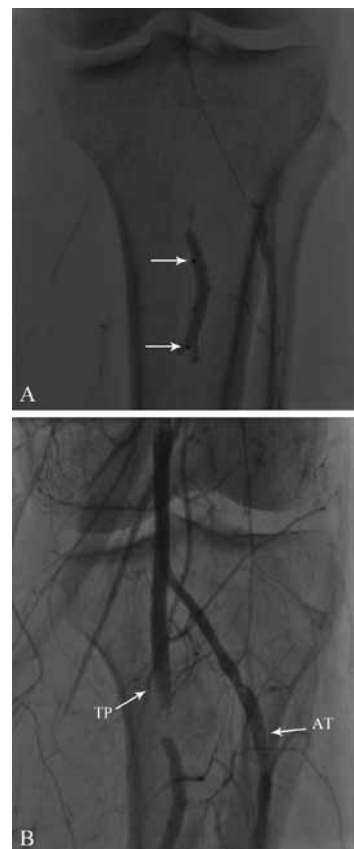


Figure 3. Re-establishment of the blood flow after successful angioplasty of the anterior tibial and peroneal arteries. While attempting to dilate the totally occluded posterior tibial artery, the tip of the balloon was torn off and its distal part remained at the bifurcation of the tibioperoneal trunk (A). Note the two balloon markers (arrows). The tibioperoneal trunk and proximal part of the anterior tibial artery have been opened (B)

## Discussion

We believe that our case is of interest inasmuch as, to the best of our knowledge, it is the first report of successful re-establishment of the blood flow by using PTA in an ischemic limb which resulted from a peripheral arterial cement embolization during PV.

Even though several cases of pulmonary or paradoxical embolism have been described due to the venous escape of cement during PV,<sup>4,5</sup> arterial cement leakage is quite a rare complication. Gangi et al. reported a leak of cement into an intercostal artery in only one case among a series of 863 patients undergoing PVP in which the leakage was asymptomatic.<sup>2</sup> Also, to our knowledge, only one case of arterial embolization of cement during PV has been reported in the literature.<sup>6</sup> One reason for that is the high arterial pressure preventing intra-arterial cement migration.

Moreover, in the case reported by Amoretti et al.,<sup>6</sup> the patient was asymptomatic in the immediate post-intervention period and at 4-months' follow-up. In contrast, a peripheral arterial acrylic cement embolism with acute leg ischemia and clinical consequence has been reported during intraoperative vertebroplasty.<sup>7</sup>

In the case reported by Amoretti and colleagues,<sup>6</sup> the aortal cement migration was attributed to the rich collateral arterial supply of the breast metastasis of the L3, which enabled the needle tip be placed in an enlarged intraosseous artery. In that case, the cement was polymerized before reaching the aorta and resulted in the attachment of the cement to the lumbar artery ostium within the aortic lumen.

In our case, no leakage was noted most probably because the cement was being washed by the blood flow, and the fact that the patient was overweight with poor image quality on fluoroscopy. The PMMA from the L3 filled the left lumbar artery, reached the abdominal aorta, where it was washed out into the distal abdominal aorta via the blood stream, and finally lodged at the left infrapopliteal arteries.

## Conclusion

Interventionists and surgeons should be aware of the possibility of direct arterial cement leakage during PV, particularly in hypervascularized lesions. Treatment options are limited for this very rare scenario and PTA below the knee may be the only chance to salvage the limb as was the case in our patient.

## Acknowledgement

We wish to express our thanks to all the nurses of the cardiac catheterization laboratory of Laleh Hospital, for their valuable help with data collection and patient care,

particularly Ms. F. Seifi and Mr. A. Hajopour. Our thanks are also due to Dr. M. Mahmoodian for technical assistance in preparing graphics.

## References

1. Murphy KJ, Deramond H. Percutaneous vertebroplasty in benign and malignant disease. *Neuroimaging Clin N Am* 2000;10:535-545.
2. Gangi A, Guth S, Imbert JP, Marin H, Dietemann JL. Percutaneous vertebroplasty: indications, technique, and results. *Radiographics* 2003;23:e10.
3. Chung SE, Lee SH, Kim TH, Yoo KH, Jo BJ. Renal cement embolism during percutaneous vertebroplasty. *Eur Spine J* 2006;15:590-594.
4. McGraw JK, Cardella J, Barr JD, Mathis JM, Sanchez O, Schwartzberg MS, Swan TL, Sacks D. Society of Interventional Radiology quality improvement guidelines for percutaneous vertebroplasty. *J Vasc Interv Radiol* 2003;14:S311-315.
5. Choe DH, Marom EM, Ahrar K, Truong MT, Madewell JE. Pulmonary embolism of polymethyl methacrylate during percutaneous vertebroplasty and kyphoplasty. *AJR Am J Roentgenol* 2004;183:1097-1102.
6. Amoretti N, Hovorka I, Marcy PY, Grimaud A, Brunner P, Bruneton JN. Aortic embolism of cement: a rare complication of lumbar percutaneous vertebroplasty. *Skeletal Radiol* 2007;36:685-687.
7. Soultanis K, Kakisis JD, Pyrovolou N, Lazaris AM, Vasdekis S, Soukagos P. Peripheral arterial embolization of cement during revision spine surgery. *Ann Vasc Surg* 2009;23:413 e419-412.