

Received: 2017.09.15
Accepted: 2017.11.11
Published: 2018.02.06

e-ISSN 1941-5923
© Am J Case Rep, 2018; 19: 133-136
DOI: 10.12659/AJCR.907144

Adenocarcinoma in a Blind Loop of the Ileum 53 Years After an Ileotransversostomy Procedure

Authors' Contribution:
Study Design A
Data Collection B
Statistical Analysis C
Data Interpretation D
Manuscript Preparation E
Literature Search F
Funds Collection G

DEF **Ryohei Takei**
EF **Ichiro Onishi**
F **Ryosuke Zaimoku**
D **Naoki Makita**
F **Yasumichi Yagi**
DEF **Masato Kayahara**

Department of Surgery, National Hospital Organization Kanazawa Medical Center,
Kanazawa, Ishikawa, Japan

Corresponding Author: Ryohei Takei, e-mail: ryohei_20@hotmail.com
Conflict of interest: None declared

Patient: Female, 84
Final Diagnosis: Ileal adenocarcinoma
Symptoms: Right lower quadrant abdominal pain
Medication: —
Clinical Procedure: Operation
Specialty: Gastroenterology and Hepatology

Objective: Rare disease

Background: Primary small bowel cancer is a rare malignancy; the common histopathological types are carcinoid and adenocarcinoma. Inflammatory bowel diseases and familial adenomatous polyposis are known risk factors for small bowel cancer. Additionally, cases of surgery-induced small bowel adenocarcinoma are sometimes reported after ileostomy.

Case Report: A 84-year-old woman, who had undergone ileotransversostomy for intestinal obstruction due to postoperative adhesion following appendectomy at the age of 31 years, was referred to our hospital for further examination after experiencing abdominal pain in the right lower quadrant for 2 weeks. Laboratory data showed elevated serum levels of carcinoembryonic antigen (CEA, 102.9 ng/ml) and carbohydrate antigen 19-9 (CA19-9, 104 U/ml). Enhanced computed tomography (CT) revealed a 10-cm mass in the terminal ileum and a distention of the ileum and colon in the blind loop, with retention of feces. The patient was suspected of having ileal cancer by preoperative examination; therefore, right hemicolectomy with en bloc resection was performed. The tumor was histopathologically diagnosed as a well-differentiated and mucinous adenocarcinoma of the ileum. At over 12 months after surgery, tumor recurrence had not been observed.

Conclusions: Difficulties in diagnosis can cause delays in treatment and lead to poor prognosis, mainly because tumors in the small bowel rarely cause clinical symptoms. Adenocarcinoma of the ileum should be considered in postoperative patients with ileotransversostomy.

MeSH Keywords: Adenocarcinoma, Mucinous • Abdominal Neoplasms • Intestinal Obstruction

Full-text PDF: <https://www.amjcaserep.com/abstract/index/idArt/907144>



1032



3



13



Background

Primary small bowel malignancy is rare, accounting for 1-3% of all gastrointestinal (GI) tract neoplasms [1]. The following histological types are reported: carcinoid (44% of cases), adenocarcinoma (33%), lymphoma (15%), and sarcoma (8%) [2]. Additionally, the frequency of tumors at different sites are: duodenum (57% of cases), jejunum (29%), and ileum (10%) [3], indicating a lower frequency in the distal portion of the small intestine.

The risk factors for small bowel malignancy are underlying Crohn disease, celiac disease, and familial adenomatous polyposis [4]. Additionally, cases of surgery-induced small bowel adenocarcinoma (SBA) are sometimes reported after ileostomy [5], suggesting that this type of operation is a possible risk factor for this disease. Clinical symptoms of small bowel cancer are nonspecific and are similar to those observed in most abdominal disorders, eventually leading to delayed diagnosis and treatment and consequently poor prognosis. Here, we report the first case of SBA arising in a blind loop of the ileum 53 years after an ileotransversostomy procedure.

Case Report

An 84-year-old woman was admitted to the gastroenterology department of our hospital with a 2-week history of right lower quadrant abdominal pain. She had undergone ileotransversostomy for intestinal obstruction due to postoperative adhesion following appendectomy at the age of 31 years. On physical examination, her abdomen was mildly distended and a palpable abdominal mass was detected with right lower quadrant pain on deep palpation. Laboratory data showed no anemia (hemoglobin, 13.3 g/dl) or leukocytosis (white blood cell count, $6.2 \times 10^9/L$ with 72.0% neutrophils), but she had elevated serum levels of carcinoembryonic antigen (CEA, 102.9 ng/ml) and carbohydrate antigen 19-9 (CA19-9, 104 U/ml). Enhanced computed tomography (CT) revealed a 10-cm mass in the terminal ileum and a distention of the ileum and colon in the blind loop, with retention of feces (Figure 1A). An ileotransversostomy was present in the upper abdomen (Figure 1A). Lymph node swelling, distant metastasis, peritoneal dissemination, and intra-abdominal free fluid were not observed. Upper GI tract radiography (UGI) showed circumferential narrowing of the lumen in the distal ileum (Figure 1B). Colonoscopy was attempted; however, only the bifurcation of the anastomosis after ileotransversostomy was visualized (Figure 2), owing to difficulties in passing the endoscope camera head further into the lumen. In light of elevated levels of tumor marker and a mass in the ileum revealed by CT, the patient was suspected of having ileal cancer and underwent surgery. During laparotomy, the tumor was observed to be involving the entire wall of

the terminal ileum, and multiple enlarged lymph nodes were present in the mesenteric root. No other visible lesions were identified. We performed right hemicolectomy with en bloc resection of the last 15 cm of the ileum (Figure 3A). No surgical complications were noted, so the patient was discharged on postoperative day 16. Macroscopic findings of the specimen showed that the tumor was localized in the terminal ileum and the ileocecal valve was intact. Microscopic findings revealed a well-differentiated and mucinous adenocarcinoma of the ileum (Figure 3B). The tumor invaded the serosal surface but free surgical margins were achieved. No lymph node metastasis was present. The pathological stage of the tumor was diagnosed as pT4pN0. Distant metastasis was not observed (M0), and the patient was diagnosed with stage IIB disease. Regular follow-up with CT scan and laboratory studies every 3 months has not revealed tumor recurrence in the 12 months after the operation.

Discussion

Adenocarcinoma of the ileum is a GI malignancy with low incidence, and is often derived from the distal ileum [6]. In general, small bowel malignant tumors are rarer than other GI malignancies. The possible reasons for this are: (1) small bowel contents have high fluidity, and the exposure duration and possible presence of carcinogenic agents are short and rare; (2) degrading enzyme (e.g., benzopyrene hydroxylase) activity of the carcinogen is higher than in the large bowel; (3) there are few anaerobic bacteria converting bile to active carcinogens; and (4) the small intestine has higher immunological surveillance [7,8].

We encountered this rare case of adenocarcinoma in the blind loop of the ileum after ileotransversostomy. In such a case, the epithelium of the distal ileum would have more chance of being exposed to carcinogens from the retained feces in the blind loop, which could induce chronic inflammation, tissue injury, and somatic gene mutations [9]. Alterations in gut immunity and intestinal flora by overgrowth of anaerobic bacteria such as *Bacteroides* and *Eubacterium* are also reported to cause small bowel carcinogenesis [10,11]. Therefore, a blind loop after reconstruction might cause intestinal carcinogenesis, and should be avoided in any situation.

The common symptoms of SBA are nonspecific: abdominal pain, nausea, vomiting, and occult GI bleeding. Diagnosis is difficult due to the absence of specific clinical presentation, such as in this case, and usually occurs on presentation of an emergency involving an occlusion (40%) or bleeding (24%) [2].

Diagnostic studies include UGI, ultrasonography, computed tomography (CT), magnetic resonance imaging (MRI), and GI

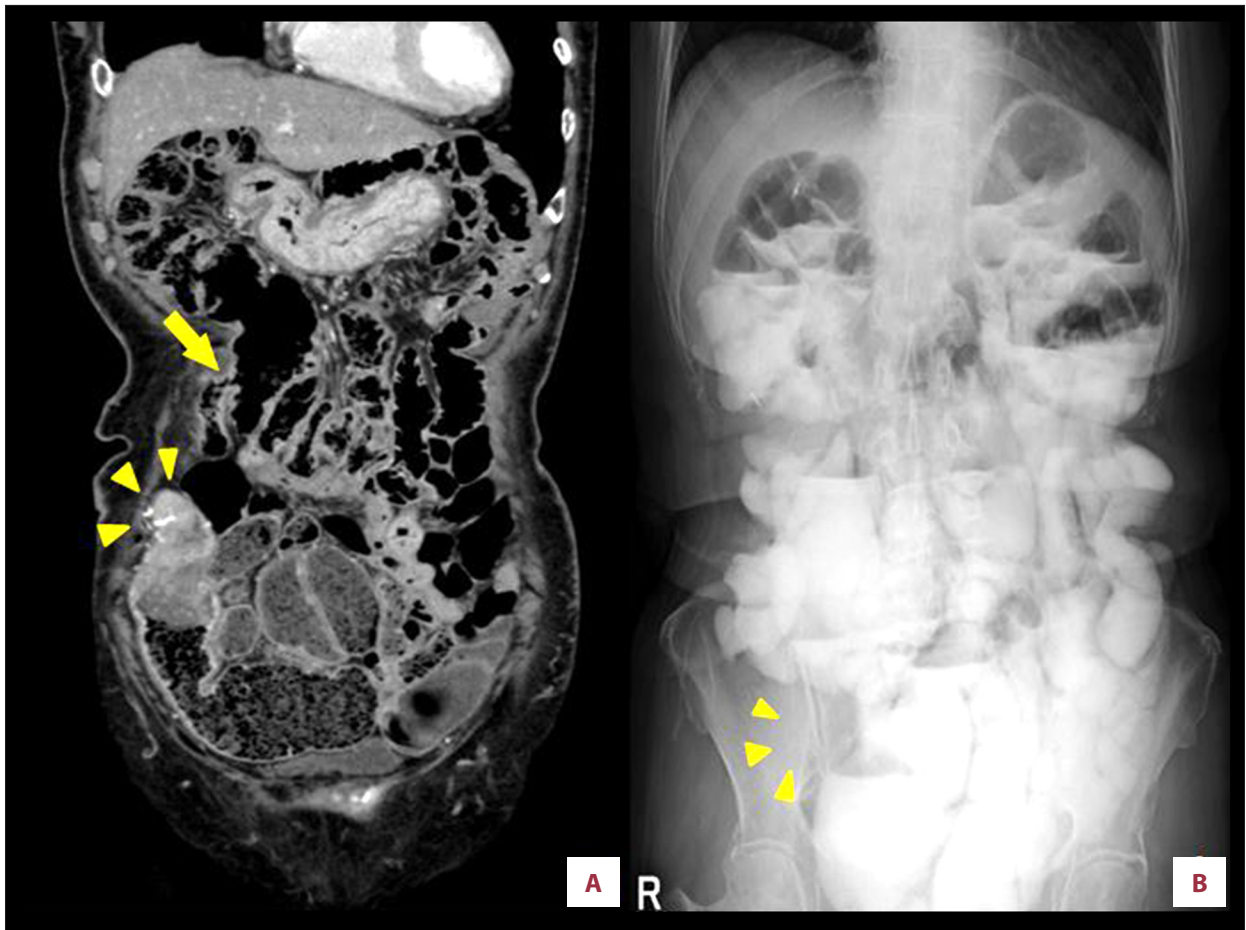


Figure 1. (A) Computed tomography scan image (coronal view) showing an enhanced tumor in the ileocecal area (arrowhead) and ileotransversostomy in the upper abdomen (arrow). (B) Upper gastrointestinal tract radiography showing occlusion in the lumen of the terminal ileum by a stenosing annular tumor.

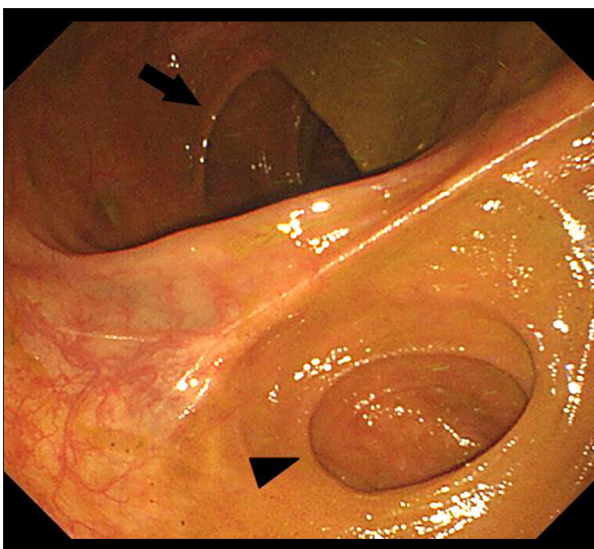


Figure 2. Colonoscopy showing an anastomosis of the distal ileum (arrowhead) to the transverse colon (arrow).

endoscopy. Gastroscopy and enteroscopy can be appropriate if the tumor is located close to the proximal duodenum or far from the terminal ileum. The rest of the small bowel cannot be accessed without the use of video capsule endoscopy or double-balloon enteroscopy. Recent advances in examination techniques such as imaging and endoscopy are improving the diagnostic rate of small intestinal adenocarcinoma.

Because of the difficulties in early detection and diagnosis of this particular cancer, prognosis for patients is poor; the median overall survival and 5-year survival rate are reported to be 20 months and 26%, respectively [2]. It is also reported that ~40% of patients have lymph node metastasis when they are diagnosed with SBA [12]. As with most digestive cancers, surgical resection with negative margins and regional lymphadenectomy are the primary treatment for localized SBA. There is no standard adjuvant chemotherapy for SBA, and the efficacy of any particular regimen is still unknown. Chemotherapy regimens similar to those used in colorectal cancer could also have an effect in SBA [13].

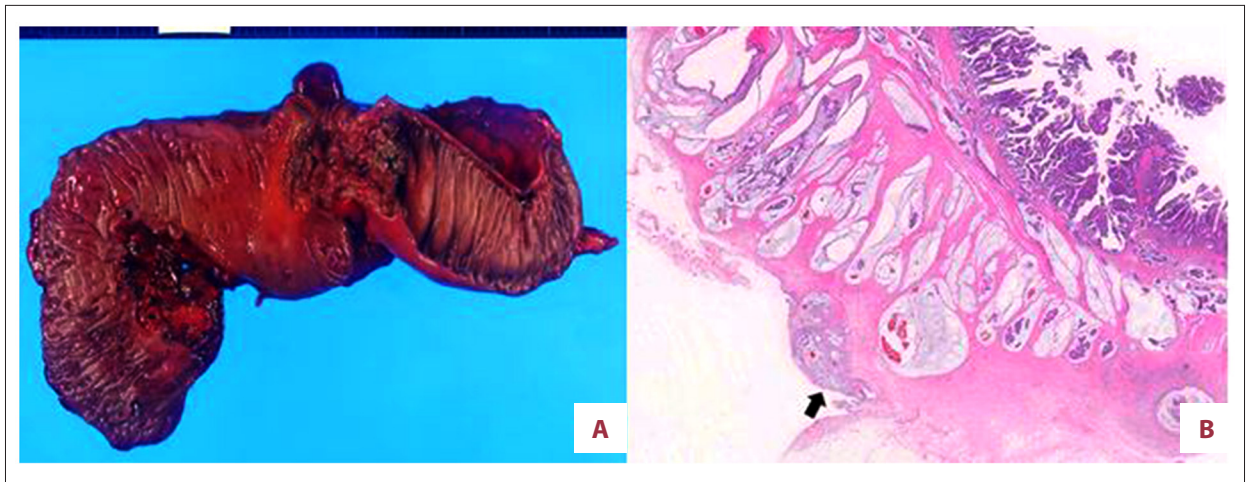


Figure 3. Pathological findings. (A) The resected specimen revealed a tumor localized in the terminal ileum. The tumor involved the entire wall of the ileum. (B) Microscopic image of the tumor showing a well-differentiated and mucinous adenocarcinoma of the ileum. Cancer cells invaded the serosal surface (arrow).

Conclusions

We report a very rare case of SBA arising in a blind loop of the ileum. Adenocarcinoma in the ileum should be considered in postoperative patients with ileotransversostomy, and early detection of this disease is important to improve patient outcomes.

References:

1. Howlader NNA, Krapcho M, Garshell J et al: SEER Cancer Statistics Review, National Cancer Institute, 1975–2011 [serial online] [cited 2017 Jan 16]. Available from: URL:<http://www.seer.cancer.gov>
2. Shenoy S: Primary small-bowel malignancy: Update in tumor biology, markers, and management strategies. *J Gastrointest Cancer*, 2014; 45: 421–30
3. Halfdanarson TR, McWilliams RR, Donohue JH, Quevedo JF: A single-institution experience with 491 cases of small bowel adenocarcinoma. *Am J Surg*, 2010; 199: 797–803
4. Dabaja BS, Suki D, Pro B, Bonnen M, Ajani J: Adenocarcinoma of the small bowel: Presentation, prognostic factors, and outcome of 217 patients. *Cancer* 2004; 101: 518–26
5. Quah HM, Samad A, Maw A: Ileostomy carcinomas a review: The latent risk after colectomy for ulcerative colitis and familial adenomatous polyposis. *Colorectal Dis*, 2005; 7: 538–44
6. Misawa S, Horie H, Kumano H et al: A clinicopathological study of 10 cases of primary small bowel adenocarcinoma. *J Jpn Soc Gastroenterol*, 2011; 108: 429–35
7. Speranza G, Doroshow JH, Kummar S: Adenocarcinoma of the small bowel: Changes in the landscape? *Curr Opin Oncol*, 2010; 22: 387–93
8. Hunahashi K, Teramoto R: Surgical disease data book: Small bowel malignant tumor. *Surgery*, 2007; 69: 1430–69
9. Suzuki H, Shibata C, Miura K et al: Two cases of ileal cancer arising at the ileostomy after total proctocolectomy for familial adenomatous polyposis. *Jpn J Gastroenterol Surg*, 2012; 45: 451–58
10. Kakisaka A, Hoshi T, Osanai M et al: Study of conversion of ileal tissue into colorectal tissue and changes in the intestinal flora in patients with ileal stoma. *Jpn J Surg Assoc*, 1996; 57: 23–29
11. Woefel GF, Campbell DN, Penn I, Reichen J, Warren GH: Inflammatory polyposis in an ileal blind loop. *Gastroenterology*, 1983; 84: 1020–24
12. Nishigori N, Koyama F, Nakagawa T et al: Five cases and 178 domestic reported cases of primary small intestinal cancers. *J Jpn Soc Coloproctol*, 2014; 67: 35–44
13. Ecker BL, McMillan MT, Datta J et al: Efficacy of adjuvant chemotherapy for small bowel adenocarcinoma: A propensity score-matched analysis. *Cancer*, 2016; 122: 693–701

Conflict of interest

None.