

# Lipoid proteinosis: Review of Indian cases

Jigna S Shah, Himali A Shah

Department of Oral Medicine and Radiology, Government Dental College and Hospital, Ahmedabad, Gujarat, India

## Abstract

Lipoid proteinosis (LP) is a rare autosomal recessive disorder characterized by the deposition of amorphous hyaline material in the dermis and submucosal connective tissue. To date <500 cases of LP have been described and oral manifestations described in a very few reports. Indian cases are much less reported and reviewed. Hence, here review of 51 Indian LP cases along with a case of histologically proven LP in 12-year-old male patient with typical skin, ocular, laryngeal, oral and radiographic features is done. Cases from 1969 to 2021 were collected using keyword LP on google and google scholar and Indian cases were analyzed afterward. Review with case presentation regarding oral manifestations will help the oral physician to diagnose LP in early stage.

**Keywords:** Indian cases, lipoid proteinosis, oral manifestations, oral physician, review

**Address for correspondence:** Dr. Himali A Shah, Department of Oral Medicine and Radiology, Government Dental College and Hospital, Ahmedabad, Gujarat, India.

E-mail: himalishah06@gmail.com

**Submitted:** 22-Jul-2021, **Accepted:** 05-Sep-2021, **Published:** 28-Jun-2022

## INTRODUCTION

Lipoid proteinosis (LP), also known as Urbach-Wiethe syndrome, (Hyalinosis cutis et mucosae), is a rare autosomal recessive disorder characterized by the deposition of amorphous hyaline material in the dermis and submucosal connective tissue.<sup>[1-3]</sup> First described by Urbach and Wiethe in 1929, originally as “Lipoidosis cutis et mucosae.” After decade, Urbach changed the term to “LP cutis et mucosae” believing that the condition was associated with abnormal lipid and protein deposition in various tissues. Since then attempts to characterize the biochemical alteration in LP have not yield pathognomic findings. Ultrastructural studies have shown abnormal vacuolar changes in fibroblasts. Protein analysis of hyaline material has shown overproduction of normally expressed noncollagenous protein. LP is caused by homozygous or compound heterozygous mutations in the Extracellular Matrix Protein

1 (ECM1) gene located on chromosome 1q21. The ECM1 gene encodes an important structural component of the basement membrane and extracellular matrix.<sup>[2]</sup> ECM1 is a glycoprotein that may contribute to skin adhesion, scarring, wound healing and angiogenesis. ECM1 deficiency leads to impaired protein-protein interaction, resulting in altered degradation of glycolipids and sphingolipids, as well as accumulation of basement membrane collagen types and hyaline material.<sup>[4]</sup> It is estimated that <500 cases of LP have been described in the literature with most of these reports focusing on ocular and dermatologic manifestations<sup>[3,5,6]</sup> and approximately 137 cases of LP with oral manifestation are reported to 2016.<sup>[7]</sup> In India, approximately 51 cases reported to the date and review of all Indian cases are shown in Table 1a-c.

Extraoral manifestations include waxy papules on the skin and beaded-like pearls along the eyelids.<sup>[7,8]</sup> Moreover, the

### Access this article online

#### Quick Response Code:



#### Website:

www.jomfp.in

#### DOI:

10.4103/jomfp.jomfp\_249\_21

This is an open access journal, and articles are distributed under the terms of the Creative Commons Attribution-NonCommercial-ShareAlike 4.0 License, which allows others to remix, tweak, and build upon the work non-commercially, as long as appropriate credit is given and the new creations are licensed under the identical terms.

**For reprints contact:** WKHLRPMedknow\_reprints@wolterskluwer.com

**How to cite this article:** Shah JS, Shah HA. Lipoid proteinosis: Review of Indian cases. J Oral Maxillofac Pathol 2022;26:236-41.

respiratory system, upper gastrointestinal tract, central nervous system, blood vessels and lymph nodes may also be involved. LP is known to have calcification of the temporal lobes or hippocampi in the brain. Epilepsy, memory loss, schizophrenic behavior, mental retardation, emotional changes and other neuropsychiatric abnormalities may be seen in some patients. Hyaline deposits have also been described in the conjunctiva, cornea, trabeculum and retina. Corneal opacities or secondary glaucoma may appear later.<sup>[8]</sup> Oral manifestations of LP occasionally commence at infancy. Typically, babies with LP are unable to cry because of vocal cord infiltration with hyaline deposits. This gradually results in a unique voice that sounds like a hoarse whisper. The tongue is firm, sometimes described as having a wooden hard consistency, and it is usually immobile. Other oral mucosae might also be infiltrated by characteristic hyaline deposits that confer a clinical appearance of thick yellow-gray plaques.<sup>[7,9]</sup> Frenkel *et al.* 7 recently reviewed the largest case series of oral manifestations observed in patients with LP. In their

study, the primary sites of oral involvement included: Tongue (68%), floor of the mouth (55.8%), lips (43%), buccal mucosa (40%), palate (25%) and gingiva (5.8%).<sup>[7]</sup>

In classic cases, the most characteristic radiological findings on plain radiographs and computed tomography (CT) scans are bilateral, fairly dense, paracellular, symmetrical, intracranial bean-shaped calcifications within the hippocampal region of temporal lobes.<sup>[8-10]</sup>

There is no such blood or serum profile abnormality present, which can be used as diagnostic purpose.<sup>[6]</sup> Only combined typical clinical, radiographical and histopathological investigations can confirm the diagnosis.

The histopathological features include epidermal hyperkeratosis, irregular acanthosis, thickened dermis and the presence of large deposits of periodic acid-Schiff (PAS)-positive and diastase-resistant extracellular hyaline material. Ultrastructural findings include multiple concentric rings of basement membrane around blood vessels and irregular reduplication of the lamina densa at the dermal-epidermal junction.<sup>[10,11]</sup>

There is presently no effective therapy for LP. Various treatment modalities including dimethyl sulfoxide, etretinate, acitretin, penicillamine, surgical procedures, carbon dioxide laser and dermabrasion have been used with variable results. Generally, LP is benign and patients have normal life expectancy.<sup>[10,12]</sup>

An attempt has been done to review 51 Indian LP cases as well as classical skin, laryngeal, ocular, oral, radiographic and histological features are discussed for the present reported case.

**MATERIALS AND METHODS**

A thorough search was carried out from the year 1969 to 2021 using keywords such as LP and Urbach-Wiethe syndrome on Google, Google scholar, and PubMed. Indian

**Table 1a: Age and sex wise distribution of Indian cases of lipoid proteinosis**

Age group (years)	Male (n=36; 70.6%), n (%)	Female (n=15; 29.4%), n (%)	Total (n=51; 100%), n (%)
1-10	7 (19.4)	3 (20)	10 (19.6)
11-20	17 (47.2)	9 (60)	26 (51)
21-30	4 (11.1)	2 (13.3)	6 (11.8)
31-40	4 (11.1)	1 (6.6)	5 (9.8)
41-50	-	-	-
>50	4 (11.1)	-	4 (7.8)

**Table 1b: Distribution of patients according to features of lipoid proteinosis in Indian cases**

Features	Number of cases (n=51), n (%)	Present case
Consanguinity	21 (41.2)	Yes
Siblings	11 (21.6)	No
Dermatological manifestation	51 (100)	Yes
Laryngeal involvement	49 (96.1)	Yes
Oral manifestation	42 (82.3)	Yes
Systemic manifestation	10(19.61%)	No
Radiographic features	12 (41.2)	Yes
Histologically proven	50 (41.2)	Yes

**Table 1c: Distribution of oral manifestations reported in Indian cases of lipoid proteinosis**

Oral manifestations	Number of cases (n=42), n (%)	Present case
Macroglossia	12 (28.6)	No
Restricted mouth opening	6 (14.3)	No
Restricted tongue movements	19 (45.2)	Yes
Thick woody tongue	20 (47.6)	Yes
Lingual frenum	11 (26.2)	Yes
Lower lip	13 (31)	Yes
Thick and nodular/popular buccal mucosa	10 (23.8)	No
Thick and nodular palatal mucosa	6 (14.3)	No
Infiltrations present over tonsils and soft palate	4 (9.5)	No
Xerostomia	2 (4.8)	No
Dysphagia	2 (4.8)	Yes

cases were retrieved and analyzed for all demographic data, extraoral and intraoral manifestations, radiographic features, and histopathological details.

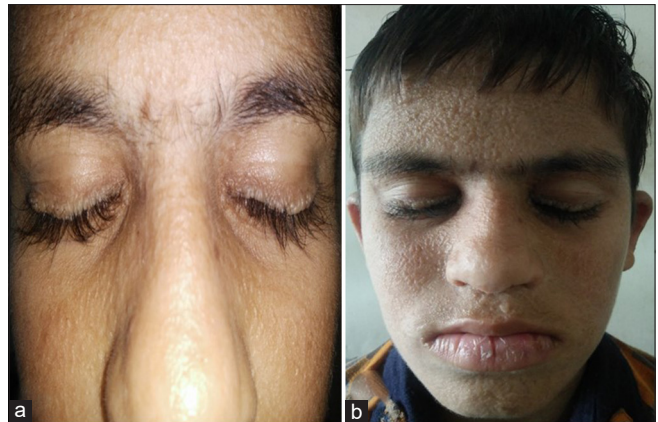### CASE REPORT

A 12-year-old male patient reported to the Oral Medicine and Radiology Department with pain during mastication and difficulty in swallowing due to oral ulcerations for 8 days. The patient was a known case of LP, diagnosed before 7 years.

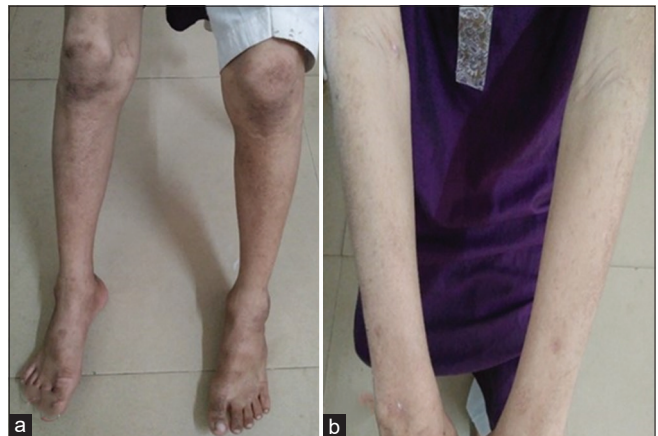
Mother noticed the child's hoarseness of voice since birth. Then after 5 years, she noticed multiple fluid-filled, nonitchy peeled skin lesions on bilateral arms then spread to involve the entire body within 12 months. Along with that photosensitivity and winter aggravation of skin, lesions were also present. After 2 years difficulty in speech developed. For that parent consulted private practitioner and LP was diagnosed. Except consanguineous marriage of parents, no significant family history was present. No history of respiratory obstruction or any gastric complaint or no other systemic involvement was there. The patient was relatively asymptomatic before 8 days. Then he developed high grade, intermittent fever. After taking medications fever subsided. He had also complaint of oral ulcerations and difficulty in mastication for 8 days which was not relieved by medications and hence, the patient came to dental outpatient department.

On extraoral examination, string of beads appearance over eyelids (moniliform blepharosis) [Figure 1a]. Pock-like scarring was present on the forehead [Figure 1b]. Varioliform scarring was present over legs [Figure 2a] and forearms [Figure 2b]. On the back and buttocks, few erosions with varioliform scarring were present [Figure 3].

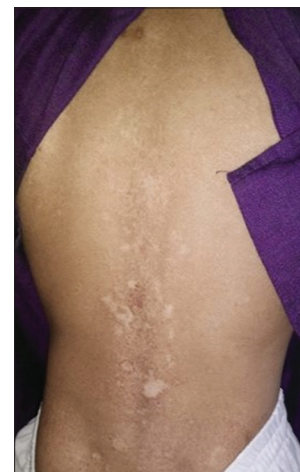On intraoral examination, diffuse ulceration present over the dorsum of the tongue with yellowish slough present over the surface [Figure 4a]. Margin was thick, raised and everted. The lesion was firm and thick with slight indurated base, with marked increased tenderness on palpation. No bleeding tendency was there. Thickened tongue and sublingual frenum [Figure 4b]. Tongue movements were reduced in all directions. Few minute white plaque-like lesions present on the dorsum of the tongue which were slightly raised from the surface. Uvula was slightly thickened. Lower labial mucosa was also thickened having firm consistency with yellowish papular infiltration, giving pebbled appearance [Figure 5a]. Crusting lower lip and increased fissures on both the lips were also noticed [Figure 5b]. No any abnormality was present on Gingiva and Buccal Mucosa.



**Figure 1:** (a) Showing string of beads appearance over eyelids (moniliform blepharosis). (b) Showing pox-like scarring on forehead



**Figure 2:** (a) Showing pox like scarring on legs. (b) Showing pox like scarring on forearms



**Figure 3:** Showing similar skin lesions on back and buttocks

On hard tissue examination, no any abnormality was noted in teeth or any hard tissue.

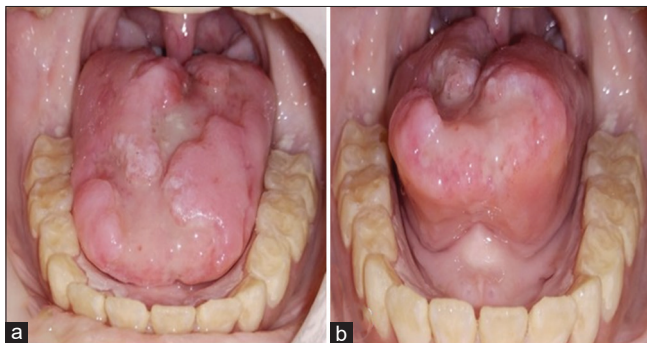
Orthopantomogram showed absence of all 2<sup>nd</sup> premolars. Erupting all canine and 1<sup>st</sup> premolars and 2<sup>nd</sup> molars and

erupted left maxillary 1<sup>st</sup> premolar. All teeth had normal tooth structure with no any other abnormality [Figure 6a]. A rare radiographic finding of bean-shaped calcification just above the sella turcica region is also evident in lateral cephalogram [Figure 6b].

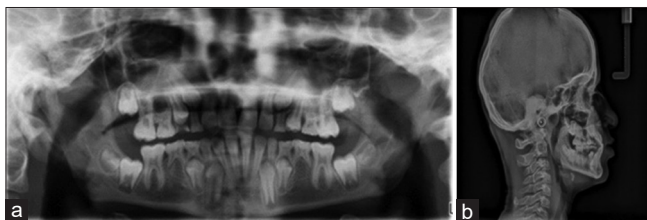The patient's blood, liver function profile and urine profile were within the normal limits. Lipid profile was also within the normal range that was serum cholesterol 140 mg/dl (Reference level <200 mg/dl), serum triglyceride 94 mg/dl (Reference Level < 200 mg/dl), serum high-density lipoprotein 36.6 mg/dl (Reference level <60 mg/dl), serum low-density lipoprotein (LDL) 94.6 (Reference Level <130 mg/dl), serum Very LDL 18.8 mg/dl (Reference Level up to 34 mg/dl).

Incisional biopsy was taken from lower labial mucosa, which showed hyperplastic parakeratinized stratified squamous epithelium with features of mild dysplasia and dense and mature collagen fiber bundles in connective tissue were seen. PAS stained section showed thickening of the walls of some of the blood vessels.

The patient was under medication of capsule acitretin 10 mg, multivitamin tablets, and folic acid tablets for skin lesions. For oral lesions, topical application of choline salicylate and lignocaine combination (dologel CT), xylocaine mouthwash, and calcium gluconate tablet were given.



**Figure 4:** (a) Showing thickened tongue with diffuse ulceration and slightly thickened uvula. (b) Showing thickened sublingual frenum with reduced tongue movement



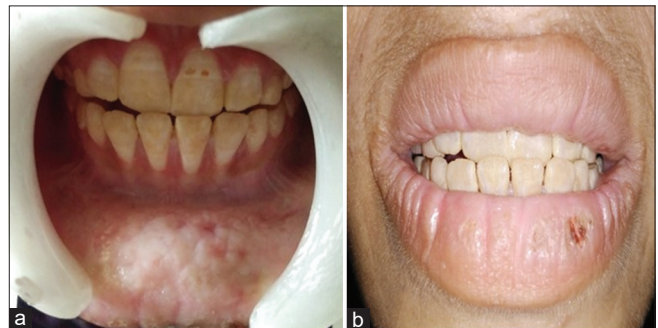**Figure 6:** (a) Orthopantomogram showing absence of all 2<sup>nd</sup> premolars. Erupting all canine and 1<sup>st</sup> premolars and 2<sup>nd</sup> molars, and erupted left maxillary 1<sup>st</sup> premolar with normal teeth structure. (b) Lateral cephalogram showing bean-shaped calcification in suprasellar region

Follow-up after 1 month, showed that lesions were totally subsided on the tongue as well as tongue movements were also increased up to certain limit. Extremities' lesions were improved as well. Facial and ocular features were unchanged [Figure 7]. The patient was kept on follow-up and recalled after 1 month.

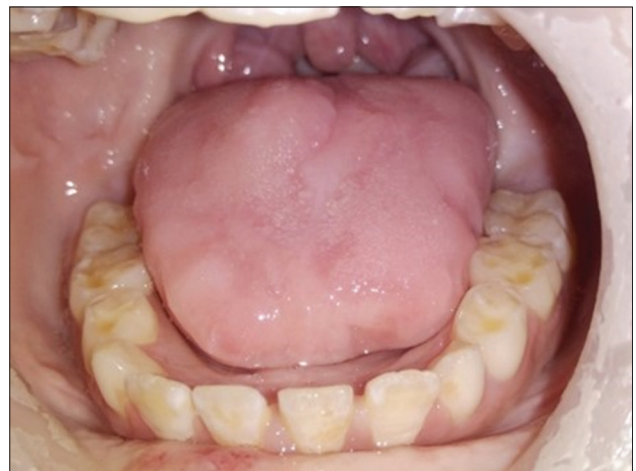## REVIEW AND DISCUSSION

LP is a very rare, autosomal recessive disorder, characterized by infiltration of hyaline material into the skin, oral cavity, larynx and internal organs.

As per literature, LP is more prevalent in Sweden, South Africa, and Asia. Consanguineous marriage plays a major role in correlation with LP.<sup>[6,7,13]</sup> As Indian cases are much less reported and reviewed. Hence, review of 51 cases of LP reported in India from 1969 to 2021 is done along with the present case [Table 1a-c].<sup>[1,4,5,6,8-44]</sup> LP is more reported in patients in the age group of 11-20 (51%). More prevalence of LP is reported in males (70.6%). Consanguineous marriage history is positive in 21 (41.2%) of the cases. Siblings are not much affected except in 11 (21.6%) cases.



**Figure 5:** (a) Showing Thickened lower labial mucosa with minute depressions and elevation giving pebbled appearance. (b) Showing crusting and fissuring seen on both lips



**Figure 7:** Showing total regression of tongue lesion after 1 month

Dermatological manifestations are constantly seen in every case. The skin lesions occur in two stages. The first stage consists of pustules, bullae and hemorrhagic crusts of the skin, mouth and throat, which usually appear during the first 2 years of life. The skin lesions resolve with pock-like or acneiform scarring, usually on the face and distal extremities. In the second stage, deposits increase in the dermis, and the skin becomes thickened, yellowed and waxy. The scarring of these erosions usually begins during childhood and is often worst in the face. It may follow trauma or occur spontaneously. The classic and most easily recognizable sign is the beaded eyelid papules (moniliform blepharosis).<sup>[1,11,12]</sup> All dermatological findings are due to deposition of hyaline material into the dermal-epidermal junction. In all reviewed Indian cases had similar findings. In the present case also skin lesions started since the age of 5 years.

Laryngeal involvement is most commonly and earliest to be involved, seen clinically as hoarseness of voice.<sup>[7]</sup> In the present case also similar findings were reported. It is due to vocal cord infiltration by hyaline deposits.<sup>[3,13]</sup> All cases had similar findings except two cases.<sup>[6,18]</sup>

On review of oral manifestations, 42 cases were found as shown in Table 1c.<sup>[1,4,5,8-23,25-35,37-39,42-44]</sup> The most common involved site is tongue with typical thick woody appearance followed by restricted tongue movements. In the present case, also similar findings were present. Thickened lingual frenum is also reported in the present case. Oral ulceration on the dorsal surface of the tongue is not much reported in the literature. However, few cases have been reported for oral ulcerations. In the present case, ulcer occurred for the first time and healed after giving topical anti-inflammatory and anesthetic. This is suggestive of traumatic ulcer. The reason behind it may be due to depapillation of the tongue, restricted tongue movement and recurrent inflammation of glands of the oral mucosa. ECM1 is normally expressed in several tissue types and is responsible for the deposition of hyaline material in the dermis, as well as the thickening of the skin, mucosa and basement membrane around blood vessels and adnexal epithelia. Mutations in ECM1 cause extensive deposition of noncollagenous proteins and glycoproteins in the skin and mucosa. In addition, normal Collagen IV binding is impaired, resulting in increased expression of Collagen V giving all dermatological, oral, and histopathological changes.<sup>[3,21,31]</sup>

Systemic involvement is rare to seen to be involved. Only 10 cases have reported systemic involvement in which, the most common feature is seizure and mental retardation.<sup>[5,9,14-20]</sup>

Along with typical bean-shaped calcifications in the temporal lobe and in the amygdala in radiographs, in some cases, microdontia of the permanent premolars and the congenital absence of the permanent upper lateral incisors and 2<sup>nd</sup> premolar have been described in the literature.<sup>[3,8]</sup> Twelve cases have been found with such radiographic changes.<sup>[5,6,8,17,18,20,33]</sup> In the present case also along with typical radiographic changes, the absence of all 2<sup>nd</sup> premolars was found giving typical case of LP.

Fifty cases have been proven histologically. The present case also histologically proven. It is mandatory to confirm histopathologically to differentiate from amyloidosis or erythropoietic protoporphyria.<sup>[3,11]</sup>

## CONCLUSION

On review of Indian cases, it can be said that the most commonly affected age group is 11–20 years with male prevalence. Dermatological manifestation was found to be the most common followed by laryngeal and oral involvement. As consanguineous marriage and sibling's history are also seen, parents should be educated for the same to prevent the occurrence of LP. Civilians also should be educated regarding the risks of consanguineous marriage. Here, a very rare case of LP is reported having typical oral, laryngeal, dermatological, and radiographical manifestations as very early involvement before any other systemic involvement other than skin, which is not reported much. Thus, oral physician are often in the earliest position to diagnose LP and by proper management, its morbidity can be decreased and so the prognosis of the disease.

## Declaration of patient consent

The authors certify that they have obtained all appropriate patient consent forms. In the form the patient (s) has/have given his/her/their consent for his/her/their images and other clinical information to be reported in the journal. The patients understand that their names and initials will not be published and due efforts will be made to conceal their identity, but anonymity cannot be guaranteed.

## Financial support and sponsorship

Nil.

## Conflicts of interest

There are no conflicts of interest.

## REFERENCES

1. Nayak S, Acharjya B. Lipoid proteinosis in a six-year-old child. *Indian Dermatol Online J* 2012;3:25-7.
2. Hamada T, McLean WH, Ramsay M, Ashton GH, Nanda A, Jenkins T, *et al.* Lipoid proteinosis maps to 1q21 and is caused by mutations in

- the extracellular matrix protein 1 gene (ECM1). *Hum Mol Genet* 2002;11:833-40.
3. Lee KC, Peters SM, Ko YC, Kunkle TC, Perrino MA, Yoon AJ, *et al*. Oral manifestations of lipoid proteinosis in a 10-year-old female: A case report and literature update. *Oral Surg Oral Med Oral Pathol Oral Radiol* 2018;126:e228-32.
  4. Ravi Prakash SM, Verma S, Sumalatha MN, Chattopadhyay S. Oral manifestations of lipoid proteinosis: A case report and literature review. *Saudi Dent J* 2013;25:91-4.
  5. Kachewar S, Singh H, Sasane AG, Bhadane S. Full blown case of lipoid proteinosis. *Med J Armed Forces India* 2011;67:90-1.
  6. Kachewar SG, Kulkarni DS. A novel association of the additional intracranial calcification in lipoid proteinosis: A case report. *J Clin Diagn Res* 2012;6:1579-81.
  7. Frenkel B, Vered M, Taicher S, Yarom N. Lipoid proteinosis unveiled by oral mucosal lesions: A comprehensive analysis of 137 cases. *Clin Oral Investig* 2017;21:2245-51.
  8. Kabre V, Rani S, Pai KM, Kamra S. Lipoid proteinosis: A review with two case reports. *Contemp Clin Dent* 2015;6:233-6.
  9. Bharathi R, Gnanadeepam S, Parthiban N, Kamalakaran A. Lipoid proteinosis: A case report. *J Dr NTR Univ Health Sci* 2017;6:133.
  10. Ranjan R. Lipoid proteinosis: A case report in two siblings. *Dermatol Online J* 2015;21:7.
  11. Mittal HC, Yadav S, Malik S, Singh G. Lipoid proteinosis. *Int J Clin Pediatr Dent* 2016;9:149-51.
  12. Madura C, Priya A, Chandrashekar BS. Lipoid proteinosis: Skin resurfacing with combination of fractional CO<sub>2</sub> and non-ablative radio frequency: A rare case report. *J Cutan Aesthet Surg* 2018;11:91-4.
  13. Rath MM, Mohanty P. Lipoid proteinosis: A rare congenital genodermatosis. *J Dr NTR Univ Health Sci* 2017;6:166.
  14. Mainali S, Nayak R, Gaur S. Oral findings in a child with lipoid proteinosis: A case report and review. *J Indian Soc Pedod Prev Dent* 2011;29:62-7.
  15. Kini S, Jain A, Shet TM, Bansode S, Vora IM, Ghorpade K. Lipoid proteinosis in a 12-year-old child: A report from west India. *Dermatol Online J* 2006;12:10.
  16. Chakrabarti K, Sengupta SK, Ghosh AK, Das SK. Lipoid proteinosis (Urbach-Wiethe syndrome) with dwarfism. *Indian Pediatr* 1991;28:75-8.
  17. Rao AG, Koppada D. Lipoid proteinosis. *Indian J Dermatol Venereol Leprol* 2015;81:549.
  18. Sainani MP, Muralidhar R, Parthiban K, Vijayalakshmi P. Lipoid proteinosis of Urbach and Weithe: Case report and a brief review of the literature. *Int Ophthalmol* 2011;31:141-3.
  19. Mandal S, Dutta P, Venkatesh P, Sinha R, Kukreja M, Garg S. Bilateral lens subluxation in a case of lipoid proteinosis. *J Cataract Refract Surg* 2007;33:1469-70.
  20. Srinivas SM, Maganthi M, Chandrasekaran PJ, Gowdra A, Palany R. Clinical and molecular characterization of lipoid proteinosis in three Indian families. *Indian J Paediatr Dermatol* 2020;21:167.
  21. Sadaksharam J, Karthikeyan B, Mahalingam S, Kessavalou S. Lipoid proteinosis with oral manifestation in a geriatric patient: A unique case report. *J Indian Acad Oral Med Radiol* 2015;27:428.
  22. Rao RS, Betkerur SS, Babu C, Sudha V. Lipoid proteinosis. *J Oral Maxillofac Pathol* 2009;13:81-4.
  23. Batra K, Safaya A, Aggarwal K. Lipoid proteinosis (Urbach-Wiethe disease): A case report from India. *Ear Nose Throat J* 2008;87:531-2.
  24. Sen S, Roy G, Bandopadhyay D. Lipoid proteinosis. *Indian J Dermatol* 2006;51:49.
  25. Vedamurthy M. Lipoid proteinosis in siblings. *Dermatol Online J* 2003;9:13.
  26. Sethuraman G, Tejasvi T, Khaitan BK, Handa KK, Rao S, Singh MK, *et al*. Lipoid proteinosis in two siblings: A report from India. *J Dermatol* 2003;30:562-5.
  27. Rahalkar MD, Kelkar AB, Gharpuray MB, Patwardhan NG. Images: Lipoid proteinosis. *Indian J Radiol Imaging* 2001;11:85.
  28. Chaudhary SJ, Dayal PK. Hyalinosis cutis et mucosae. Review with a case report. *Oral Surg Oral Med Oral Pathol Oral Radiol Endod* 1995;80:168-71.
  29. Kaur V, Singh G. Lipoid proteinosis. *Indian J Dermatol Venereol Leprol* 1992;58:399.
  30. Banerjee S, Jana S, Azad AK, Sinha R, Datta J, Banerjee R, *et al*. Lipoid proteinosis with vesicular eruptions and hypertrichosis: Rare associations. *Indian J Dermatol* 2005;50:98.
  31. Deshpande P, Guledgud MV, Patil K, Hegde U, Sahní A, Huchanahalli Sheshanna S. Lipoid proteinosis: A rare encounter in dental office. *Case Rep Dent* 2015;2015:670369.
  32. Naha K, Shastry AB, Saravu K, Bhatia S. Lipoid proteinosis mimicking congenital immunodeficiency: A case report. *Australas Med J* 2011;4:155-9.
  33. Singh G, Misra D. Lipoid proteinosis. *Int J Dermatol* 1988;27:344-5.
  34. Bhattacharjee R, Chatterjee D, Vinay K. Lipoid proteinosis. *JAMA Dermatol* 2018;154:1479-80.
  35. Shetty NJ, Rao NR. Lipoid proteinosis. *Indian J Dermatol Venereol* 1969;35:230-2.
  36. Ranjan P, Mishra D, Plesec T, Pratap VB, Singh AD. Familial moniliform blepharosis: Clinical, histopathological and genetic correlation. *Ophthalmic Genet* 2015;36:160-4.
  37. Parmar NV, Krishna CV, De D, Kanwar AJ, Saikia UN. Papules, pock-like scars, and hoarseness of voice. Lipoid proteinosis. *Indian J Dermatol Venereol Leprol* 2013;79:136.
  38. Kuchabal SD, Kuchabal DS. Lipoid proteinosis in two families. *Int J Dermatol* 2011;50:972-5.
  39. Srivalli M, Qaiyum HA, Moorthy PN. Lipoid proteinosis of the larynx in siblings: Exploring new modalities of treatment. *Indian J Otolaryngol Head Neck Surg* 2009;61 Suppl 1:59-61.
  40. Sharma A, Gupta LK, Balai M, Khare AK. Lipoid proteinosis: A series of three cases. *Indian J Paediatr Dermatol* 2018;19:170.
  41. Tripathi A, Kumar Gupta S. Lipoid proteinosis masquerading as seborrheic dermatitis. *Cureus* 2021;13:e15617.
  42. Agarwal P, Jagati A, Vadher P, Chaudhari M. Lipoid proteinosis: Curious case of two siblings! *Indian Dermatol Online J* 2020;11:639-40.
  43. Vishwanath T, Dhurat R, Borawake S, Joshi A, Agrawal S, Ghate S. Utility of acitretin in improving quality of life in lipoid proteinosis. *Ann Indian Acad Otorhinolaryngol Head Neck Surg* 2019;3:49.
  44. Sharma SR, Karjodkar FR, Sansare KP, Saalim M. Oral manifestations of lipoid proteinosis – A rare clinical entity. *J Oral Maxillofac Surg Med Pathol* 2018;30:562-5.