

Not all elevated hormones are toxic: A case of thyroid hormone resistance

Rajeev Philip¹, Mohan Krishnakumar Padikal², Altaf Alinausad³,
Charamelsankaran Keshavan³

Departments of ¹Endocrinology, ²Family Medicine and ³Medicine, PIMS, Thiruvalla, Kerala, India

ABSTRACT

Resistance to thyroid hormone syndrome (RTH) is a rare disorder and is usually inherited as dominantly negative autosomal trait. RTH is caused by mutations in the thyroid hormone receptor beta. Patients with RTH usually do not have signs and symptoms of thyrotoxicosis, but the thyroid function test shows an elevated T3 and T4, which get misinterpreted as hyperthyroidism, resulting in unnecessary treatment.

Keywords: Neurophysiologic abnormalities, resistance to thyroid hormone syndrome, thyroid hormone receptor beta

Introduction

Thyroid hormone resistance (RTH) is a rare genetic disorder characterized by reduced target tissue responsiveness to thyroid hormones. Since Refetoff *et al.* described this syndrome in 1967; over 1000 cases have been identified. Thyroid hormone resistance can have highly variable clinical manifestations, making it difficult to diagnose, and it may go unrecognized for a long time, or can get misdiagnosed and treated as hyperthyroidism.

We are presenting the case of a 26-year-old female with goiter and RTH and was managed previously as a case of hyperthyroidism.

Case Report

A 26-year-old female was referred to the medicine OPD for follow-up of her thyroid status. She was previously diagnosed to have hyperthyroidism from an outside hospital and was on carbimazole for the last 5 years.

On review of her complaints, she recollected that she was always the shortest in her class in the school years. There was also a history of subnormal intelligence, poor scholastic performance, hearing loss, and attention deficit hyperactivity disorder (ADHD). There was a history of short stature in the family in the maternal side, and they were being treated for hyperthyroidism. She developed goiter 10 years back, but she did not have any clinical symptoms of hyperthyroidism (palpitations, tremors, and moist skin) nor had any ocular signs or symptoms. During the evaluation for goiter, her thyroid hormone levels showed increased T4, T3, free T4 and free T3, with a normal thyroid stimulating hormone (TSH), for which she was started on antithyroid drugs.

On clinical examination, she was conscious and alert, short statured (height 142 cm, weight 47 kg). She had tachycardia with a pulse rate of 102/min. She was normotensive and afebrile at presentation. Examination of the thyroid gland showed diffuse enlargement of the thyroid, World Health Organization Grade 2 without palpable nodules [Figure 1]. There was no bruit on auscultation, and the eye examination was normal. The systemic examination was within normal limits.

Address for correspondence: Dr. Rajeev Philip,
Department of Endocrinology, PIMS, Thiruvalla, Kerala, India.
E-mail: dr Rajeevphilip@yahoo.com

Access this article online

Quick Response Code:



Website:
www.jfmpc.com

DOI:
10.4103/2249-4863.192339

This is an open access article distributed under the terms of the Creative Commons Attribution-NonCommercial-ShareAlike 3.0 License, which allows others to remix, tweak, and build upon the work non-commercially, as long as the author is credited and the new creations are licensed under the identical terms.

For reprints contact: reprints@medknow.com

How to cite this article: Philip R, Padikal MK, Alinausad A, Keshavan C. Not all elevated hormones are toxic: A case of thyroid hormone resistance. *J Family Med Prim Care* 2016;5:460-2.

Laboratory investigations showed elevated T3 and T4 with T3 - 3.15 (0.95–2.5 nmol/L), free T3 - 5.12 (2.3–4.2 pg/mL), T4: 233 (60–120 nmol/L), and free T4 - 3.1 (0.8–1.8 ng/L). The TSH was inappropriately normal - 4.39 (0.2–5 μ IU/L).

Ultrasonography thyroid was done which showed multiple hyperechoic well-defined subcentimetric nodules with peripheral halo and no internal vascularity in both lobes of the thyroid-features suggestive of multinodular goiter.

The possibilities of thyroid hormone resistance and TSH-secreting adenoma were considered, and a magnetic resonance imaging (MRI) pituitary was done to look for a pituitary mass, which turned out to be normal. A sex hormone binding globulin levels were done to look for peripheral action of thyroid hormone, which was normal - 48.3 ng/L (normal - 11.7–137.2 ng/L), indicating the resistance of thyroid hormone action at the level of liver.

A pure tone audiometry done showed a moderate hearing loss with mixed component at mid frequency [Figure 2].

Thyroxin suppression testing was done which showed poor suppression of TSH (3.29 μ IU/L), confirming the diagnosis of thyroid hormone resistance.

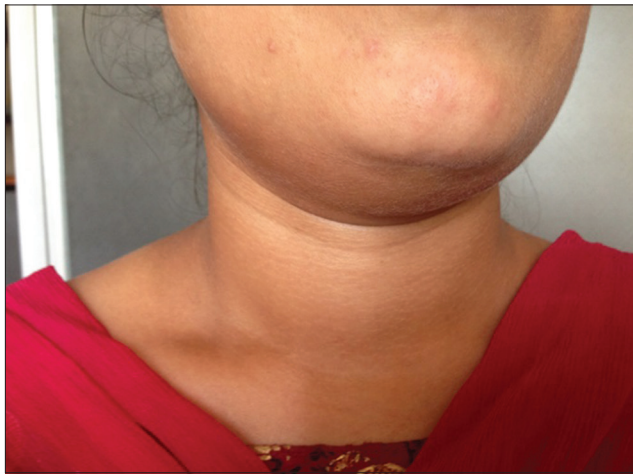

Figure 1: Firm Organisation Organization Grade 2 goitre

Discussion

RTH is found in about 1/40,000–50,000 live births. Familial occurrence of RTH has been documented in approximately 75% of cases and inheritance is usually autosomal dominant,^[1] but *de novo* mutation can occur in approximately 17% of cases. Both males and females are equally affected.

RTH is classified into two phenotypes: Generalized resistance to thyroid hormone (GRTH) and partial resistance to thyroid hormone (PRTH). Patients with GRTH are typically euthyroid or hypothyroid, whereas patients with PRTH are usually hypermetabolic. No differences in the absolute levels of TSH or free thyroid hormone are observed in GRTH patients as opposed to PRTH patients. A molecular mechanism to explain these two clinical phenotypes has proven elusive, and many authors have concluded that they are part of a spectrum of the same disorder.^[2]

Sinus tachycardia is very common in patients with RTH, some studies reporting frequency as high as 80%. The liver and pituitary express predominantly thyroid hormone receptor beta 1 (TR β) and TR β 2 respectively, whereas myocardium expresses TR α 1. Therefore, mutations in the TR β gene in RTH are associated with pituitary and liver resistance, as exemplified by normal serum sex-hormone-binding globulin and nonsuppressed TSH levels seen in patients while the tachycardia seen in many RTH cases may represent retention of cardiac sensitivity to elevated thyroid hormones acting via a normal TR α .^[3,4] Most cases of RTH are caused by mutations in the THRB gene.

Neurophysiological abnormalities such as ADHD in childhood or language development problems manifested by poor reading skills, dyslexia, and problems with articulation have been documented in a large number of patients with RTH.^[5]

The diagnosis of thyroid hormone resistance is suspected when a patient with no features of hyperthyroidism is detected to have elevated free T3 and free T4 with normal or slightly elevated TSH. A normal MRI Pituitary, a normal SHBG levels, and nonsuppressible TSH after thyroxine or liothyronine will help to confirm the diagnosis. This diagnosis helps in avoiding

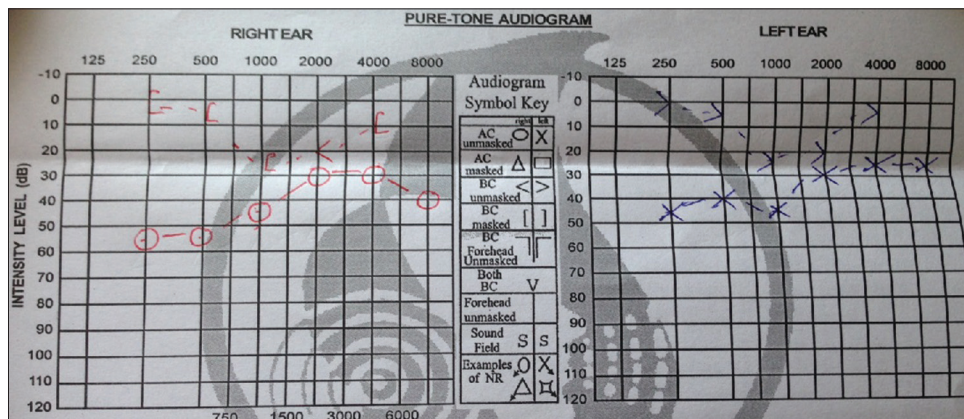


Figure 2: Tone audiometry showing moderate mixed hearing loss

unnecessary treatment as most of the patients get treated as hyperthyroidism, as it happened in our case.

Financial support and sponsorship

Nil.

Conflicts of interest

There are no conflicts of interest.

References

1. Olateju TO, Vanderpump MP. Thyroid hormone resistance. *Ann Clin Biochem* 2006;43(Pt 6):431-40.
2. Weiss RE, Weinberg M, Refetoff S. Identical mutations in unrelated families with generalized resistance to thyroid hormone occur in cytosine-guanine-rich areas of the thyroid hormone receptor beta gene. Analysis of 15 families. *J Clin Invest* 1993;91:2408-15.
3. Usala SJ, Bale AE, Gesundheit N, Weinberger C, Lash RW, Wondisford FE, *et al.* Tight linkage between the syndrome of generalized thyroid hormone resistance and the human c-erbA beta gene. *Mol Endocrinol* 1988;2:1217-20.
4. Mitchell CS, Savage DB, Dufour S, Schoenmakers N, Murgatroyd P, Befroy D, *et al.* Resistance to thyroid hormone is associated with raised energy expenditure, muscle mitochondrial uncoupling, and hyperphagia. *J Clin Invest* 2010;120:1345-54.
5. Kaplan MM, Swartz SL, Larsen PR. Partial peripheral resistance to thyroid hormone. *Am J Med* 1981;70:1115-21.