

## Epstein-Barr virus-associated Hodgkin's disease following renal transplantation

Jung-Hye Choi, M.D., Myung-Ju Ahn, M.D., Young-Ha Oh, M.D.<sup>2</sup>,  
Sang-Woong Han, M.D., Ho-Jung Kim, M.D.,  
Young-Yeul Lee, M.D. and In-Soon Kim, M.D.

*Departments of Internal Medicine and Pathology<sup>2</sup>, Hanyang University College of Medicine, Seoul, Korea*

---

Post-transplant lymphoproliferative disorders (PTLD) have been recognized as a complication of immunosuppression and occur with a reported incidence of 1 to 8% of recipients receiving solid organ transplantation. PTLD are classified into two major categories, polymorphic and monomorphic PTLD. The majority of the monomorphic PTLD cases are non-Hodgkin's lymphoma of B-cell origin. Hodgkin's disease is not part of the typical spectrum of PTLD; however, it has been rarely reported. We describe a case of Hodgkin's disease following renal transplantation. A 41-year-old man developed right cervical lymphadenopathy following renal transplantation 116 months previously for chronic renal failure of unknown origin. He had been taking cyclosporine, mycophenolate mofetil and prednisone. A lymph node biopsy revealed mixed cellularity Hodgkin's disease. Immunohistochemical staining was positive for CD30 and EBV-latent membrane protein-1. No other site of disease was identified. The immunosuppressive agents were reduced (mycophenolate mofetil was discontinued, cyclosporine dose reduced from 200 mg to 150 mg and prednisone continued at 5 mg). After 2 cycles of ABVD followed by radiation therapy (3600 cGy), he achieved complete remission.

**Key Words :** Post-transplant lymphoproliferative disorder, Hodgkin's disease, Renal transplantation

---

### INTRODUCTION

Renal transplant recipients are prone to develop secondary malignancies, especially lymphoid malignancies, carcinomas of the skin and lip, carcinomas of the vulva and perineum, *in situ* carcinomas of the cervix of the uterus, Kaposi's sarcoma, hepatocellular carcinomas, renal carcinomas, and various soft tissue sarcomas<sup>1</sup>. A large proportion of these malignancies consist of post-transplant lymphoproliferative disorders (PTLD), which have been recognized as a complication of immunosuppression and are often associated with Epstein-Barr virus (EBV) infection of B cells, leading to their uncontrolled proliferation<sup>2-4</sup>. The majority of PTLD cases are non-Hodgkin's lymphoma. In contrast, Hodgkin's disease that is not part of the typical spectrum of PTLD, is rare following solid organ transplantation<sup>5-9</sup>. We describe a case of Hodgkin's disease

following renal transplantation.

### CASE REPORT

A 41-year-old man received a kidney transplant 116 months previously for chronic renal failure of unknown origin. The post-transplant immunosuppressive agents consisted of cyclosporine, mycophenolate mofetil, and prednisone. He remained well with stable renal function for almost 10 years, maintaining a serum creatinine level in the range of 2 mg/dL.

In April 2004, he was admitted to the hospital because of right cervical lymphadenopathy and a 6 kg weight loss over the previous 2 months. There was no history of fever or night sweats. Laboratory findings showed a hemoglobin level of 9.1 g/dL, white blood cell count  $8.4 \times 10^9/L$ , platelet count  $445 \times$

---

• Received : March 16, 2005

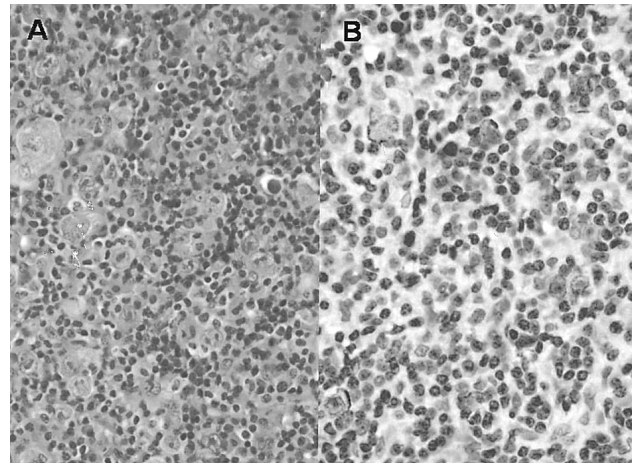
• Accepted : June 30, 2005

• Correspondence to : Jung-Hye Choi, M.D. Department of Internal Medicine, Hanyang University Guri Hospital 249-1 Gyomoon-Dong, Guri city, Gyeonggi-do 471-701, Korea Tel : 82-31-560-2236, Fex : 82-31-553-7369, E-mail : jhcnd@hanyang.ac.kr

$10^9/L$ , creatinine 2.5 mg/dL, lactic dehydrogenase 229 U/L, and an erythrocyte sedimentation rate of 50 mm/hr. Liver function tests were normal. Estimated glomerular filtration rate was 37.0 mL/min/1.73 m<sup>2</sup>. Serologic tests for EBV were negative for EBV (VCA) IgM, positive for EBV IgG and positive for EBNA. Magnetic resonance imaging (MRI) of the neck showed multiple lymph nodes ranging from 1~3 cm in the right cervical level II to V, and a single lymph node on the left at level II. There were no abnormal findings on plane film chest X-ray, abdominal computerized tomography or bone marrow biopsy. The patient was clinically stage IIB. The right cervical lymph node at level III was excised and microscopically revealed mixed cellularity Hodgkin's disease with typical Reed-Sternberg cells. Immunohistochemical staining was positive for CD30 and EBV-latent membrane protein-1 (LMP-1) in the Reed-Sternberg cells (Figure 1), but CD15 staining was negative. CD20, CD79a (B cell markers) and CD3 were positive for reactive lymphocytes and CD56 was negative. The doses of immunosuppressive agents were reduced (mycophenolate mofetil was discontinued, cyclosporine dose reduced from 200 mg to 150 mg and prednisone continued 5 mg) and the patient received 2 cycles of adriamycin, bleomycin, vinblastine, and dacarbazine (ABVD). Neck ultrasonography following the second course of chemotherapy revealed a marked decrease in the size of the cervical lymph nodes. Radiation therapy (3600 cGy) was then administered to both cervical fields. Whole body positron emission tomography CT (PET-CT) performed 3 months following completion of radiotherapy showed no abnormal fluorodeoxyglucose (FDG) uptake in the neck. Based on a follow up ultrasonography study 8 months after completion of therapy, he was in complete remission and his creatinine level remained stable at 2.5 mg/dL.

## DISCUSSION

PTLD are a heterogeneous group of lymphoproliferative disorders associated with immunosuppression, with an incidence of 1% to 8% reported in recipients of solid organ transplants<sup>10</sup>. These disorders are characterized by EBV-driven proliferation of B-lymphocytes in the face of impaired T-cell immunity. Because of difficulties in reporting and comparing the incidence, treatment and outcome of PTLD, there is no standard classification system for them. Usually, PTLD are classified into two major categories, including polymorphic and monomorphic PTLD. The majority of monomorphic PTLD cases are non-Hodgkin's lymphoma of B-cell origin. The risk factors in the development of PTLD include EBV-seronegative recipients, use of potent immunosuppressive agents, concurrent cytomegalovirus infection, young age, and simultaneous hepatitis C infection<sup>11</sup>.



**Figure 1.** (A) Hematoxylin and eosin staining of the microscopic section shows a mixed cellularity subtype of Hodgkin's lymphoma, which includes typical Reed-Sternberg cells (RS cells); (B) Epstein-Barr virus latent membrane protein is expressed in the RS cells.

Among these risk factors for recipients, EBV-naivety is the most important. The relative risk of PTLD is about 20 times higher in EBV-seronegative recipients compared to seropositive ones. In our case, the patient had no previously described risk factors.

Hodgkin's disease after renal transplantation is rare when compared to the incidence of non-Hodgkin's lymphoma in the same circumstance. Among 1,252 lymphomas following solid organ transplant, only 2.5% were Hodgkin's disease in the Cincinnati Transplant Tumor Registry<sup>12</sup>. As Hodgkin's disease is rare following transplantation, there is little information about the pathology, clinical characteristics, and the treatment of such cases. The French study<sup>9</sup> reported 7 cases of Hodgkin's disease occurring in solid organ transplant recipients. In this study, all patients were young males and five of 7 patients presented with stage I/II Hodgkin's disease at diagnosis. Mixed cellularity was the most frequent histology, and EBV was present in all tumors. Our patient had similar clinical findings in that he was a young male with stage IIB, mixed cellularity Hodgkin's disease, with expression of EBV LMP-1 in the Reed-Sternberg cells of his biopsied lymph node.

EBV is one of the most ubiquitous of viruses, such that more than 90% of adults have some serological evidence of EBV infection during their life-time. Recent data show that by mimicking B-cell antigen-activation pathways, EBV enters the long-lived memory B lymphocyte pool, where it evades immune elimination by an alteration in its viral gene expression<sup>13</sup>. For example, cells infected with EBV are thought to avoid apoptosis by expressing EBV LMP-1 and 2a. Most PTLD disorders are related to EBV. In the immunosuppressed state, a lack of EBV-specific cytotoxic T-lymphocytes allows for unchecked

proliferation of latently infected B cells<sup>14</sup>, and the subsequent malignant B-cell clone finally results in clinically recognized lymphoma. Hodgkin's disease may also express EBV-related proteins and EBV DNA<sup>15</sup>. Overall, 65% of Hodgkin's disease specimens contain EBV DNA in the Reed-Sternberg cells, with the mixed cellularity type being most commonly EBV-associated. LMP-1 is known to induce cell activation and proliferation and to inhibit apoptosis, and LMP-2 expression enhances cell survival and inhibits lytic cycle activation of cells<sup>13</sup>. Our case also expressed EBV-LMP-1 in Reed Sternberg cells.

For prevention of PTLD, both the use of EBV vaccine (EBV gp350) to inhibit virus binding to receptor molecules on the B-cell surface and the use of anti-viral therapy (acyclovir, gancyclovir) have been tried with variable success<sup>16, 17</sup>. If such treatment is to prove useful, routine EBV screening in high risk patients is needed, especially in the early post-transplant state. With reduced immunosuppression in the early stages of EBV infection, it may be that the host immune system can recover sufficiently to halt the EBV replicative cycle.

There is no consensus about the best approach to the treatment of PTLD. Reduction of immunosuppressive agents is the first most common management. Although there is no standard method, reduction of immunosuppression must be balanced between graft function and the patient's clinical and tumor status. Usually, it starts with reduction or discontinuation of azathioprine, followed by reduction of cyclosporine doses<sup>3, 8</sup>. In our case presented here, reduction of immunosuppression was carried out by cessation of mycophenolate mofetil treatment and a dose reduction of cyclosporine. Other treatment strategies for PTLD consist of systemic chemotherapy, monoclonal anti-B cell antibodies (anti-CD20, anti-CD-21, anti-CD24), interferon alpha, passive immunization using *in vitro* expanded EBV-specific cytotoxic T lymphocytes, and radiation therapy<sup>3</sup>. Anthracycline-based chemotherapy, such as CHOP and ProMACE-CytaBOM, results in a high response rate of about 70%<sup>18</sup> and rituximab, an anti-CD20 monoclonal antibody, has been used in refractory patients to allow for a reduction of immunosuppression<sup>19</sup>.

In the past, renal transplant recipients who subsequently develop Hodgkin's disease have had a relatively poor prognosis. Recently, several published cases<sup>6-8</sup> have shown that these patients can achieve complete remission and long-term disease-free survival using standard chemotherapy, and that allograft function could be preserved. Although the follow-up duration is short, our case achieved complete remission after 2 cycles of ABVD followed by radiation therapy and has continued to have stable renal function 8 months after apparently curative combination chemotherapy and radiotherapy.

In summary, Hodgkin's disease occurring after renal

transplantation is a rare condition and is highly associated with EBV infection. Further investigation of the role of EBV infection in the progression of Hodgkin's disease following organ transplantation in immunocompromised patients will be needed to understand this unusual condition.

## REFERENCES

- 1) Penn I. *Cancers in renal transplant recipients. Adv Ren Replace Ther* 7:147-156, 2000
- 2) Soler MJ, Puig JM, Mir M, Parrilla J, Pedro C, Salar A, Serrano S, Lloveras J. *Posttransplant lymphoproliferative disease: treatment and outcome in renal transplant recipients. Transplant Proc* 35:1709-1713, 2003
- 3) Shroff R, Rees L. *The post-transplant lymphoproliferative disorder: a literature review. Pediatr Nephrol* 19:369-377, 2004
- 4) Holmes RD, Sokol RJ. *Epstein-Barr virus and post-transplant lymphoproliferative disease. Pediatr Transplant* 6:456-464, 2002
- 5) Bedrossian J, Metivier F, Jaccard A, Binet I, Pruna A, Idatte JM. *Hodgkin's disease and cadaveric renal transplantation. Transplant Proc* 27:1783-1784, 1995
- 6) Bierman PJ, Vose JM, Langnas AN, Rifkin RM, Hauke RJ, Smir BN, Greiner TC. *Hodgkin's disease following solid organ transplantation. Ann Oncol* 7:265-270, 1996
- 7) Goyal RK, McEvoy L, Wilson DB. *Hodgkin disease after renal transplantation in childhood. J Pediatr Hematol Oncol* 18:392-395, 1996
- 8) Dharmidharka VR, Douglas VK, Hunger SP, Fennell RS. *Hodgkin's lymphoma after post-transplant lymphoproliferative disease in a renal transplant recipient. Pediatr Transplant* 8:87-90, 2004
- 9) Garnier JL, Lebranchu Y, Dantal J, Bedrossian J, Cahen R, Assouline D, Jaccard A, Fetsisoff F, Moreau A, Martin X, Delsol G, Berger F, Touraine JL. *Hodgkin's disease after transplantation. Transplantation* 61:71-76, 1996
- 10) Pham PT, Wilkinson AH, Gritsch HA, Pham PC, Miller JM, Lassman CR, Danovitch GM. *Monotherapy with the anti-CD20 monoclonal antibody rituximab in a kidney transplant recipient with posttransplant lymphoproliferative disease. Transplant Proc* 34:1178-1181, 2002
- 11) Dharmidharka VR, Sullivan EK, Stablein DM, Tejani AH, Harmon WE. *Risk factors for posttransplant lymphoproliferative disorder (PTLD) in pediatric kidney transplantation: a report of the North American Pediatric Renal Transplant Cooperative Study (NAPRTCS). Transplantation* 71:1065-1068, 2001
- 12) Penn I. *Neoplastic complications of transplantation. Semin Respir Infect* 8:233-239, 1993
- 13) Macsween KF, Crawford DH. *Epstein-Barr virus-recent advances. Lancet Infect Dis* 3:131-140, 2003
- 14) Savoie A, Perpete C, Carpentier L, Joncas J, Alfieri C. *Direct correlation between the load of Epstein-Barr virus-infected lymphocytes in the peripheral blood of pediatric transplant patients and risk of lymphoproliferative disease. Blood* 83:2715-2722, 1994
- 15) Haluska FG, Brufsky AM, Canellos GP. *The cellular biology of the Reed-Sternberg cell. Blood* 84:1005-1019, 1994
- 16) Gu SY, Huang TM, Ruan L, Miao YH, Lu H, Chu CM, Motz M, Wolf

- H. *First EBV vaccine trial in humans using recombinant vaccinia virus expressing the major membrane antigen. Dev Biol Stand 84:171-177, 1995*
- 17) Darenkov IA, Marcarelli MA, Basadonna GP, Friedman AL, Lorber KM, Howe JG, Crouch J, Bia MJ, Klinger AS, Lorber MI. *Reduced incidence of Epstein-Barr virus-associated posttransplant lymphoproliferative disorder using preemptive antiviral therapy. Transplantation 64:848-852, 1997*
- 18) Swinnen LJ, Mullen GM, Carr TJ, Costanzo MR, Fisher RI. *Aggressive treatment for postcardiac transplant lymphoproliferation. Blood 86:3333-3340, 1995*
- 19) Pham PT, Wilkinson AH, Gritsch HA, Pham PC, Miller JM, Lassman CR, Danovitch GM. *Monotherapy with the anti-CD20 monoclonal antibody rituximab in a kidney transplant recipient with posttransplant lymphoproliferative disease. Transplant Proc 34:1178-1181, 2002*