

Novel Approach to Medullary Oblongata Cavernous Hemangioma

Abstract

We report the case of a 31-year-old male patient who presented with complaints of left upper and lower limb weakness with giddiness, imbalance while walking, hiccups, nasal regurgitation, and history of difficulty in swallowing. He was evaluated and diagnosed to have a space-occupying lesion in the left medulla oblongata-cavernous hemangioma. He underwent suboccipital craniotomy and excision of the lesion. Postoperatively, he regained strength and balance. He is asymptomatic during follow-up.

Keywords: Brainstem lesions, hemiparesis, medulla oblongata, medullary cavernous hemangioma

Introduction

Cavernous hemangiomas are present in about 0.5% of the population.^[1] The incidence of cavernous malformations in the medulla oblongata is about 5%.^[2] There is a risk of hemorrhage, significant mortality, and morbidity in these patients. The patient presents with a variety of symptoms, depending on the level of hemorrhage and lesion. Surgery is the mainstay of treatment.^[3]

Case Report

A 31 year old male patient presented with complaints of sudden onset left-sided weakness with giddiness, imbalance while walking, nasal regurgitation, hiccups, and difficulty in swallowing. On examination, he was conscious oriented to time, place, and person. His neurological examination revealed left hemiparesis (grade-4), left facial paresis (House–Brackmann grade-3), left palatal palsy with decreased gag reflex, and left vocal cord palsy. His biochemical screening was in the normal limit.

Magnetic resonance imaging brain [Figure 1]

There is a lesion in the posterolateral medulla oblongata in the region of the restiform body, about $14.3 \times 16.6 \times 16.3$ mm (transverse \times AP \times CC) in size. It is hyperintense on T1 and shows mixed hypo- and hyperintense signals on T2. There is a

thin complete hemosiderin ring around T2 WI and shows heterogeneous blooming on gradient images. Minimal edema is seen in the surrounding area which causes mass effect on the fourth ventricle.

Ultrasonography of the abdomen and pelvis

Two hyper echoic lesions measuring 2.2 cm and 1.1 cm in segment VIII of right lobe of liver, suggestive of liver hemangioma.

Procedure and follow-up

The patient was put in the prone position and 3-point fixation was done. A midline suboccipital vertical incision was taken. Suboccipital bone and C1 arch are exposed. Suboccipital bone was drilled and excised. Foramen magnum opened. Hemostasis achieved. Dura opened in “v” manner and cerebrospinal fluid drained by opening cisterna magna. Cerebellum seen lax and pulsating. Arachnoid opened. Interhemispheric and telovelar approach was taken. The fourth ventricle opened. Bulge was noted on the lateral wall of the fourth ventricle. A small opening was made. Clot with hemangioma visualized. [Figure 2] Piecemeal excision was done till the gliotic plane was seen all around. Dura closure was done using durapatch. Postsurgery, the patient was extubated and monitored during hospital stay. Histopathological examination revealed dilated spaces around blood vessels suggestive of cavernous hemangioma. [Figure 3] His facial paresis (grade-2) and hemiparesis improved during 1-week postsurgery, but he

**Nithish Korimerla,
Anand Doshi¹,
Prashant
Khandelwal¹,
Sudhir
Sudumbrekar¹**

Departments of Surgery
and ¹Neurosurgery, Bharati
Vidyapeeth Deemed University
Medical College, Pune,
Maharashtra, India

Address for correspondence:

Dr. Anand Doshi,
Department of Neurosurgery,
Bharati Vidyapeeth Deemed
University Medical College,
Pune, Maharashtra, India.
E-mail: drananddoshi@
gmail.com

Access this article online

Website: www.asianjns.org

DOI: 10.4103/ajns.AJNS_362_20

Quick Response Code:



How to cite this article: Korimerla N, Doshi A, Khandelwal P, Sudumbrekar S. Novel approach to medullary oblongata cavernous hemangioma. Asian J Neurosurg 2021;16:603-5.

Submitted: 25-Jul-2020

Revised: 06-Sep-2020

Accepted: 26-Mar-2021

Published: 14-Sep-2021

This is an open access journal, and articles are distributed under the terms of the Creative Commons Attribution-NonCommercial-ShareAlike 4.0 License, which allows others to remix, tweak, and build upon the work non-commercially, as long as appropriate credit is given and the new creations are licensed under the identical terms.

For reprints contact: WKHLRPMedknow_reprints@wolterskluwer.com

continued to have Ryles tube feeds. One-month postsurgery, he was able to ambulate without support with subtle weakness and was able to tolerate orally without dysphagia.

Discussion

Cavernous hemangiomas of the medulla oblongata are rare presentations. Incidence is about 5% of all brain stem hemangiomas. Cavernous malformations occur in a sporadic manner or autosomal dominant inherited conditions. Cerebral malformations present in the Hispanic population are familial compared to sporadic disease in Caucasians. Familial cavernous hemangiomas have been attributed to mutations at three different loci: CCM1 on 7q21.2, CCM2 on 7p15-p13, or CCM3 on 3q25.2-q27.^[4] As in our case, the patient had hemangioma in the medulla oblongata and also in the liver which shows genetic predisposition.

The incidence of risk of bleeding is about 2.7%. The risk of rebleeding is about 21%. The medulla oblongata contains the cardiac, respiratory, vomiting, and vasomotor centers and regulates autonomic, involuntary functions such as breathing, heart rate, and blood pressure. It contains corticospinal tracts, ascending sensory tracts of fasciculus cuneatus, and gracilis with nuclei of VIII, IX, X, XI, and XII nerves. Hence, an important center for sensory and motor relay with decussation. Hence, hemorrhage in this area presents with signs of hemiparesis and cranial nerve palsy of IX nerve palsy with sensory deficit and hemiparesis.^[5,6] Rare presentations include persistent hiccups.^[7]

Surgical resection of cavernous hemangiomas is usually selected during the subacute stage^[8] because of the favorable dissection plane or gliotic plane, except for patients who experience severe and progressive neurologic deficits and need emergency surgical intervention.^[9] Electrophysiologic monitoring of the cranial nerves and nuclei mapping should be routinely performed and are useful in gaining precise feedback information intraoperatively to avoid the direct damage of the critical structure.

Usually, three distinct approaches were applied to the resection of cavernous hemangiomas involving the medulla oblongata: the far-lateral craniotomy was used for lesions in the lateral or anterolateral portion of the medulla or the pontomedullary junction; the retrosigmoid craniotomy was used for lesions in the anterolateral pontomedullary junction, especially for lesions predominantly located in the pons and posterior sub occipital craniotomy was used for lesions in the floor of the fourth ventricle or posterior medulla. The safe entry zone was determined based on the pial presentation, brainstem anatomic landmarks, intraoperative neuronavigation, and nuclei mapping.^[3]

Major complications of surgery include deficit of active or passive cough reflexes, facial palsy, need for gastrostomy in patients having severe dysphagia,

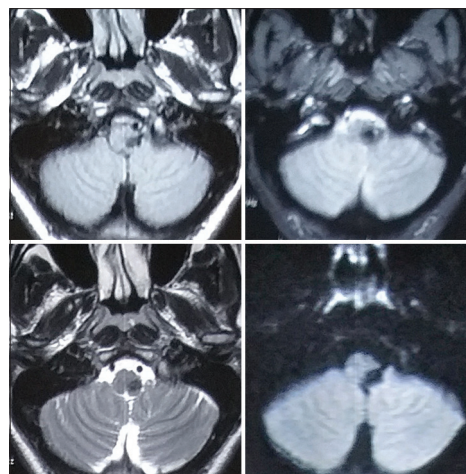


Figure 1: Magnetic resonance imaging of the brain - showing tumor




Figure 2: Intraoperative picture: visualized cavernous hemangioma

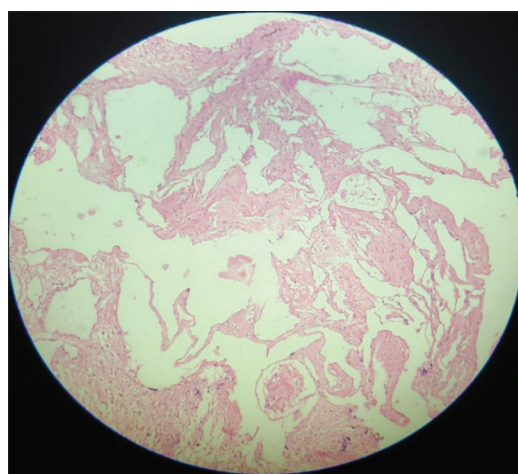


Figure 3: Histopathology: Dilated spaces around blood vessels suggestive of cavernous malformation

tracheostomy, and ventilator-associated complications. Brain stem cavernous malformations, with at least one prior symptomatic bleeds or progressive neurological deficits with clearly superficial pial or ependymal representation are good candidates for microsurgical resection, which can be reached through a small minimal

incision of the brainstem surfaces without crossing healthy tissue.

The application of new technologies such as intraoperative image navigation and diffusion tensor imaging could improve the outcome of patients. However, for reducing the likelihood of postoperative morbidity due to brainstem nuclear and tract injury, complete resection is not always the goal for brain stem cavernous malformations for those deep-seated lesions.^[10]

In our patient, a novel approach was done through the fourth ventricle and cavernoma was excised without any injury to cortical fibers. Hence posterior medullary oblongata lesions can be safely approached through the fourth ventricle after meticulous planning.

Conclusion

Incidence of medullary cavernous hemangiomas is rare. Surgery is the mainstay of treatment in medullary cavernous hemangioma. A favorable outcome of surgery is achieved following, meticulous preparation, investigations, and approach. Although symptoms of the disease are not completely relived, quality of life, mortality and morbidity, and rehemorrhage have significantly reduced.

Financial support and sponsorship

Nil.

Conflicts of interest

There are no conflicts of interest.

References

1. Bokhari MR, Al-Dhahir MA. Brain cavernous angiomas. In: StatPearls. Treasure Island (FL): StatPearls Publishing; 2020.
2. Fritschi JA, Reulen HJ, Spetzler RF, Zabramski JM. Cavernous malformations of the brain stem. A review of 139 cases. *Acta Neurochir (Wien)* 1994;130:35-46.
3. Abla AA, Lekovic GP, Turner JD, de Oliveira JG, Porter R, Spetzler RF. Advances in the treatment and outcome of brainstem cavernous malformation surgery: A single-center case series of 300 surgically treated patients. *Neurosurgery* 2011;68:403-14.
4. Dashti SR, Hoffer A, Hu YC, Selman WR. Molecular genetics of familial cerebral cavernous malformations. *Neurosurg Focus* 2006;21:e2.
5. Xie MG, Xiao XR, Guo FZ, Zhang JT, Wu Z, Zhang LW. Surgical management and functional outcomes of cavernous malformations involving the medulla oblongata. *World Neurosurg* 2018;119:e643-52.
6. Zhang S, Lin S, Hui X, Li H, You C. Surgical treatment of cavernous malformations involving medulla oblongata. *J Clin Neurosci* 2017;37:63-8.
7. Musumeci A, Cristofori L, Bricolo A. Persistent hiccup as presenting symptom in medulla oblongata cavernoma: A case report and review of the literature. *Clin Neurol Neurosurg* 2000;102:13-7.
8. Petr O, Lanzino G. Brainstem cavernous malformations. *J Neurosurg Sci* 2015;59:271-82.
9. Tumturk A, Li Y, Turan Y, Cikla U, Iskandar BJ, Baskaya MK. Emergency resection of brainstem cavernous malformations. *J Neurosurg* 2018;128:1289-96.
10. Chen LH, Zhang HT, Chen L, Liu LX, Xu RX. Minimally invasive resection of brainstem cavernous malformations: Surgical approaches and clinical experiences with 38 patients. *Clin Neurol Neurosurg* 2014;116:72-9.