



## A rare case of spontaneous bladder perforation with osteomyelitis and paravesical abscess due to CA-MRSA clone USA100/ST5

Ricardo Torres da Silveira Ugino<sup>a,\*</sup>, Valéria Cassettari<sup>b</sup>, Brenda Margatho Ramos Martines<sup>c</sup>, Ricardo Iturbe Larenas<sup>d</sup>, Gregory Melocco<sup>e,f</sup>, Oscar Eduardo Hidetoshi Fugita<sup>a,d</sup>

<sup>a</sup> Surgery Department, Hospital Universitário, Universidade de São Paulo, São Paulo, Brazil

<sup>b</sup> Hospital Infection Control Committee, Hospital Universitário, Universidade de São Paulo, São Paulo, Brazil

<sup>c</sup> Radiology Department, Hospital Universitário, Universidade de São Paulo, São Paulo, Brazil

<sup>d</sup> Urology Department, Faculdade de Medicina de Botucatu, Universidade Estadual Paulista, São Paulo, Brazil

<sup>e</sup> Department of Clinical Analysis, School of Pharmacy, University of São Paulo, São Paulo, Brazil

<sup>f</sup> One Health Brazilian Resistance Project (OneBR), Brazil

### ARTICLE INFO

#### Keywords:

Bladder perforation  
Pelvic abscess  
Osteomyelitis  
CA-MRSA  
Penile prosthesis

### ABSTRACT

Spontaneous rupture of the urinary bladder represents a rare condition that may complicate with paravesical abscess. Although *Staphylococcus aureus* may be a part of the intestinal tract flora, it is an unusual cause of abdominal or pelvic abscesses. We report the case of a male patient with spontaneous bladder perforation with osteomyelitis and paravesical abscess, secondary to community-acquired methicillin-resistant *Staphylococcus aureus* infection.

### 1. Introduction

Spontaneous Bladder Perforation (SBP) represents a rare occurrence often resulting from an underlying pathology. Complications of bladder rupture may include paravesical abscess and peritonitis. In this regard, abscesses are usually polymicrobial comprising intestinal flora. Although *Staphylococcus aureus* may be a part of the intestinal tract flora, it is an unusual cause of abdominal or pelvic abscesses.<sup>1</sup>

Community-acquired methicillin-resistant *Staphylococcus aureus* (CA-MRSA) has emerged worldwide since the 1990s. This pathogen has genetic and pathogenic characteristics distinct from hospital endemic MRSA strains, and often causes invasive infections such as necrotizing pneumonia, severe infections of soft tissues and spine and long bone osteomyelitis.<sup>1</sup> Rare cases of prostatic abscesses caused by CA-MRSA have been described in the literature,<sup>2</sup> but no cases of bladder perforation or osteomyelitis in pubis associated with this agent have been reported to date. We hereby report the case of a male patient with SBP with osteomyelitis and paravesical abscess caused by CA-MRSA.

### 2. Case presentation

A 66-year-old male patient was admitted to a primary hospital with a

10-day history of difficulty in walking due to a disabling pubic pain with bilateral irradiation to the perineal and inguinal regions, fever and darkening of urine. He started treatment for lower urinary tract infection with ciprofloxacin at the primary hospital, but presented with worsening of symptoms after 3 days when he was referred to our hospital. His past medical record included diabetes, hypertension, use of inhaled cocaine, cataract surgery 10 days before symptoms, and semi rigid penile prosthesis (PP) placement 30 years ago.

Physical examination was normal, except for pubic symphysis tenderness, and a mild perineal hyperemia without the presence of a floating point or surrounding necrotic tissue. Special attention was taken to the eyes, skin, and rhinopharynx lesions, and respiratory and cardiovascular alterations, but they were all unremarkable.

A laboratory work-up revealed leukocytosis (19530/mm<sup>3</sup>) and elevated reactive c-protein (160 mg/L). Other laboratory tests including red cell count, coagulation profile, renal function tests, and serum electrolytes were normal. HIV serology was negative. Computed tomography (CT) scan revealed signs of osteomyelitis involving the pubic symphysis, as well as an increase in the volume of soft tissues involving the pectineus, and internal and external obturator muscles on the left. Additionally, there was a 2-cm liquefied collection extending to the retropubic space associated with gaseous images. There was no

\* Corresponding author.

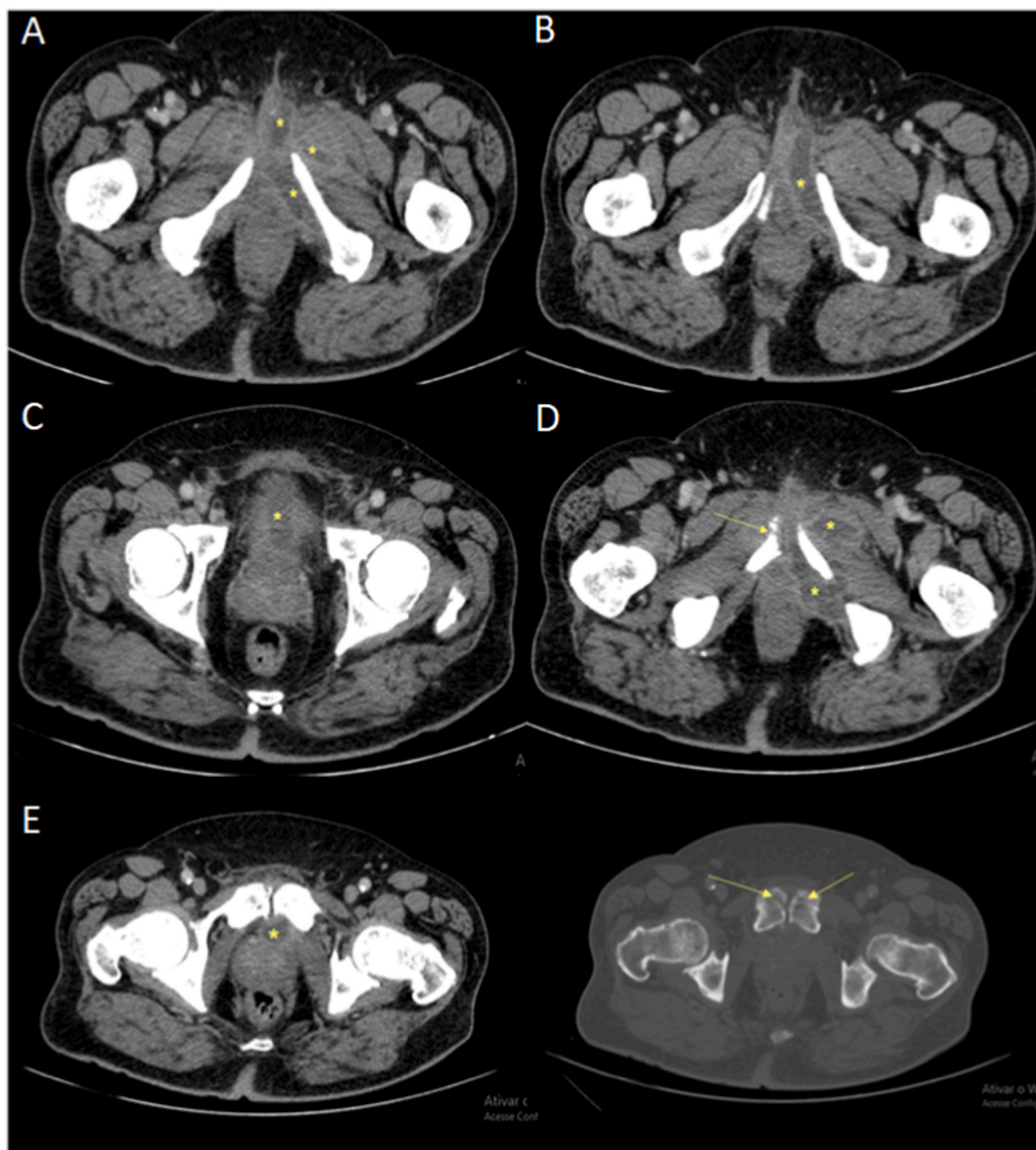
E-mail address: [ricardougino@gmail.com](mailto:ricardougino@gmail.com) (R. Torres da Silveira Ugino).

<https://doi.org/10.1016/j.eucr.2022.102018>

Received 10 January 2022; Received in revised form 25 January 2022; Accepted 29 January 2022

Available online 1 February 2022

2214-4420/© 2022 Published by Elsevier Inc. This is an open access article under the CC BY-NC-ND license (<http://creativecommons.org/licenses/by-nc-nd/4.0/>).



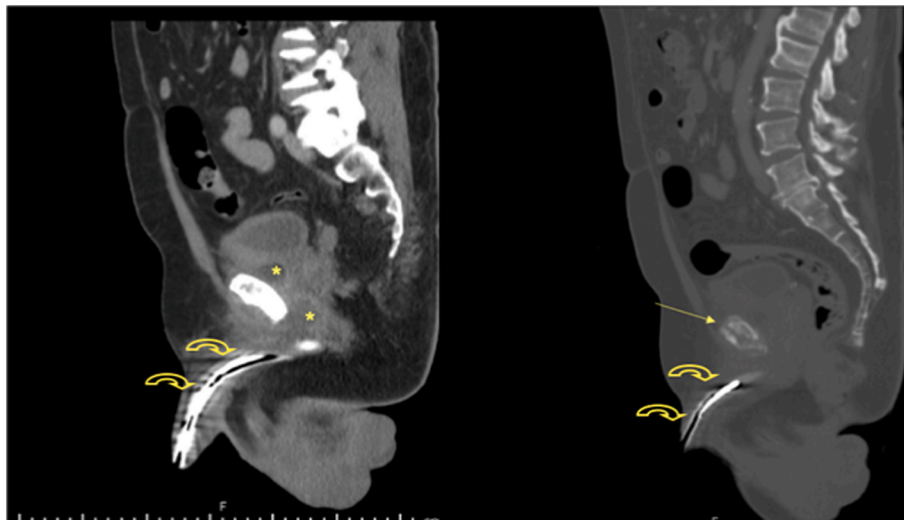
**Fig. 1.** Computed tomography (CT) scan (axial view) of the abdomen. In A and B, note the high density of adjacent fatty planes and an increase of soft tissue involving the pectineus, and the internal and external obturator muscles as well as liquefied collections (\*) on the left side of the patient. In C, the collection (\*) extends to the retropubic space associated with gaseous images. In D and E, signs of osteomyelitis involving the pubic symphysis characterized by lytic bone lesions (yellow arrows) and nearby collections (\*). (For interpretation of the references to colour in this figure legend, the reader is referred to the Web version of this article.)

communication between the abscess and the PP (Fig. 1 and Fig. 2).

Urology and orthopedics were consulted about the diagnosis of initial Fournier syndrome, osteomyelitis and paravesical abscess, and surgery was indicated. Intra-operative findings demonstrated a retropubic abscess in close contact with a 3-cm anterior bladder wall perforation and the pubic bone. Surgery confirmed the lack of communication between the abscess and the PP. Drainage of the retropubic collection with sampling for culture was carried out, followed by bladder raffia, debridement and curettage of the pubic symphysis due to the osteomyelitis.

The patient was discharged home on postoperative day 4, with bladder catheter and empirical treatment with ciprofloxacin and

clindamycin. On postoperative day 7, he returned to the outpatient clinic without complaints, and the bladder catheter was withdrawn. The bone culture was positive to MRSA displaying sensitivity to clindamycin, erythromycin, gentamycin, levofloxacin, linezolid, rifampicin, trimethoprim/sulfamethoxazole, teicoplanin and vancomycin, as determined by VITEK 2 system (bioMérieux). The patient received ciprofloxacin associated with clindamycin for two weeks, and then sulfamethoxazole-trimethoprim for another four weeks, with outpatient follow-up. The MRSA isolate was characterized by whole genome sequencing using 150-bp paired-end library on a Illumina NextSeq platform, and clinically relevant genomic information was obtained by tools available at the Center for Genomic Epidemiology (<https://www.genomicepidemiology>).



**Fig. 2.** Computed tomography (CT) scan (sagittal view) of the abdomen. No communication between the liquefied collections (\*) and the penile prosthesis (yellow curved arrow) is seen. Signs of osteomyelitis involving the pubic symphysis (yellow straight arrow) are also revealed in this image from a different perspective. (For interpretation of the references to colour in this figure legend, the reader is referred to the Web version of this article.)

org/), which included prediction of resistome, virulome, SCCmec gene typing, and multilocus sequence typing.

Genomic analysis revealed that MRSA strain HU-USP/906966501 carried both *mecA* and *blaZ* genes, which confer resistance to beta-lactams, and the *aph(3')-III* gene conferring resistance to amikacin. Noteworthy, presence of the *lukF-PV* gene encoding for the Panton-Valentine Leukocidin (PVL, toxin involved in primary skin infections, musculoskeletal disorders, necrotizing pneumonia, brain abscess, and other diseases, some of which are life-threatening) was confirmed, whereas no other virulence factors were detected in the genome. Epidemiologically, the MRSA strain belonged to high-risk international clone USA100/ST5/SCCmec type IV.

### 3. Discussion

The diagnosis and management of the pelvic CA-MRSA abscess herein posed several questions. The first is the origin of the abscess. Initially, it was assumed that the patient could have developed osteomyelitis and paravesical abscess secondary to an infection of the PP. However, the PP placement took place 30 years ago, there were no signs of perineal alterations on the CT scan and surgical findings indicated the absence of communication between the pelvic abscess and the PP. Indeed, surgery showed an intact surgical plane between the abscess and the corpora cavernosa. It is important to point out that the minority (2.6%) of PP infections occurs after 5 years of surgery.<sup>3</sup> Therefore, this hypothesis seems unlikely. Another unusual presentation of this case is the SBP. Whereas SBP is a rare event with virtually all of the reported cases having an underlying condition, idiopathic cases have been reported and should not be excluded.<sup>4</sup>

In regards to CA-MRSA infections, inhaled drug abuse has been associated with severe forms, ranging from abscesses to endocarditis. The use of inhalational drugs can alter the integrity of the nasal mucosa and precipitate MRSA nasal colonization. In fact, previous studies have demonstrated that intravenous and inhalational drug users are colonized by MRSA, specifically in the nose.<sup>5</sup> However, in this study, the otolaryngologist ruled out any lesion in this patient, and the nasal secretion culture was negative, although it was collected after antibiotic treatment was completed. Therefore, our main hypothesis is that the patient previously colonized by CA-MRSA, related to the use of inhaled cocaine, had SBP, which was the entrance to deep infection by this potentially invasive high-risk clone.

### 4. Conclusion

Bladder perforation and CA-MRSA infection represent life-threatening conditions that require prompt diagnosis and management. This case illustrates a rare event with an unusual presentation that urologists, orthopedists and primary care physicians may face and must be aware of.

### Section headings

Inflammation and Infection.

### Declarations of competing interest

There are no conflicts of interest. The author(s) received no financial support for the research, authorship, and/or publication of this article. This work was supported by the Fundação de Amparo à Pesquisa do Estado de São Paulo (FAPESP, 2020/08224–9) and Conselho Nacional de Desenvolvimento Científico e Tecnológico (CNPq, 422984/2021–3). Gregory Melocco<sup>e</sup> is a research fellow of CNPq (130767/2021–2).

### Acknowledgments

We thank Nilton Lincopan, Fernanda Esposito, Brenda Cardoso, Elder Sano and the Department of Microbiology of the Institute of Biomedical Sciences, University of São Paulo (São Paulo – Brazil) for the microbiological/genomic analysis and review of this article.

### References

1. Tong SY, Davis JS, Eichenberger E, et al. *Staphylococcus aureus* infections: epidemiology, pathophysiology, clinical manifestations, and management. *Clin Microbiol Rev.* 2015;28:603–661. <https://doi.org/10.1128/CMR.00134-14>.
2. Carroll DE, Marr I, Huang GKL, et al. *Staphylococcus aureus* prostatic abscess: a clinical case report and a review of the literature. *BMC Infect Dis.* 2017;17:1–7. <https://doi.org/10.1186/s12879-017-2605-4>.
3. Fishman IJ, Scott FB, Selim AM. Rescue procedure: an alternative to complete removal for treatment of infected penile prosthesis. *J Urol.* 1987;137:202A. [https://doi.org/10.1016/s0022-5347\(17\)75546-2](https://doi.org/10.1016/s0022-5347(17)75546-2).
4. Kabarriti AE, Ramchandani P, Guzzo TJ. Spontaneous urinary bladder perforation: an unusual presentation of diabetes mellitus. *Urol Case Reports.* 2014;2:109–111. <https://doi.org/10.1016/j.eucr.2014.03.005>.
5. El-Sharif A, Ashour HM. Community-acquired methicillin-resistant *Staphylococcus aureus* (CA-MRSA) colonization and infection in intravenous and inhalational opiate drug abusers. *Exp Biol Med.* 2008;233:874–880. <https://doi.org/10.3181/0711-RM-294>.