

Lung ultrasound score for the assessment of lung aeration in ARDS patients: comparison of two approaches

OPEN
ACCESS

Authors

Silvia Mongodi¹ , Davide Chiumello^{2, 3, 4}, Francesco Mojoli^{5, 1}

Affiliations

- 1 Anesthesiology and Intensive Care, San Matteo Hospital, Pavia, Italy
- 2 Department of Health Sciences, University of Milan, Milano, Italy
- 3 Anaesthesia and Intensive Care, San Paolo University Hospital, Milano, Italy
- 4 Coordinated Research Center on Respiratory Failure, University of Milan, Milano, Italy
- 5 Anesthesiology, Intensive Care and Pain Medicine, San Matteo Hospital, Pavia, Italy

Keywords

lung ultrasound score, lung monitoring, quantitative lung ultrasound, lung density, lung aeration

received 15.02.2024

accepted after revision 21.07.2024

published online 2024

Bibliography

Ultrasound Int Open 2024; 10: a24218709

DOI 10.1055/a-2421-8709

ISSN 2509-596X

© 2024. The Author(s).

This is an open access article published by Thieme under the terms of the Creative Commons Attribution-NonDerivative-NonCommercial-License, permitting copying and reproduction so long as the original work is given appropriate credit. Contents may not be used for commercial purposes, or adapted, remixed, transformed or built upon. (<https://creativecommons.org/licenses/by-nc-nd/4.0/>).

Georg Thieme Verlag KG, Rüdigerstraße 14,
70469 Stuttgart, Germany

Correspondence

Dr. Silvia Mongodi
Anesthesiology and Intensive Care, Foundation IRCCS
Polyclinic San Matteo
Viale Golgi 19
27100 Pavia
Italy
s.mongodi@smatteo.pv.it



Supplementary Material is available at
<https://doi.org/10.1055/a-2421-8709>

ABSTRACT

Purpose A 4-step lung ultrasound (LUS) score has been previously used to quantify lung density. We compared 2 versions of this scoring system for distinguishing severe from moderate loss of aeration in ARDS: coalescence-based score (cLUS) vs. quantitative-based score (qLUS – > 50% pleura occupied by artefacts).

Materials and Methods We compared qLUS and cLUS to lung density measured by quantitative CT scan in 12 standard thoracic regions. A simplified approach (1 scan per region) was compared to an extensive one (regional score computed as the mean of all relevant intercostal space scores).

Results We examined 13 conditions in 7 ARDS patients (7 at PEEP 5, 6 at PEEP 15 cmH₂O-156 regions, 398 clips). Switching from cLUS to qLUS resulted in a change in interpretation in 117 clips (29.4%, 1-point reduction) and in 41.7% of the regions (64 decreases (range 0.2–1), 1 increase (0.2 points)). Regional qLUS showed very strong correlation with lung density ($r_s = 0.85$), higher than cLUS ($r_s = 0.79$; $p = 0.010$). The agreement with CT classification in well aerated, poorly aerated, and not aerated tissue was moderate for cLUS (agreement 65.4%; Cohen's K coefficient 0.475 (95%CI 0.391–0.547); $p < 0.0001$) and substantial for qLUS (agreement 81.4%; Cohen's K coefficient 0.701 (95%CI 0.653–0.765), $p < 0.0001$). The agreement between single spot and extensive approaches was almost perfect (cLUS: agreement 89.1%, Cohen's kappa coefficient 0.840 (95%CI 0.811–0.911), $p < 0.0001$; qLUS: agreement 86.5%, Cohen's kappa coefficient 0.819 (95%CI 0.761–0.848), $p < 0.0001$).

Conclusion A LUS score based on the percentage of occupied pleura performs better than a coalescence-based approach for quantifying lung density. A simplified approach performs as well as an extensive one.

Introduction

Since a relationship between lung ultrasound (LUS) and lung density was described in vitro [1], multiple quantification approaches have been developed in different clinical contexts [2]. A LUS score based on 4 steps of progressive loss of aeration according to the number and type of visualized artifacts has been validated in critically ill patients [3, 4]. The quantitative approach allows LUS to switch from a diagnostic [5] to a monitoring tool, with multiple applications at the bedside including assessment of the severity of acute respiratory failure [6–8], guide for treatments [9–16], daily monitoring of lung recovery [17–20], and early detection of complications [21, 22], finally leading to a reduced need for traditional imaging [23]. Since its first description [4, 14, 15], some improvements have been proposed to distinguish between moderate (score 1) and severe (score 2) loss of aeration [24, 25] in an attempt to overcome the tendency of LUS score to overestimate lung density [4, 26]. The aim of this study was to compare two LUS score approaches to quantitative CT in ARDS patients.

Materials and Methods

The patients were enrolled in a prospective study performed at our university hospitals and approved by the institutional review board. Written consent was obtained according to Italian regulations. The current analysis included 7 patients having undergone double LUS examination for interobserver agreement assessment. Only the second operator's exams were analyzed to avoid data replication. The examinations were performed at two PEEP levels (5 and 15 cmH₂O)

Lung ultrasound

LUS was performed as previously described in 12 regions, in a transversal scan [4]. In each region, all intercostal spaces were examined. One clip acquired in the center of the region was identified as “single spot” to compare a simplified approach (1 scan per region) to the extensive one (all intercostal spaces per region).

LUS clips were analyzed offline by 2 expert physicians blinded to the patients' identity, PEEP level, lung region, and CT findings.

Two different LUS scores were computed (► Fig. 1):

1. cLUS score – coalescence-based: presence of A-line alone/less than three B-lines (0 point); at least three well-spaced B-lines (1 point); coalescent B-lines (2 points); any tissue-like pattern (3 points).
2. qLUS score – quantitative-based: presence of A-line alone/less than three B-lines (0 point); artifacts (at least three well-spaced B-lines, coalescent B-lines, or subpleural consolidations) occupying $\leq 50\%$ of visualized pleura (1 point); artifacts occupying clearly $>50\%$ of visualized pleura (2 points); tissue-like pattern as the prevalent pattern with thickness >2.5 cm (3 points).

Regional cLUS and qLUS scores corresponded to the rounded average score of all pertaining intercostal spaces (range 0–3); average scores with decimal digit equal to 5 were rounded down. Global cLUS and qLUS scores were the sum of regional scores (range 0–36).

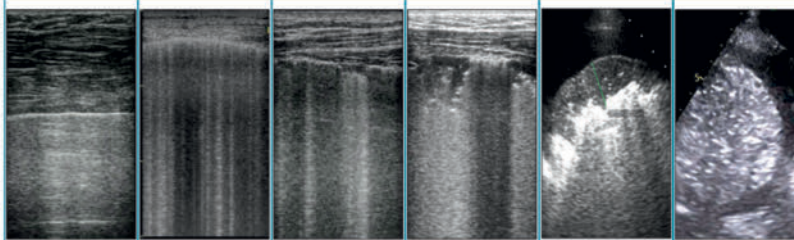
CT analysis

Lung CT was performed and analyzed as previously described [4]. Lung tissue was classified according to lung density as not aerated (+100 and –100HU), poorly aerated (–101 and –500HU), normally aerated (–501 and –900HU), hyper-inflated (–901 and –1000HU) [27]. Each lung was divided into six areas to mirror ultrasound regions: three of equal height along the sternum-vertebral axis, each divided into two of equal height along the apex-base axis. The regional and overall lung tissue density was computed.

Statistical analysis

Power calculation was not performed since this was an exploratory analysis comparing different LUS approaches. Data are expressed as median [interquartile range] or mean \pm SD for quantitative variables, as number (%) for categorical ones. Normal distribution was assessed by the Shapiro-Wilk test.

The difference in the classification/scores of clips and regions by cLUS/qLUS was tested by Fisher's exact test or t-test/Wilcoxon rank



	A-lines or a maximum of 2 well-spaced B-lines	Multiple well-spaced B-lines occupying $>50\%$ of the pleura	Focal coalescence or subpleural consolidations occupying $<50\%$ of the pleura	Coalescent B-lines with subpleural consolidations occupying clearly $>50\%$ of the pleura	Tissue-like pattern with peripheral involvement <2.5 cm of thickness	Tissue-like pattern as prevalent pattern (lobar/hemi-lobar involvement)
cLUS	0	1	2	2–3	3	3
qLUS	0	2	1	2	2	3

► Fig. 1 Interpretation of lung ultrasound patterns with a coalescence-based score (cLUS) and a quantitative-based one (qLUS).

sum test for repeated measures. The difference in lung density in different cLUS/qLUS categories was tested by one-way ANOVA with Bonferroni method of adjustment for multiple comparison.

A Spearman rank correlation (r_s) was run to assess the relationship between regional cLUS/qLUS scores and average tissue density on CT (classic cut-off for the interpretation of the strength of association: 0–0.19 very weak, 0.20–0.39 weak, 0.40–0.59 moderate, 0.60–0.79 strong, 0.80–1.0 very strong). Cohen’s kappa coefficient was computed to measure the agreement between CT and ultrasound classification and between ultrasound approaches (classic cut-off for interpretation: < 0.20-null; 0.21–0.40-fair; 0.41–0.60-moderate; 0.61–0.80-substantial; 0.81–1.00-almost perfect [28]).

Difference between cLUS/qLUS global scores was tested by the Sign test for repeated measures. A simple linear regression model (reported with coefficient of determination- R_2) was performed to test linear relationship between global cLUS/qLUS scores and average overall CT lung density.

Analyses were performed by STATA 14.

Results

We examined 13 conditions in 7 ARDS patients (7 at PEEP 5, 6 at PEEP 15 cmH₂O), for a total of 156 regions, 398 clips. Population characteristics are provided in e-Tab. 1.

Clip interpretation

Among the 398 analyzed clips, 127 (31.9%), 13 (3.3%), 167 (42.0%), and 91 (22.9%) were classified with cLUS as scores 0, 1, 2 and 3, respectively; qLUS classified 127 (31.9%), 106 (26.6%), 98 (24.6%), and 67 (16.8%) clips as scores 0, 1, 2 and 3, respectively (e-Tab. 2). When switching from cLUS to qLUS, clip interpretation changed in 117 cases (29.4%), always with a 1-point reduction. The number of score 0 clips remained unchanged, while score 1 increased and scores 2 and 3 decreased leading to a different distribution of scores ($p < 0.001$ – e-Fig. 1). The mean score decreased (cLUS 1.6 ± 1.2 vs. qLUS 1.3 ± 1.1 ; $p < 0.0001$); the agreement between cLUS and qLUS was moderate, as expected (agreement 70.6%; Cohen’s K coefficient 0.607 (95%CI 0.582–0.633); $p < 0.0001$).

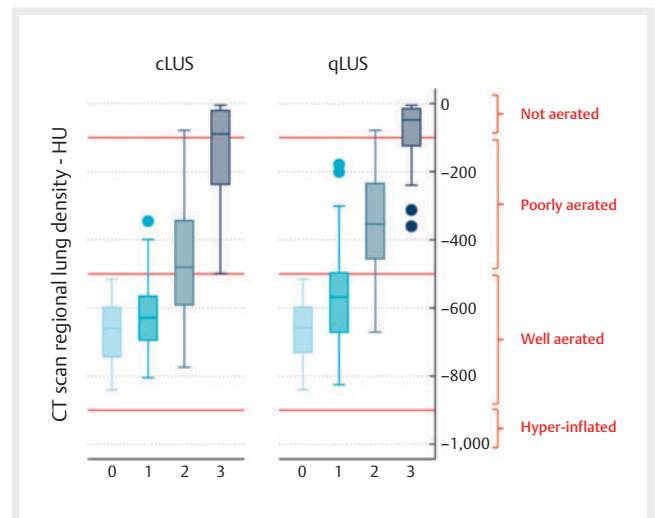
Regional aeration

When switching from cLUS to qLUS, the regional score changed in 65/156 regions (41.7% – 64 decreases (range 0.2–1), 1 increase (0.2 points)). The number of scores of 0 increased from 31 (19.9%) to 32 (20.5%), score of 1 increased from 14 (9.0%) to 47 (30.1%), score of 2 decreased from 67 (43.0%) to 46 (29.5%) and score of 3 from 44 (28.2%) to 31 (19.9%; $p < 0.001$ – e-Tab. 3; e-Fig. 2). The median regional score was higher with cLUS (2.0 [1.0–3.0] vs. 1.5 [1.0–2.0]; $p = 0.0054$); the agreement between regional cLUS and qLUS was moderate, as expected (agreement 68.0%; Cohen’s K coefficient 0.572 (95%CI 0.498–0.661); $p < 0.0001$) The agreement between single spot and extensive approaches was almost perfect (cLUS: agreement 89.1%, Cohen’s kappa coefficient 0.840 (95%CI 0.811–0.911), $p < 0.0001$; qLUS: agreement 86.5%, Cohen’s kappa coefficient 0.819 (95%CI 0.761–0.848), $p < 0.0001$ – e-Tab. 4).

► **Table 1** Regional lung density as measured by quantitative CT scan in regions classified as score 0–3 according to cLUS (coalescence-based lung ultrasound score) and qLUS (quantitative-based lung ultrasound score).

	cLUS	qLUS	p-value
Score 0	-675.1 ± 100.5	-672.0 ± 98.9	0.9021
Score 1	-617.4 ± 128.8	-564.7 ± 149.5	0.2385
Score 2	-462.0 ± 170.9	-357.7 ± 145.9	0.0010
Score 3	-147.8 ± 144.7	-81.6 ± 91.4	0.0275
P-value	$p < 0.0001^*$	$p < 0.0001^{\#}$	

*Score 1 vs. score 0: not significant; score 2 vs. score 1 $p = 0.003$; for all the other comparisons $p < 0.001$. # Score 1 vs. score 0: $p = 0.002$; for all the other comparisons $p < 0.001$.



► **Fig. 2** Box plot of regional lung density as measured by quantitative CT scan and lung aeration assessment according to cLUS score (coalescence-based lung ultrasound score) and qLUS score (quantitative-based lung ultrasound score).

Comparison to quantitative CT

Lung tissue density in each incremental increase of cLUS/qLUS is displayed in ► **Table 1**/► **Fig. 2**. The correlation with lung density was strong for regional cLUS ($r_s = 0.79$, $p < 0.0001$) and very strong for regional qLUS ($r_s = 0.85$; $p < 0.0001$). The Spearman rank-order correlation coefficient was significantly higher for qLUS vs. cLUS ($p = 0.011$).

LUS scores of 0 and 1 were grouped to allow comparison with the CT 3-step classification. The agreement between cLUS and CT was moderate (agreement 65.4%; Cohen’s K coefficient 0.475 (95%CI 0.391–0.547); $p < 0.0001$). cLUS overestimated the loss of aeration in 51 regions (32.7%) and underestimated it in 3 (1.9% – ► **Table 2**). The agreement between qLUS and CT was substantial (agreement 81.4%; Cohen’s K coefficient 0.701 (95%CI 0.653–0.765), $p < 0.0001$); qLUS overestimated lung loss of aeration in 15 regions (9.6%) and underestimated it in 14 cases (9.0%).

Table 2 Agreement between CT scan classification as well aerated, poorly aerated, and not aerated tissue according to regional lung density and lung ultrasound scores (cLUS: coalescence-based lung ultrasound score; qLUS: quantitative-based lung ultrasound score). In bold: agreement between LUS scores and CT scan.

CT scan		cLUS			qLUS		
		0–1	2	3	0–1	2	3
Well aerated		43	30	0	66	7	0
	Poorly aerated	2	36	21	13	38	8
	Not aerated	0	1	23	0	1	23

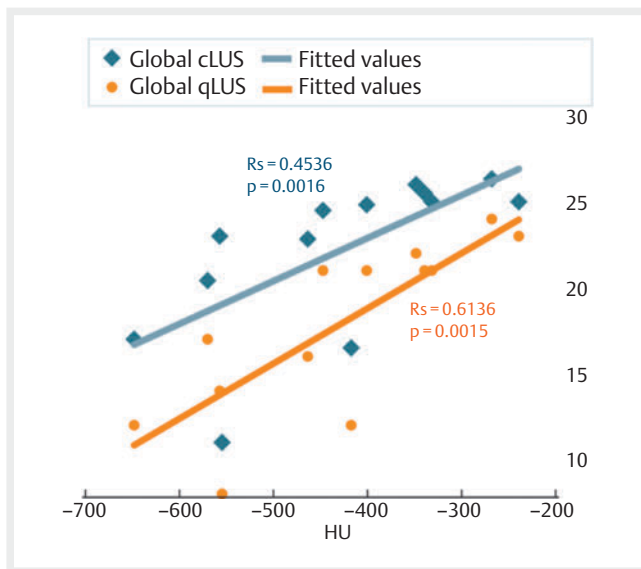


Fig. 3 Linear correlation and relative coefficients for global lung ultrasound scores measured with cLUS (coalescence-based lung ultrasound score) and qLUS (quantitative-based lung ultrasound score) and lung density measured in Hounsfield units (HU) by quantitative CT scan.

In the 13 analyzed conditions, the global LUS score was higher with cLUS vs. qLUS (24.5 [20.4–25.0] vs. 20.4 [16.0–22.0]; $p = 0.0002$). The linear regression between global LUS scores and overall tissue density is displayed in **Fig. 3** (cLUS: $R_2 = 0.4536$, $p = 0.0116$; qLUS: $R_2 = 0.6136$; $p = 0.0015$).

Discussion

The main results of this study are: 1. That a LUS score based on percentage of occupied pleura (quantitative-based) performs better than a coalescence-based one for quantifying lung density, and 2. That a single spot approach performs as well as an extensive one.

Coalescence may be a good marker of increased lung density when the loss of aeration is homogeneous [1]. However, the presence of focal coalescences in non-homogeneous diseases such as ARDS [29] may lead to the overestimation of lung density [4]. Moreover, in the first description of LUS scoring, it was unclear how to interpret subpleural consolidations – i. e., echo-poor regions applied to the pleura with irregular deep border with a diameter of at least 1 cm [30] – which are frequent findings in trauma, ventilator-

associated pneumonia, and ARDS. Subpleural consolidations are small areas with severe loss of aeration. Some authors classify them as score 3 [26], as normally performed in neonates in the case of subpleural consolidations > 1 cm [31]. However, while such an approach is justified in neonates by their small thoracic antero-posterior diameter, this may easily lead to additional overestimation of lung loss of aeration in adults. Our approach based on the percentage of occupied pleura improved LUS score performance when compared to quantitative CT, as previously demonstrated when compared to extra-vascular lung water [25].

A score based on the distinction of different steps of pleura occupation (0, 25%, 50%, 75%) has been proposed in COVID-19 patients admitted to the emergency department and showed good correlation with CT scans [32]. However, when compared to qLUS, this approach seems to have limited applicability if the lung involvement is extensive, as expected in critically ill patients [33].

Similarly, the amount of visualized tissue-like pattern required to define a score of 3 was not clear, leading to the assignment of the same score to completely consolidated lung lobes and to small peripheral consolidations. The introduced criterion (predominant tissue-like pattern with at least 2.5 cm of thickness) improved the identification of not aerated regions, as shown by regions with a higher tissue density score of 3 with qLUS vs. cLUS.

Finally, a single spot proved to be as reliable as an extensive approach. A quicker exam makes the LUS score more suitable for daily clinical practice.

As a limitation, we analyzed a limited number of patients with ARDS. Generalizability to other respiratory conditions should be confirmed.

Conclusion

An LUS score based on percentage of occupied pleura performs better than a coalescence-based one for quantifying lung density. A simplified approach performs as well as an extensive one.

Conflict of Interest

FM received fees for lectures from GE Healthcare, Hamilton Medical, SEDA SpA, outside the present work. SM received fees for lectures from GE Healthcare, outside the present work. A research agreement is active between University of Pavia and Hamilton Medical. The other authors declare no conflict of interest.

References

- [1] Soldati G, Inchingolo R, Smargiassi A, Sher S, Nenna R, Inchingolo CD, Valente S. Ex vivo lung sonography: morphologic-ultrasound relationship. *Ultrasound Med Biol* 2012; 38: 1169–1179
- [2] Mongodi S, De Luca D, Colombo A, Stella A, Santangelo E, Corradi F, Gargani L, Rovida S, Volpicelli G, Bouhemad B, Mojoli F. Quantitative Lung Ultrasound: Technical Aspects and Clinical Applications. *Anesthesiology* 2021; 134: 949–965. DOI: 10.1097/ALN.0000000000003757
- [3] Zhao Z, Jiang L, Xi X, Jiang Q, Zhu B, Wang M, Xing J, Zhang D. Prognostic value of extravascular lung water assessed with lung ultrasound score by chest sonography in patients with acute respiratory distress syndrome. *BMC Pulm Med* 2015; 15: 98
- [4] Chiumello D, Mongodi S, Algieri I et al. Assessment of Lung Aeration and Recruitment by CT Scan and Ultrasound in Acute Respiratory Distress Syndrome Patients*. *Crit Care Med* 2018; 46: 1761–1768
- [5] Mojoli F, Bouhemad B, Mongodi S, Lichtenstein D. Lung Ultrasound for Critically Ill Patients. *Am J Respir Crit Care Med* 2019; 199: 701–714
- [6] AZUREA Network Zielekiewicz L, Markarian T, Lopez A, Taguet C, Mohammedi N, Boucekinge M, Baumstarck K, Besch G, Mathon G, Duclos G, Bouvet L, Michelet P, Allaouchiche B, Chamoître K, Di Bisceglie M, Leone M. Comparative study of lung ultrasound and chest computed tomography scan in the assessment of severity of confirmed COVID-19 pneumonia. *Intensive Care Med* 2020; 46: 1707–1713. DOI: 10.1007/s00134-020-06186-0.
- [7] Deng Q, Zhang Y, Wang H, Chen L, Yang Z, Peng Z, Liu Y, Feng C, Huang X, Jiang N, Wang Y, Guo J, Sun B, Zhou Q. Semiquantitative lung ultrasound scores in the evaluation and follow-up of critically ill patients with COVID-19: a single-center study. *Acad Radiol* 2020; 27: 1363–1372. DOI: 10.1016/j.acra.2020.07.002.
- [8] Lichter Y, Topilsky Y, Taieb P, Banai A, Hochstadt A, Merdler I, Gal Oz A, Vine J, Goren O, Cohen B, Sapir O, Granot Y, Mann T, Friedman S, Angel Y, Adi N, Laufer-Perl M, Ingbir M, Arbel Y, Matot I, Szekely Y. Lung ultrasound predicts clinical course and outcomes in COVID-19 patients. *Intensive Care Med* 2020; 46: 1873–1883. DOI: 10.1007/s00134-020-06212-1.
- [9] Caltabeloti F, Monsel A, Arbelot C, Brisson H, Lu Q, Gu W-J, Zhou G-J, Auler JOC, Roubly J-J. Early fluid loading in acute respiratory distress syndrome with septic shock deteriorates lung aeration without impairing arterial oxygenation: a lung ultrasound observational study. *Crit Care* 2014; 18: R91
- [10] Bouhemad B, Brisson H, Le-Guen M et al. Bedside Ultrasound Assessment of Positive End-Expiratory Pressure-induced Lung Recruitment. *Am J Respir Crit Care Med* 2011; 183: 341–347
- [11] Costamagna A, Pivetta E, Goffi A, Steinberg I, Arina P, Mazzeo AT, Del Sorbo L, Veglia S, Davini O, Brazzi L, Ranieri VM, Fanelli V. Clinical performance of lung ultrasound in predicting ARDS morphology. *Ann Intensive Care* 2021; 11: 51. DOI: 10.1186/s13613-021-00837-1
- [12] Pierrakos C, Smit MR, Pisani L, Paulus F, Schultz MJ, Constantin JM, Chiumello D, Mojoli F, Mongodi S, Bos LDJ. Lung Ultrasound Assessment of Focal and Non-focal Lung Morphology in Patients With Acute Respiratory Distress Syndrome. *Front Physiol* 2021; 12: 730857. DOI: 10.3389/fphys.2021.730857
- [13] Robba C, Ball L, Battagliani D, Iannuzzi F, Brunetti I, Fiaschi P, Zona G, Taccone FS, Messina A, Mongodi S, Pelosi P. Effects of positive end-expiratory pressure on lung ultrasound patterns and their correlation with intracranial pressure in mechanically ventilated brain injured patients. *Crit Care* 2022; 26: 31. DOI: 10.1186/s13054-022-03903-7
- [14] Santangelo E, Mongodi S, Bouhemad B, Mojoli F. The weaning from mechanical ventilation: a comprehensive ultrasound approach. *Curr Opin Crit Care* 2022; 28: 322–330. DOI: 10.1097/MCC.0000000000000941
- [15] Lung Ultrasound Study Group Soummer A, Perbet S, Brisson H, Arbelot C, Constantin J-M, Lu Q, Roubly J-J. Ultrasound assessment of lung aeration loss during a successful weaning trial predicts postextubation distress*. *Crit Care Med* 2012; 40: 2064–2072
- [16] Bouhemad B, Liu Z-H, Arbelot C, Zhang M, Ferarri F, Le-Guen M, Girard M, Lu Q, Roubly J-J. Ultrasound assessment of antibiotic-induced pulmonary reaeration in ventilator-associated pneumonia. *Crit Care Med* 2010; 38: 84–92
- [17] Mongodi S, Pozzi M, Orlando A, Bouhemad B, Stella S, Tavazzi G, Via G, Iotti GA, Mojoli F. Lung ultrasound for daily monitoring of ARDS patients on extracorporeal membrane oxygenation: preliminary experience. *Intensive Care Med* 2018; 44: 123–124
- [18] Lu X, Arbelot C, Schreiber A, Langeron O, Monsel A, Lu Q. Ultrasound Assessment of Lung Aeration in Subjects Supported by Venovenous Extracorporeal Membrane Oxygenation. *Respir Care* 2019; 64: 1478–1487. DOI: 10.4187/respcare.06907.
- [19] Mongodi S, Colombo A, Orlando A, Cavagna L, Bouhemad B, Iotti GA, Mojoli F. Combined ultrasound-CT approach to monitor acute exacerbation of interstitial lung disease. *Ultrasound J* 2020; 12: 27. DOI: 10.1186/s13089-020-00174-7
- [20] Lieveld AWE, Heldeweg MLA, Schouwenburg J, Veldhuis L, Haaksma ME, van Haften RM, Teunissen BP, Smit JM, Twisk J, Heunks L, Nanayakkara PWB, Tuinman PR. Monitoring of pulmonary involvement in critically ill COVID-19 patients – should lung ultrasound be preferred over CT? *Ultrasound J*. 2023; 15: 11. DOI: 10.1186/s13089-022-00299-x.
- [21] COVIDLUS study group Dargent A, Chatelain E, Si-Mohamed S, Simon M, Baudry T, Kreitmann L, Quenot JP, Cour M, Argaud L. Lung ultrasound score as a tool to monitor disease progression and detect ventilator-associated pneumonia during COVID-19-associated ARDS. *Heart Lung* 2021; 50: 700–705. DOI: 10.1016/j.hrtlng.2021.05.003.
- [22] Mongodi S, De Vita N, Salve G, Bonaiti S, Daverio F, Cavagnino M, Siano G, Amatu A, Maggio G, Musella V, Klersy C, Vaschetto R, Bouhemad B, Mojoli F. The Role of Lung Ultrasound Monitoring in Early Detection of Ventilator – Associated Pneumonia in COVID-19 Patients: A Retrospective Observational Study. *J Clin Med* 2022; 11: 3001. DOI: 10.3390/jcm11113001
- [23] Mongodi S, Orlando A, Arisi E, Tavazzi G, Santangelo E, Caneva L, Pozzi M, Pariani E, Bettini G, Maggio G, Perlini S, Presa L, Iotti GA, Mojoli F. Lung Ultrasound in Patients with Acute Respiratory Failure Reduces Conventional Imaging and Health Care Provider Exposure to COVID-19. *Ultrasound Med Biol* 2020; 50: 301–302. DOI: 10.1016/j.ultrasmedbio.2020.04.033
- [24] Mongodi S, Bouhemad B, Orlando A et al. Modified Lung Ultrasound Score for Assessing and Monitoring Pulmonary Aeration. *Ultraschall der Medizin – Eur J Ultrasound* 2017; 38: 530–537
- [25] Brusasco C, Santori G, Bruzzo E, Trò R, Robba C, Tavazzi G, Guarracino F, Forfori F, Boccacci P, Corradi F. Quantitative lung ultrasonography: a putative new algorithm for automatic detection and quantification of B-lines. *Crit Care* 2019; 23: 28
- [26] Heldeweg MLA, Lopez Matta JE, Haaksma ME et al. Lung ultrasound and computed tomography to monitor COVID-19 pneumonia in critically ill patients: a two-center prospective cohort study. *ICMx* 2021; 9: 1. DOI: 10.1186/s40635-020-00367-3
- [27] Gattinoni L, Pesenti A, Avalli L et al. Pressure-volume curve of total respiratory system in acute respiratory failure. Computed tomographic scan study. *Am Rev Respir Dis* 1987; 136: 730–736
- [28] Landis JR, Koch GG. The measurement of observer agreement for categorical data. *Biometrics* 1977; 33: 159–174
- [29] Copetti R, Soldati G, Copetti P. Chest sonography: a useful tool to differentiate acute cardiogenic pulmonary edema from acute respiratory distress syndrome. *Cardiovasc Ultrasound* 2008; 6: 16. DOI: 10.1186/1476-7120-6-16

- [30] International Liaison Committee on Lung Ultrasound (ILC-LUS) for International Consensus Conference on Lung Ultrasound (ICC-LUS) Volpicelli G, Elbarbary M, Blaivas M, Lichtenstein DA, Mathis G, Kirkpatrick AW, Melniker L, Gargani L, Noble VE, Via G, Dean A, Tsung JW, Soldati G, Copetti R, Bouhemad B, Reissig A, Agricola E, Rouby JJ, Arbelot C, Liteplo A, Sargsyan A, Silva F, Hoppmann R, Breikreutz R, Seibel A, Neri L, Storti E, Petrovic T. International evidence-based recommendations for point-of-care lung ultrasound. *Intensive Care Med* 2012; 38: 577–591. DOI: 10.1007/s00134-012-2513-4.
- [31] Gomond-Le Goff C, Vivalda L, Foligno S, Loi B, Yousef N, De Luca D. Effect of Different Probes and Expertise on the Interpretation Reliability of Point-of-Care Lung Ultrasound. *Chest*. 2020; 157: 924–931. DOI: 10.1016/j.chest.2019.11.013.
- [32] Volpicelli G, Fracalini T, Cardinale L, Stranieri G, Senkeev R, Maggiani G, Pacielli A, Basile D. Feasibility of a New Lung Ultrasound Protocol to Determine the Extent of Lung Injury in COVID-19 Pneumonia. *Chest*. 2023; 163: 176–184. DOI: 10.1016/j.chest.2022.07.014.
- [33] ALIFE Study GroupHeldeweg MLA, Lieveld AWE, Mousa A, Pisani L, Tuinman PR. Validation of New Quantitative Lung Ultrasound Protocol and Comparison With Lung Ultrasound Score in Patients With COVID-19. *Chest* 2023; 164: 1512–1515. DOI: 10.1016/j.chest.2023.07.022