



Hyperosmolar hyperglycemic state in children: case report and review of the literature

Introduction

Hyperosmolar hyperglycemic state (HHS) is a rare complication in children and a life-threatening emergency that presents with a significant increase in blood sugar and hyperosmolality with or without low ketosis [1]. In fact, HHS is a rare complication in children with diabetes mellitus (DM) that shows itself with a triad: hyperglycemia (typically >600 mg/dL), hyperosmolality (serum osmolality >330 mOsm/L), and mild metabolic acidosis (pH >7.2).

This condition is not associated with a good prognosis, as reports indicate a mortality rate of 10–50% [2, 3].

As the most common cause of glucose-related metabolic disorders in childhood is diabetic ketoacidosis (DKA) in type 1 diabetes (T1D), HHS is expected to be more common in obese adults with type 2 diabetes (T2D) [4]; however, evidence suggests that the incidence of HHS has recently increased significantly in children. HHS is a challenging diagnosis due to its low frequency compared to

DKA, especially at a young age, and is often confused with DKA [5].

Here, the case of a 9-year-old boy with an initial diagnosis of HHS who was brought to the emergency room with weakness, lethargy, decreased level of consciousness, and a serum glucose level of 1600 is reported. The prevalence and physiopathology of HHS in children was further assessed.

Case presentation

The patient was a previously healthy 9-year-old boy who was brought to the emergency department presenting with weakness, lethargy, and decreased level of consciousness.

At 1 week before admission, the child became increasingly irritable, which was followed by polyuria and polydipsia. At 2 days before admission, the patient had a low-grade fever and frequent postprandial vomiting. He mentioned morning abdominal pain but no diarrhea. No history of glucose overdose or past neurological disease has been reported.

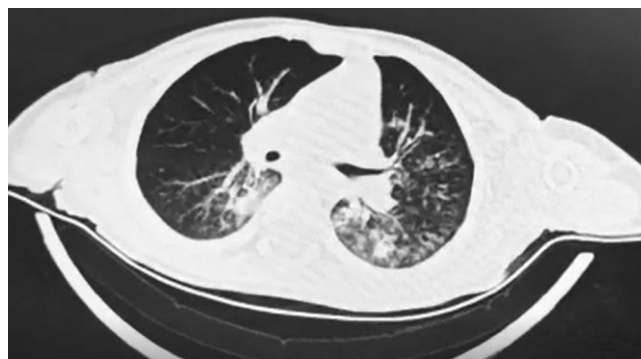


Fig. 1 ◀ Chest imaging of the patient showed bilateral consolidation and ground-glass opacities

At the time of admission to hospital, the child weighed 20 kg. He initially appeared to be ill and confused. He had moderate dehydration. His mucous membranes were dry, and his skin turgor was increased. He had postprandial vomiting eight times in the morning of admission to the hospital. His body temperature was 37.6 °C and oxygen saturation level (O₂SAT) = 91.1%. Other vital signs were stable (blood pressure (BP): 100/60 mm Hg, heart rate (HR): 90 beats/min, respiratory rate (RR): 22 breaths/min). The remaining examinations were generally not significant.

Initial laboratory evaluation revealed: arterial blood gas pH 7.22; partial pressure of carbon dioxide (PCO₂) 28.8 mm Hg; Bicarbonate (HCO₃) 11.5 mM. Complete blood count had a white blood count of 23.6/μL, a hematocrit of 51%, and a platelet count of 340,000/μL. Electrolytes were the following: sodium (Na): 143 mM (corrected Na using the formula: Corrected Na = Measured Na + 1.6 (glucose (mg/dL) – 100) was 167 mM); potassium: 5.3 mM. Serum glucose: 1600 mg/dL; BUN: 30.7 mg/dL; creatinine: 1.8 mg/dL; liver enzyme and coagulation profile were normal; urinalysis had 1+ glucose and urinary acetone.

Based on the above findings, the patient was diagnosed with HHS following type 1 diabetes. Therefore, the patient was admitted to the pediatric intensive care unit, and the necessary medical measures were taken. Upon admission, the patient underwent fluid therapy: half-saline 1500 cc with apotel 200 g, intravenous as needed. This was followed by serum normal saline 400 cc IV and 50 U insulin regular + 500 cc normal saline. Insulin therapy was continued for the patient in the form of 6 units of neutral protamine hagedorn (NPH) insulin and 3 units of regular insulin in the morning and 2 units per night.

Based on the patient's chest computed tomography (CT) scan findings (■ Fig. 1) and suspicion of coronavirus disease 2019 (COVID-19) infection, antibiotic therapy (Amp clindamycin 200 mg QID + Amp ceftriaxone 700 mg BD) was also initiated. However, his

polymerase chain reaction (PCR) test was negative. The patient responded well to invasive fluid resuscitation and gentle insulin administration. Finally, the patient was discharged after 3 days in good general condition without HHS-related complications and was followed up with insulin therapy.

Discussion and conclusion

HHS, characterized by a marked increase in serum glucose concentration and significant hyperosmolality without ketosis, has been historically rare in children. In general, the classic presentation of HHS is in obese children and adolescents with type 2 diabetes. However, cases of HHS in type 1 diabetes and non-obese adolescents have recently been reported [6, 7]. These reports indicate that the prevalence of this disorder is increasing [8]. Therefore, in children, increased awareness of the occurrence of HHS and differences in management strategies between DKA and HHS is needed to improve outcomes in this life-threatening disorder.

These metabolic disorders are caused by synergistic factors such as insulin deficiency and elevated levels of regulatory hormones (glucagon, catecholamines, cortisol, and growth hormone), which have many causes; in children, one of the most common causes of HHS can be infections. Evidence shows that 50–60% of HHS is associated with infectious causes [9]. As Rafique et al. [10] noted in their study, hyperglycemic emergencies such as DKA and HHS are associated with severe COVID-19 infection; thus, diabetic patients suffering from COVID-19 need high doses of insulin to control blood glucose. Chan et al. [11] showed in their study that diabetic patients were at significant risk of developing DKA/HHS combined with COVID-19 and significant mortality. Due to the importance of the COVID-19 pandemic, the patient underwent a PCR test for COVID-19 infection, which was negative.

In fact, severe hyperglycemia is associated with a severe inflammatory condition involving an increase in proinflammatory cytokines (tumor necrosis factor-α, interleukin (IL) β, IL6, and IL8) and reactive oxygen species with insulin

J. Klin. Endokrinol. Stoffw. 2022 · 15: 60–62

<https://doi.org/10.1007/s41969-022-00164-1>

© The Author(s), under exclusive licence to Springer-Verlag GmbH Austria, ein Teil von Springer Nature 2022

I. Shahramian · P. Ostad Rahimi · S. Radvar Hyperosmolar hyperglycemic state in children: case report and review of the literature

Abstract

Hyperosmolar hyperglycemic state (HHS) is a rare complication in children and a life-threatening emergency that presents with a significant increase in blood sugar and hyperosmolality with or without low ketosis. This study reports the case of a 9-year-old boy with severe HHS due to type 1 diabetes. The patient's initial serum glucose level was 1600; however, he was discharged in a stable condition. The patient presented many of the known complications of HHS, including decreased level of consciousness, hypovolemic shock, acute kidney injury, and very high serum glucose levels. The patient responded well to invasive fluid resuscitation and insulin administration, was discharged in good general condition without HHS-related complications, and was followed up with insulin therapy. As the prevalence of HHS in children is increasing, it is necessary for physicians to be aware of the unusual manifestations in children, especially children with type 1 diabetes, and to have the ability to diagnose and manage HHS and differentiate it from diabetic ketoacidosis.

secretion. Hyperglycemia also increases oxidative stress markers such as membrane lipid peroxidation [12]. Evidence also suggests that infections are caused by other causes such as cerebrovascular accidents, medications, peritoneal dialysis, burns and dehydration, certain medications, lack of treatment, undiagnosed diabetes mellitus, and substance abuse [13–15]. Some reports suggest that HHS mortality may be higher in children than in adults. In fact, patients with HHS are vulnerable to a number of serious complications, including cerebral edema, thrombosis, malignant hyperthermia, renal failure, pancreatitis, and severe electrolyte imbalance. Obese children are also at higher risk since accurate estimation of dehydration can be challenging and can lead to dehydration [6, 16]. This

study reported a severe case of HHS following a respiratory infection in a child with good outcomes. This particular patient had many of the known complications of HHS, including decreased level of consciousness, hypovolemic shock, acute kidney injury, and very high serum glucose levels. Finally, the patient responded well to invasive fluid resuscitation and insulin administration, and was discharged in good general condition without HHS-related complications and was followed up with insulin therapy. As the prevalence of HHS in children and adolescents is increasing, it is necessary for physicians to be aware of the unusual manifestations in children, especially children with type 2 diabetes, and to have the ability to diagnose and manage HHS, as well as differentiate it from DKA.

Corresponding address

Sepideh Radvar

Department of Pediatrics, Faculty of Medicine, Zabol University of Medical Sciences Zabol, Iran
30stana@gmail.com

Declarations

Conflict of interest. I. Shahramian, P. Ostad Rahimi, and S. Radvar declare that they have no competing interests.

For this article no studies with human participants or animals were performed by any of the authors. All studies mentioned were in accordance with the ethical standards indicated in each case. Additional written informed consent was obtained from all individual participants or their legal representatives for whom identifying information is included in this article.

References

1. Stoner GD (2017) Hyperosmolar hyperglycemic state. *Am Fam Physician* 96(11):729–736
2. Murthy S, Sharara-Chami R (2010) Aggressive fluid resuscitation in severe pediatric hyperglycemic hyperosmolar syndrome: a case report. *Int J Pediatr Endocrinol*. <https://doi.org/10.1155/2010/379063>
3. Cochran JB, Walters S, Losek JD (2006) Pediatric hyperglycemic hyperosmolar syndrome: diagnostic difficulties and high mortality rate. *Am J Emerg Med* 24(3):297–301
4. Mohn A, Polidori N, Castorani V, Comegna L, Gianini C, Chiarelli F, Blasetti A (2021) Hyperglycaemic hyperosmolar state in an obese prepubertal girl with type 2 diabetes: case report and critical approach to diagnosis and therapy. *Italian J Pediatr* 47(1):1–6
5. D'Ambrosio F, Marranzini-Rodriguez I, Castaneda RA, Boucher-Berry C (2020) Hyperosmolar hyperglycemic state as initial presentation of type 1 diabetes in children. *J Endocr Soc* 4(Supplement_1):MON-84
6. Zeitler P, Haqq A, Rosenbloom A, Glaser N (2011) Hyperglycemic hyperosmolar syndrome in children: pathophysiological considerations and suggested guidelines for treatment. *J Pediatr* 158(1):9–14
7. Rosenbloom AL (2010) Hyperglycemic hyperosmolar state: an emerging pediatric problem. *J Pediatr* 156(2):180–184
8. Hernández Moreno A, Sanz Fernández M, Ballesteros Pomar MD, Rodríguez Sánchez A (2016) Hiperglycémico hiperosmolar state: an unusual way of first appearance of type 1 diabetes in children. *Endocrinol Nutr* 63(5):252–253
9. Adeyinka A, Kondamudi NP (2020) Hyperosmolar hyperglycemic nonketotic coma (HHNC, hyperosmolar hyperglycemic nonketotic syndrome). *StatPearls, Treasure Island*
10. Rafique S, Ahmed FW (2020) A case of combined diabetic ketoacidosis and hyperosmolar hyperglycemic state in a patient with COVID-19. *Cureus* 12(7):e8965
11. Chan KH, Thimmareddygar D, Ramahi A, Atallah L, Baranetsky NG, Slim J (2020) Clinical characteristics and outcome in patients with combined diabetic ketoacidosis and hyperosmolar hyperglycemic state associated with COVID-19: A retrospective, hospital-based observational case series. *Diabetes Res Clin Pract* 166:108279
12. Rains JL, Jain SK (2011) Oxidative stress, insulin signaling, and diabetes. *Free Radic Biol Med* 50(5):567–575
13. Karlioglu French E, Donihi AC, Korytkowski MT (2019) Diabetic ketoacidosis and hyperosmolar hyperglycemic syndrome: review of acute decompensated diabetes in adult patients. *BMJ* 365:l1114
14. Reddy A, Finley L, Horrall S (2019) Hyperosmolar hyperglycemic syndrome in a young boy. *Proc (Bayl Univ Med Cent)* 32:627–628
15. Nakazawa H, Naruse Y, Mori M, Hiramoto R (2021) Hyperosmolar hyperglycemic syndrome induced by diazoxide and furosemide in a 5-year-old girl. *Clin Pediatr Endocrinol* 30(3):139–142
16. Tsai SL, Hadjiyannakis S, Nakhla M (2012) Hyperglycemic hyperosmolar syndrome at the onset of type 2 diabetes mellitus in an adolescent male. *Paediatr Child Health* 17(1):24–26

Publisher's Note. Springer Nature remains neutral with regard to jurisdictional claims in published maps and institutional affiliations.

Hilde Löfqvist: Hormontherapie in den Wechseljahren

Alles zu Fakten und Mythen



Es gibt viele Informationen über Wechseljahre und Hormontherapie, doch kann es oft schwierig sein, Fakten von allgemeinen Meinungen

und Mythen zu unterscheiden. In diesem Buch erfahren Sie, welche Empfehlungen zu Hormonbehandlungen es gibt und was Sie tun können, um Wechseljahresprobleme in den Griff zu bekommen. Die Autorin schreibt in leicht verständlicher Form und verbindet gesicherte wissenschaftliche Erkenntnisse mit ihrer fast 40-jährigen praktischen Berufserfahrung.

- Vermittelt notwendige und wichtige Grundlagen, um Veränderungen in den Wechseljahren zu verstehen
- Stellt Vor- und Nachteile einer Hormontherapie dar
- Mit illustrierenden Fallbeispielen aus der Praxis der Autorin

Autorin

Dr. med. Hilde Löfqvist. Fachärztin für Gynäkologie und Geburtshilfe im Ärztezentrum Cevita Care, Gyn Stockholm, St. Görans Krankenhaus in Stockholm. Verantwortlich für die Entwicklung eines Menopausenzentrums mit dem Schwerpunkt Probleme der Wechseljahre.

<https://doi.org/10.1007/978-3-662-62710-5>
Springer, Berlin, Heidelberg

© Information Hildemarias AB 2021

Softcover ISBN 978-3-662-62709-9

eBook ISBN 978-3-662-62710-5

Schwedische Originalausgabe: „Hormonkarusellen: fakta och myter om klimakteriebehandling“, Bromma, Schweden, 2019