



## Leukemia – Lymphoma and Myeloma

# Ovarian Tissue Reservation and Risk of Reimplantation in a Young Girl with Acute Lymphocytic Leukemia after 6-Month Chemotherapy: A Case Report

Mojgan Karimi-Zarchi<sup>1</sup> Mohammad Ali Khalili<sup>2</sup> Fariba Binesh<sup>3</sup> Mahboubeh Vatanparast<sup>4</sup>

<sup>1</sup>Department of Gynecology Oncology, Iran University of Medical Sciences, Tehran, Iran

<sup>2</sup>Research and Clinical Center for Infertility, Yazd University of Medical Sciences, Yazd, Iran

<sup>3</sup>Department of Pathology, Shahid Sadoughi University of Medical Sciences, Yazd, Iran

<sup>4</sup>Molecular Medicine Research Center, Rafsanjan University of Medical Sciences, Rafsanjan, Iran

**Address for correspondence** Mahboubeh Vatanparast, PhD, Molecular Medicine Research Center, Rafsanjan University of Medical Sciences, Rafsanjan, Iran (e-mail: mahboob\_vatan@yahoo.com).

**South Asian J Cancer 2021;10:112–114.**

## Abstract



Mahboubeh Vatanparast

## Keywords

- ▶ fertility preservation
- ▶ cancer
- ▶ chemotherapy
- ▶ ovarian reservation
- ▶ ALL

In the fertility preservation programs, ovarian cryopreservation is usually offered when the risk of premature ovarian failure is high (>30–50%) while the risk of ovarian metastasis is low. According to the guidelines, it must be done before the patient receives chemotherapy. A 22-year-old girl with acute lymphocytic leukemia was a candidate for ovarian cryopreservation after 6 months of chemotherapy. Despite chemotherapy, the anti-Mullerian hormone survey was within normal range. Ovarian tissue cryopreservation was done. In the histology survey, follicular density was 7.48. This case shows that only having a history of chemotherapy does not exclude the patient from the fertility preservation program. Regarding referring the patients for fertility preservation, cumulative factors such as a history of gonadotoxic treatment, age, and treatment protocol should be considered. In addition, the case was negative for assessing of CD45 marker. New data may challenge previous strict criteria, and extend the indications of this effective method in preserving fertility among cancer patients.

## Introduction

Nowadays, there is a strong interest in the long-term effects of chemo- or radiotherapy on the future fertility of cancer patients.<sup>1,2</sup> Evidence-based clinical practice guidelines are needed to reach high-quality uniform care in the cancer patients and to decrease divisions in practice and costs.<sup>2</sup>

Many guidelines describe the circumstances under which fertility preservation is needed to be discussed and for which patients the ovarian cryopreservation may be appropriate. Nevertheless, there is a significant heterogeneity between different groups in the selection criteria for ovarian cryopreservation, such as age limits or a history of chemotherapy. One of them is a guideline published after

**DOI** <https://doi.org/10.1055/s-0041-1729495> **ISSN** 2278-330X

**How to cite this article:** Mojgan K-Z, Ali M. K, Fariba B, Vatanparast M. Ovarian Tissue Reservation and Risk of Reimplantation in a Young Girl with Acute Lymphocytic Leukemia after 6-Month Chemotherapy: A Case Report. *South Asian J Cancer* 2021;10(2):112–114.

©2021. MedIntel Services Pvt Ltd.

MedIntel Services Pvt Ltd.. This is an open access article published by Thieme under the terms of the Creative Commons Attribution-NonDerivative-NonCommercial-License, permitting copying and reproduction so long as the original work is given appropriate credit. Contents may not be used for commercial purposes, or adapted, remixed, transformed or built upon. (<https://creativecommons.org/licenses/by-nc-nd/4.0/>). Thieme Medical and Scientific Publishers Private Ltd A-12, Second Floor, Sector -2, NOIDA -201301, India

**Table 1** Numbers and density of primordial follicles in each group

	Primordial	Fragments	Total	Volume	Density
Fresh	347	11	2,717	275	7.48
Cryopreserved	188	11	1,738	275	3.76

multidisciplinary discussion in 1996 and slightly revised in 2000 (Edinburgh Criteria).<sup>3</sup> Some guidelines were also published by both the American Society of Clinical Oncology and the American Society of Reproductive Medicine.<sup>4</sup> According to many of them, fertility preservation must be done before chemotherapy.

In this case, a patient referred to our fertility center for ovarian tissue cryopreservation, after 6 months of chemotherapy. Was the patient a good candidate for fertility preservation according to the guidelines? Also because of the potential risk for reintroducing disease after the remission, this case is the most controversial case for ovarian cryopreservation and transplantation. CD45 or leukocyte common antigen is a marker to evaluate the presence of leukemic cells in the cryopreserved ovarian tissue.

## Case History

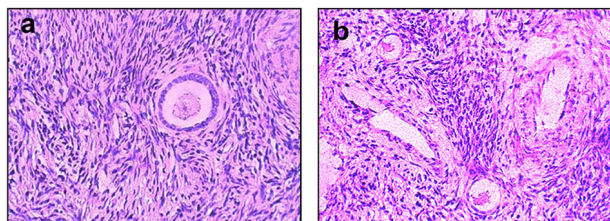
A young girl diagnosed with acute lymphocytic leukemia was referred to our institute for ovarian cryopreservation. The patient had undergone 15 sessions of chemotherapy with 30 mg vincristine and 975 mg adriamycin before referring for fertility preservation. The next plan for her was hematopoietic stem cell transplantation (HSCT). A big question was this: if the patient had enough ovarian reservation after receiving chemotherapy? With the aim of a further survey of the fertility situation, an anti-Mullerian hormone (AMH) survey was also requested, which was within the normal range (3.66 ng/mL). It showed premenopausal ovarian function, which is in accordance with the Backhus' criteria.<sup>4</sup> However, if she was married, we would propose ovarian hyperstimulation followed by follicular puncture and fertilization with the husband's sperm. Because she was single, actually the best approach for the patient was cryopreservation of the gametes. We planned for vitrification of oocytes and ovarian tissue.

After laparoscopic incision, ovarian tissue was transferred to our institute. We aspirated the follicles for oocyte rescue. All detectable antral follicles were aspirated. Eight germinal vesicle oocytes were cultured in in vitro maturation medium (IVM) (sage, IVF) maturation medium (SAGE, IVF) supplemented with 75 mIU/mL follicle-stimulating hormone and 75 mIU/mL luteinizing hormone (Ferring). After 48-hour incubation, one oocyte reached to metaphase II stage and was cryopreserved using RapidVit Cleave (Vitrolife, Goteborg, Sweden), and the ovarian cortex was frozen simultaneously for the posttreatment fertility options. A total of 11 cortical fragments were isolated with a volume of 550 mm<sup>3</sup>. A written informed consent was taken in agreement to donate one ovarian biopsy for histological study. This study was approved

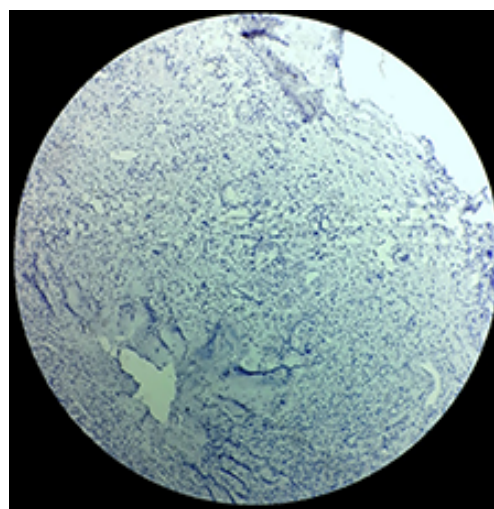
by the Ethics Committee of Research and Clinical Center for Reproductive Medicine (ir.ssu.rsi.rec.1395.22). One piece was taken for the histological evaluation. For this purpose, we divided this fragment into two parts. One was fixed in formalin and the other was frozen. The fresh and warmed tissue was placed in 7% formalin for the next histology (H&E) and immunohistologic (CD45) evaluations. All evaluated sections were negative for presence of malignant cells or CD45 marker. The contamination was assessed in both extra- and intravascular spaces within the tissue.

## Follicular Density

All the primordial follicles were counted in the fresh and thawed fragments. Follicular density was calculated. Follicular density (→ Fig. 1) was 7.48 in the fresh and 3.76 in the thawed ovary (in 250 mm<sup>2</sup>) (→ Table 1). After warming immunostaining was done also for detecting CD45. All evaluated sections were negative for presence of malignant cells or CD45 marker (→ Fig. 2).



**Fig. 1** Primordial and primary follicles. (a) Fresh primary follicle. Original magnification ×40. (b) Cryopreserved primordial follicles. Original magnification ×20.



**Fig. 2** CD45 negative. Original magnification ×20.

## Discussion

This study showed that a patient who had received chemotherapy, still, had enough ovarian reservation for fertility preservation. Therefore, a history of chemotherapy alone is not a sufficient reason for being a contraindication of ovarian cryopreservation. Another study also reported that a history of cancer is not a strong reason for the patient's sterility.<sup>5</sup> Hormone and histology survey confirmed that this case had enough ovarian reservation for fertility preservation. However, we used only a single small biopsy of the ovarian cortex and it may not be a good indicator of the ovarian total numbers of follicles; it can provide us with some diagnostic value. Previous reports that addressed the issue of ovarian cryopreservation did not pay attention to the AMH level as a criterion for reassurance of premenopausal ovarian function.<sup>6,7</sup>

To the best of our knowledge, there is not an ideal option for fertility preservation in postpubertal females with leukemia. However, cryopreservation of ovarian tissue should be considered before HSCT.<sup>8</sup> In histology survey it wasn't positive for both presence of malignant cells, or for CD45. This result is true only for the sections that were observed by our pathologist colleague. This finding is in accordance with the result that evaluated two cases of leukemia after transplantation and reported none of them experienced cancer re-introduction in mean 3.18 years follow up. They also believed that chemotherapy before ovarian cryopreservation is useful in clearance of the peripheral blood and reduction of the risk of possible presence of cancer cells in the graft. This is highly applicable in leukemic patients who their ovaries must be harvested before high-dose chemotherapy that is needed for bone marrow transplantation (REF 9). It must be mentioned that with use of very sensitive RT-qPCR techniques, low levels of contamination by malignant cells is possible to identify in thawed ovarian cortical samples, even from patients in complete remission. It is of great importance that physicians evaluate practice guidelines, in order to offer an appropriate fertility preservation options according to patients clinical status, accurate evaluation of risk-benefit ratio, and patient's values. Unless, it is demonstrated that ovarian failure is in place, it hypothesizes that adequate ovarian reservation exists for fertility cryopreservation, irrespective of age or previous treatment regimens.<sup>4</sup>

In the present study, we used only a single small biopsy of ovarian cortex. However, one piece of the ovarian tissue may not be a good indicator of the ovarian total number of follicles, it can provide us with some diagnostic value. Based on Oncofertility Consortium Consensus Statement, even the patient may not become infertile, but a shift in her reproductive lifespan which may end by reaching early 30s instead of 40s could change her range of choices and quality of life. Thus, ovarian tissue cryopreservation indications may be a wider spectrum than the patients with high risk of immediate infertility.

In conclusion, this case shows that only having a history of chemotherapy does not exclude the patient from a fertility preservation program. Regarding referring the patients to the fertility preservation program, a cumulative of factors such as age, diagnosis of disease, and treatment protocol should be considered, as well as a history of gonadotoxic treatment.

### Note

This study was approved by the Research Ethics Committee of the Yazd Reproductive Sciences Institute, which follows the Helsinki Declaration of 1975.

### Author Contribution

Mojgan Karimi-Zarchi: concepts, definition of intellectual content, literature search.

Mohammad Ali Khalili: manuscript review, experimental studies.

Fariba Bineh: Clinical studies: manuscript editing.

Mahboubeh Vatanparast: data acquisition, manuscript preparation.

### Conflict of Interest

None.

## References

- 1 Revel A, Revel-Vilk S. Fertility preservation in young cancer patients. *J Hum Reprod Sci* 2010;3(1):2-7
- 2 Font-Gonzalez A, Mulder RL, Loeffen EAH, et al. PanCareLIFE Consortium. Fertility preservation in children, adolescents, and young adults with cancer: quality of clinical practice guidelines and variations in recommendations. *Cancer* 2016;122(14):2216-2223
- 3 Wallace WHB, Anderson RA, Irvine DS. Fertility preservation for young patients with cancer: who is at risk and what can be offered? *Lancet Oncol* 2005;6(4):209-218
- 4 Backhus LE, Kondapalli LA, Chang RJ, Coutifaris Ch, Kazer R, Woodruff TK. Oncofertility consortium consensus statement: guidelines for ovarian tissue cryopreservation. *Cancer Treat Res* 2007. 138:235-239
- 5 Gracia CR. Reproductive health after cancer. *Cancer Treat Res* 2010. 156:3-9
- 6 Wallace WHB, Smith AG, Kelsey TW, Edgar AE, Anderson RA. Fertility preservation for girls and young women with cancer: population-based validation of criteria for ovarian tissue cryopreservation. *Lancet Oncol* 2014;15(10):1129-1136
- 7 von Wolff M, Montag M, Dittrich R, Denschlag D, Nawroth F, Lawrenz B. Fertility preservation in women—a practical guide to preservation techniques and therapeutic strategies in breast cancer, Hodgkin's lymphoma and borderline ovarian tumours by the fertility preservation network FertiPROTEKT. *Arch Gynecol Obstet* 2011;284(2):427-435
- 8 Mahajan N. Fertility preservation in female cancer patients: an overview. *J Hum Reprod Sci* 2015;8(1):3-13
- 9 Meirou D, Ra'anani H, Shapira M, Brenghausen M, Chaim SD, Aviel-Ronen S, et al. Transplantations of frozen-thawed ovarian tissue demonstrate high reproductive performance and the need to revise restrictive criteria. *Fertility and sterility*. 2016;106(2):467-474.