

Lessons learned from poisoning cases caused by 2 illegal rodenticides

Tetramine and fluoroacetamide

Rongshuai Wang, MD^a, Luo Zhuo, MD^b, Yunyun Wang, MD^a, Liang Ren, MD^a, Qian Liu, MD^a, Liang Liu, MD^{a,*}

Abstract

Background: Tetramine (tetramethylene disulphotetramine, TETS) and fluoroacetamide (FAA) are known as illegal rodenticides with high toxicity to animal species and human beings, which could lead to severe clinical features, including reduction of consciousness, convulsions, coma, and even death.

Methods and Results: We presented 2 cases that involved rodenticides poisoning. Even though the patients showed severe manifestations, they were initially misdiagnosed, resulting in 2 persons finally died from TETS and FAA poisoning in homicide cases.

Conclusion: From the clinical and forensic experience of these 2 cases, we suggest that physicians should consider TETS and FAA poisoning when patients present generalized seizures, especially in some cases without clear cause and diagnosis of disease. Early diagnosis and treatment are essential for positive management and criminal investigation in intentional poisoning cases. Moreover, clinical toxicology education should be reinforced.

Abbreviations: CSF = cerebrospinal fluid, CT = computer tomography, ECG = electrocardiograph, EEG = electroencephalogram, FAA = fluoroacetamide, TETS = tetramine or tetramethylenedisulphotetramine.

Keywords: clinical toxicology, fluoroacetamide, seizures, tetramine

1. Introduction

Tetramine (tetramethylene disulphotetramine, TETS) and fluoroacetamide (FAA) have been banned worldwide due to their high toxicity to animal species and human beings. However, they remain available and responsible for intentional or unintentional poisoning cases in China and other countries. It is reported that there were about 3500 persons, including 225 fatalities, involving TETS poisoning in mainland China from 2001 to 2012.^[1] In northeast and central China, TETS and FAA were commonly found in the rodenticide-related poisoning cases.^[2,3]

Both of them have an extremely low lethal dose. However, 7.0 to 10.0 mg TETS is considered lethal for human beings and approximate lethal oral dose of FAA is 30 mg.^[4] The most

common route of exposure to TETS and FAA is ingestion, though occupational exposures through inhalation and skin contact occur occasionally.

At present, TETS or FAA poisoning patients are rare in clinic. The physicians may initially miss the diagnosis of intoxication due to lack of both information of the toxicant intake and clinical/medical toxicology education (especially in China).^[5] Here we presented 2 cases in which patients displayed typical manifestations of TETS and FAA poisoning but finally died due to misdiagnosis.

2. Ethical statement

Ethical approval was not necessary because the study was focused on the retrospective observations of patient's hospital courses and criminal investigation files from police, which in no way affected their treatment. Informed consent was obtained from the patient's relative (in case 1) and the patient (in case 2) for publication of their data and materials.

3. Case report

3.1. Case 1

A 52-year-old, previously healthy male who suffered from sudden convulsion for 3 hours was admitted in intensive care unit (ICU). The patient was suddenly unconscious around 8:30 am after breakfast. He was found foaming, limb stiffness, and urinary incontinence. The seizure lasted 5 to 7 minutes each episodes along with the interval of 20 to 30 minutes. Physical examination: the patient was in a coma, T:37.0°C, HR: 98 bpm, BP: 123/87 mm Hg. Neurological examination: Babinski sign (+) on his right foot. Computer tomography (CT) scan and electroencephalogram (EEG) were unremarkable and electrocardiograph (ECG) showed sinus tachycardia. Serology assay on the day of admission revealed

Editor: Sanket Patel.

Funding: This work was supported by the National Natural Science Foundation of China (Grant No. 81373243).

The authors have no conflicts of interest to disclose.

^a Department of Forensic Medicine, Tongji Medical College, Huazhong University of Science and Technology, Wuhan, ^b Institute of Forensic Science, Fujian Provincial Department of Public Security, Fuzhou, China.

* Correspondence: Liang Liu, Department of Forensic Medicine, Tongji Medical College, Huazhong University of Science and Technology, Wuhan, China (e-mail: liuliang@mails.tjmu.edu.cn).

Copyright © 2016 the Author(s). Published by Wolters Kluwer Health, Inc. All rights reserved.

This is an open access article distributed under the terms of the Creative Commons Attribution-Non Commercial License 4.0 (CCBY-NC), where it is permissible to download, share, remix, transform, and build up the work provided it is properly cited. The work cannot be used commercially without permission from the journal.

Medicine (2016) 95:41(e5103)

Received: 4 March 2016 / Received in final form: 2 September 2016 / Accepted: 18 September 2016

<http://dx.doi.org/10.1097/MD.0000000000005103>

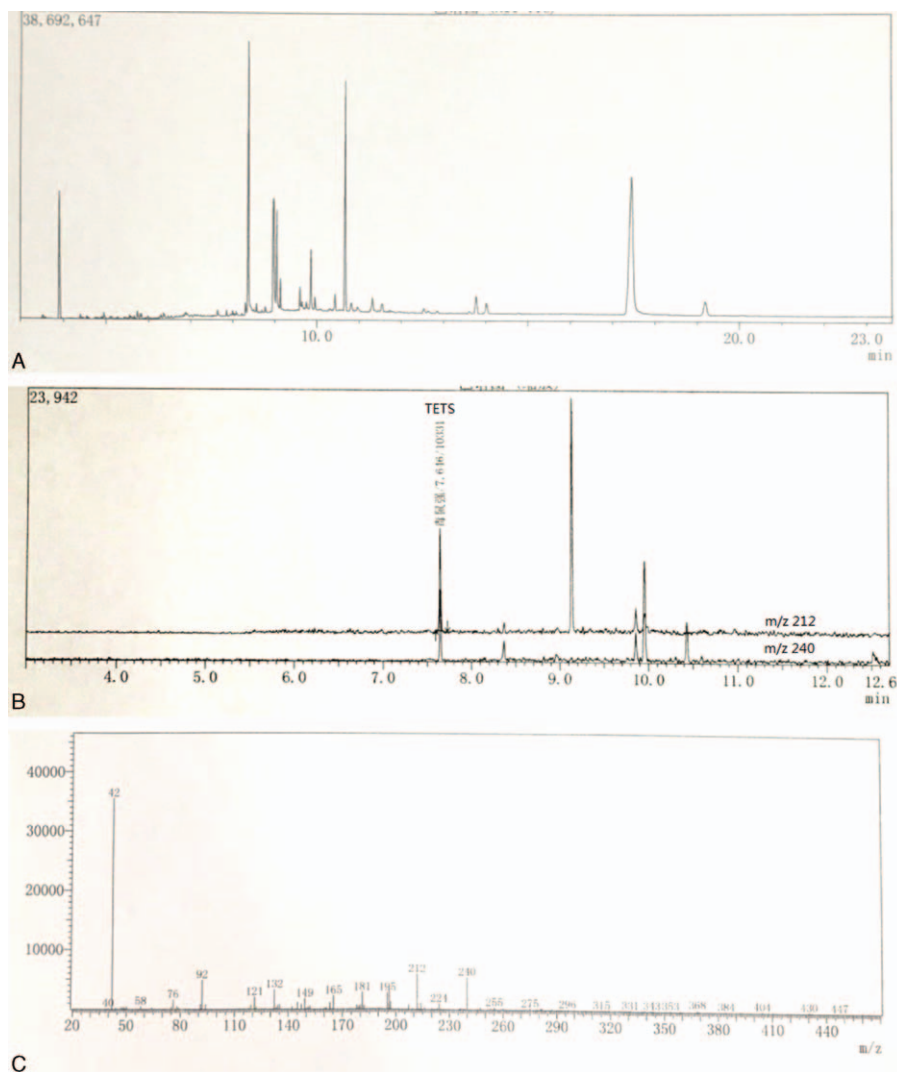


Figure 1. GC-MS chromatograms of the blood sample in case 1. (A) Gas chromatographic analysis of TETS detected in the blood sample; (B) scan at m/z 212/240 in the blood sample; (C) full scan mass spectra of TETS in the blood sample. GC-MS = gas chromatography-mass spectrography, TETS = tetramine or tetramethylenedisulphotetramine.

ALT:64IU/L, AST:39IU/L, CK: 230U/L, LDH: 55U/L, HBDH: 321U/L, CK-MB: 44U/L, cTnT ~0.1 µg/L. The cerebrospinal fluid (CSF) routine test and culture were assessed as negative. Supportive treatments were done and the patient was discharged with a better health condition without a definite diagnosis.

One month later, the patient died suddenly and unexpectedly. The cause of death was determined as TETS poisoning through the toxicological test. According to the police investigation, the suspect poisoned the victim with TETS a month ago. Therefore, the patient's blood samples during his hospitalization were sent for the toxicological test immediately, and the results showed 0.42 µg/mL and 0.35 µg/mL by gas chromatography-mass spectrography (GC-MS), demonstrating TETS poisoning (see Fig. 1).

3.2. Case 2

A 48-year-old man was witnessed generalized convulsions and aphasia and brought to emergency room. His past medical history was unremarkable and free of injuries. Physical examination: The patient was in a coma, T: 36.7°C, HR 86

bpm, BP 164/100 mmHg, and his myodynamia decreased. Dysphagia and dysphonia observed. The patient's brain CT showed hypoxic-ischemic changes lightly at hippocampal regions and cerebral cortex. The results of blood routine test, plasmic electrolytes, chest CT scan, and ECG were unremarkable. The biochemical test showed CK 413.0U/L, ALT 58U/L, AST 47U/L, and hematuria observed, indicating myocardial injuries and dysfunction of liver and renal. The CSF routine test and culture were assessed as negative. Through responsive treatment, the patient's clinical symptoms disappeared 8 days later without a clear diagnosis.

The patient presented similar symptoms twice in next 4 months. The etiology was not clear until his wife was arrested for poisoning her child to death 6 months later. The suspect confessed that she intended to poison her husband and put FAA in the daily dishes for several times in last few months. However, her husband recovered after treatment every time. The blood sample taken from the patient was sent for GC-MS analysis, and the result shown FAA poisoning with positive of FCH₂COO⁻ derivative (1.13 µg/mL) (see Fig. 2).

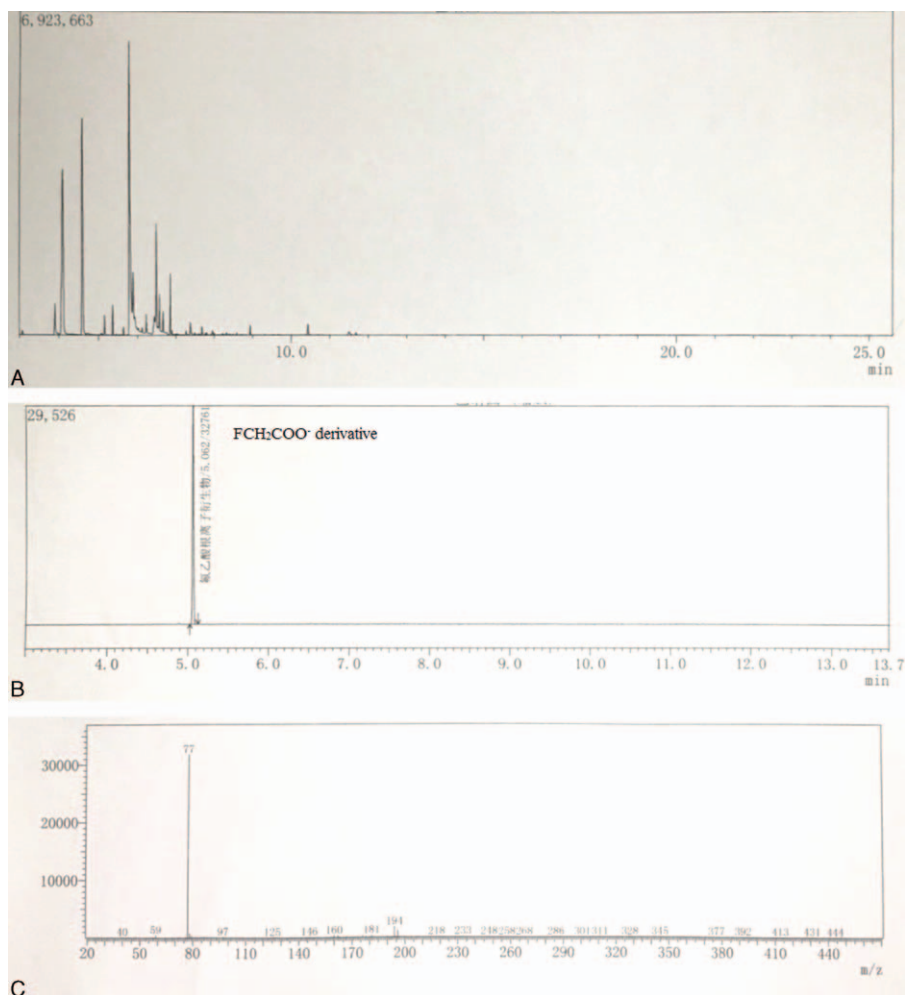


Figure 2. GC-MS chromatograms of the blood sample in case 2. (A) Gas chromatographic analysis of FCH_2COO^- derivative detected in the blood sample; (B) scan at m/z 77 in the blood sample; (C) full scan mass spectra of FCH_2COO^- derivative in the blood sample. GC-MS = gas chromatography-mass spectrography.

4. Discussion

TETS, first synthesized in 1949, is a neural toxin and a noncompetitive blocker of the GABA type A receptor ($GABA_A R$) irreversibly on neuronal cell membranes and blocking chloride channels (see Fig. 3). This leads to excitation of the central

nervous system and induces convulsions.^[6] FAA has a lower toxicity than TETS and could induce convulsion, too. FAA's extreme toxicity stems from blocking the tricarboxylic acid cycle (the Krebs cycle) by combining with coenzyme A (CoA) to form fluoroacetyl CoA, resulting in an accumulation of citrate and

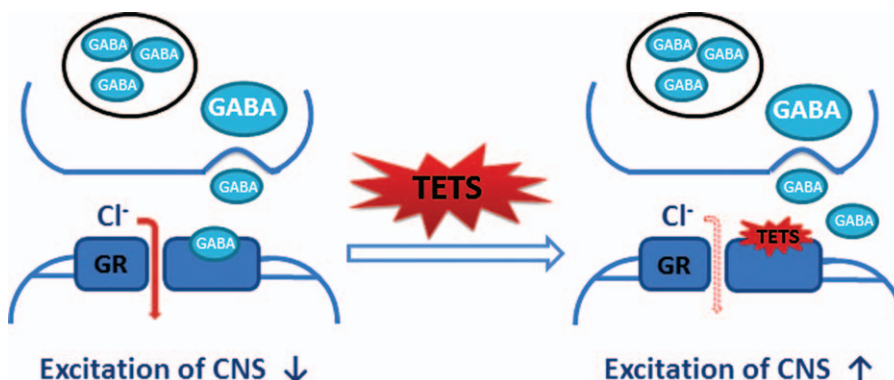


Figure 3. Toxicological mechanism of TETS on CNS (GABA: γ -aminobutyric acid; GR: GABA receptor). TETS = tetramine or tetramethylenedisulphotetramine.

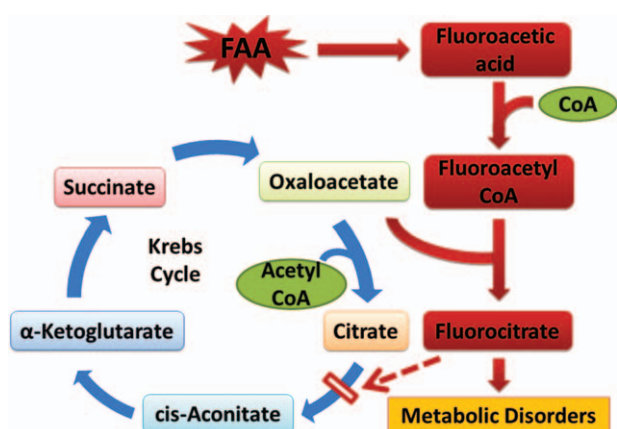


Figure 4. Lethal synthesis in the toxicological effect of FAA. FAA = fluoroacetamide.

cellular metabolic disorder (see Fig. 4).^[7] The onset of TETS and FAA poisoning symptoms occurs immediately or within a few hours after exposure and develop rapidly.^[8,9] Although mild to moderate poisoning may induce symptoms such as headache, dizziness, nausea, vomiting, and agitation, in severe cases, patients suffer generalized clonic-tonic convulsions that may lead to refractory status epilepticus followed by coma, multiorgan failure, and death.^[9] Laboratory tests show that CK, LDH, ALT, AST, creatinine values persistently elevated, and hematuria observed, indicating heart injuries, liver, and renal dysfunction occurs, with or without ECG/EEG atypical changes.^[6,8,10–12] In some FAA poisoning cases, patients developed dysphonia, dysphagia, and myasthenia, which may be a consequence of central nerve system damage.^[13]

It is difficult to distinguish TETS and FAA poisoning from epilepsy, cerebrovascular accident, myocardial infarction, or other toxicant poisoning because of their similar clinical features. Unknown history of toxicant intake and lack of experience of dealing with poisoning cases usually prevent the physician from making correct diagnosis.

To confirm the cause of intoxication, toxicological analysis should be performed using specimens such as vomitus, blood, urine, then detoxification treatment need to be done. Usually, gastric lavage and activated charcoal treatment were performed to eliminate TETS and FAA, oral administration or intravenous drip of anticonvulsants such as diazepam alone or combined with sodium valproate to control convulsion. Hemoperfusion and

hemofiltration can reduce mortality and morbidity.^[6,10,12,14] For FAA poisoning, correction of hypocalcaemia was necessary by calcium supplementation, and ethanol, acetate, sodium succinate and sodium 2-ketoglutarate can be used to reduce FAA toxicity.^[7,14] Other supportive treatments, including preventing organs function failure, maintenance treatment of fluid and electrolyte balance, should be performed in TETS and FAA poisoning.

In conclusion, from the clinical and forensic experience of these 2 cases, we suggest that physicians should consider TETS and FAA poisoning when they meet patients with generalized seizures, especially in some cases without clear cause and diagnosis of disease. Early diagnosis and treatment are essential for positive management and very important to criminal investigation. Moreover, clinical toxicology education should be reinforced.

References

- [1] Li Y, Gao YX, Yu XZ, et al. Tetramine poisoning in China: changes over a decade viewed through the media's eye. *BMC Public Health* 2014;14:842.
- [2] Zhang DL, Zhang JL, Zuo Z, et al. A retrospective analysis of data from toxic substance-related cases in Northeast China (Heilongjiang) between 2000 and 2010. *Forensic Sci Int* 2013;231:172–7.
- [3] Zhou L, Liu L, Chang L, et al. Poisoning deaths in Central China (Hubei): A 10-year retrospective study of forensic autopsy cases. *J Forensic Sci* 2011;56:S234–7.
- [4] Xu XM, Song GL, Zhu Y, et al. Simultaneous determination of two acute poisoning rodenticides tetramine and fluoroacetamide with a coupled column in poisoning cases. *J Chromatogr B Analyt Technol Biomed Life Sci* 2008;876:103–8.
- [5] Li Y, Sun CY, Qiu ZW, et al. Clinical toxicology in China: current situation and future development. *Clin Toxicol (Phila)* 2009;47:263–9.
- [6] Poon WT, Chan K, Lo MH, et al. A case of tetramine poisoning: a lethal rodenticide. *Hong Kong Med J* 2005;11:507–9.
- [7] Proudfoot AT, Bradberry SM, Vale JA. Sodium fluoroacetate poisoning. *Toxicol Rev* 2006;25:213–9.
- [8] Zhang Y, Su M, Tian DP. Tetramine poisoning: A case report and review of the literature. *Forensic Sci Int* 2011;204:e24–7.
- [9] Zolkowska D. Characterization of rodent model of tetramethylenedisulfotetramine (TETS)-induced seizures and potential treatment options. *Pharmacol Rep* 2013;65:258–60.
- [10] Deng XJ, Li G, Mei RW, et al. Long term effects of tetramine poisoning: an observational study. *Clin Toxicol (Phila)* 2012;50:172–5.
- [11] MA, Tian JB, Yang WN, et ST, al. [Change of serum cardiac enzymes of patients with tetramine poisoning]. *Chinese Journal of Emergency Medicine* 2006;15:348–50.
- [12] Chau CM, Leung AK, Tan IK. Tetramine poisoning. *Hong Kong Med J* 2005;11:511–4.
- [13] Gao W. [10 cases of dysphonia in acute fluoroacetamide poisoning]. *Chinese Journal of Industrial Medicine* 2008;21:13.
- [14] Hu CA. [Analysis of 57 cases of children with acute fluoroacetamide poisoning]. *Chinese Community Doctors* 2015;15:61–7.