



## Case report

# Anomalous duplication of the portal vein with prepancreatic postduodenal portal vein

Sho Kitagawa<sup>1</sup>

<sup>1</sup>Department of Gastroenterology, Sapporo Kosei General Hospital, Japan

### Abstract

**Objective:** We report a case of unusual anomalous duplication of the portal vein.

**Patient:** A 40-year-old man with portal vein duplication. One portal vein is derived from the superior mesenteric vein and splenic vein and enters the caudate lobe of the liver. Another portal vein, known as the prepancreatic postduodenal portal vein, is derived from the superior mesenteric vein and courses anterior to the pancreas and posterior to the duodenum.

**Conclusion:** Duplication of the portal vein is an extremely rare developmental anomaly, and in previous reports, the superior mesenteric and splenic veins entered the liver separately. We present a previously unreported case of anomalous duplication of the portal vein, one of which was the prepancreatic postduodenal portal vein.

**Key words:** duplication of the portal vein, prepancreatic postduodenal portal vein, portal vein, anatomic variant

(J Rural Med 2022; 17(4): 259–261)

## Introduction

The prepancreatic postduodenal portal vein is an extremely rare developmental anomaly in which the portal vein courses between the duodenum and pancreas instead of being posterior to both the duodenum and pancreas<sup>1, 2)</sup>. Duplication of the portal vein is also an extremely rare developmental anomaly, and in previous reports, the superior mesenteric and splenic veins entered the liver separately<sup>3–5)</sup>. Here, we present a previously unreported case of anomalous duplication of the portal vein, one of which courses between the duodenum and pancreas, namely, the prepancreatic postduodenal portal vein.

## Case Report

A 40-year-old man presented for the evaluation of a peri-

hepatic mass-like structure found on ultrasonography. On contrast-enhanced computed tomography, the perihepatic mass-like structure was revealed to be an enlarged caudate lobe of the liver. Furthermore, duplication of the portal vein was found incidentally (Figure 1A). One portal vein is derived from the superior mesenteric and splenic veins (PV1; Figure 2A). PV1 enters the enlarged caudate lobe and supplied branches to segments IV, V, VI, VII, and VIII of the liver. Another portal vein, known as the prepancreatic postduodenal portal vein, is derived from the superior mesenteric vein and courses anterior to the pancreas and posterior to the duodenum, which is known as the prepancreatic postduodenal portal vein (PV2; Figures 1B and 2B). PV2 enters segment II of the liver, and except for this anomalous confluence, everything is nearly normal in the liver.

## Discussion

The portal venous system evolves through complex processes, including selective persistence of the vitelline venous system and its anastomoses. Around the rotation of the duodenum, two vitelline veins (right and left) communicate via three anastomoses (cranial ventral, middle dorsal, and caudal ventral), and the middle dorsal anastomosis becomes the main portal vein as a result of regression of the cranial part of the left vitelline vein, caudal part of the right vitelline vein, and caudal ventral anastomosis<sup>6, 7)</sup>. In the normal development of the portal vein and pancreas, the portal vein

Received: March 8, 2022

Accepted: June 6, 2022

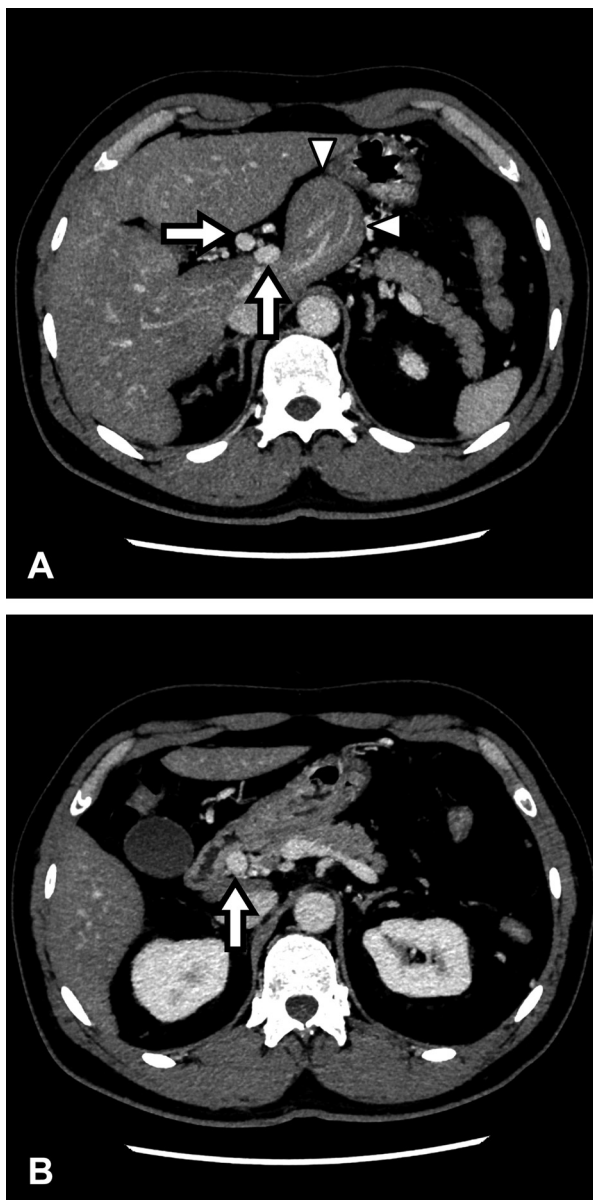
Correspondence: Sho Kitagawa, Department of Gastroenterology, Sapporo Kosei General Hospital, Kita 3 Higashi 8, Chuo-ku, Sapporo 060-0033, Japan

E-mail: bossa0405@yahoo.co.jp

This is an open-access article distributed under the terms of the Creative Commons Attribution Non-Commercial No Derivatives

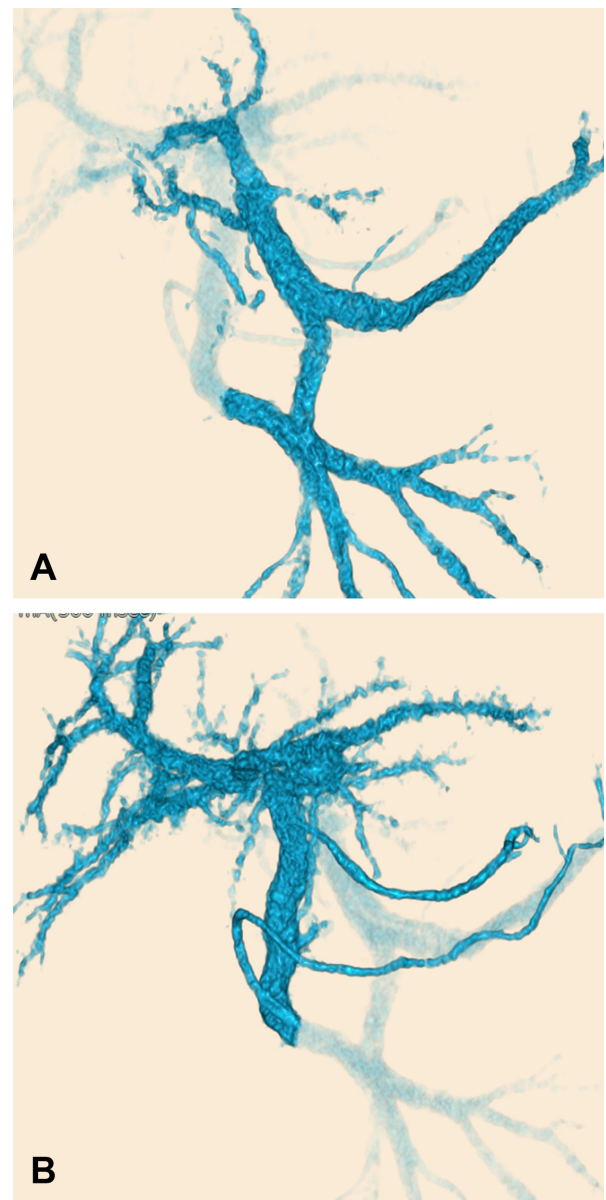
(by-nc-nd) License <<http://creativecommons.org/licenses/by-nc-nd/4.0/>>.





**Figure 1** Contrast-enhanced computed tomography showing an enlarged caudate lobe of the liver (A, arrowheads), duplication of the portal vein (A, arrows), and prepancreatic postduodenal portal vein (B, arrow).

lies posterior to the pancreas because the dorsal pancreatic bud lies cephalad and ventral to the middle dorsal anastomosis. In contrast, in case of the prepancreatic postduodenal portal vein, the portal vein lies anterior to the pancreas and posterior to the duodenum because the dorsal bud of the pancreas lies caudal to the middle dorsal anastomosis and dorsal to the caudal part of the left vitelline vein<sup>2)</sup>. Our case could be explained by the assumption that the cranial part of the left vitelline vein did not regress. Furthermore, the dorsal bud of the pancreas lay cephalad to the middle dorsal anastomosis and dorsal to the caudal part of the left



**Figure 2** Coronal volume-rendered images showing that one portal vein is formed from the superior mesenteric vein and splenic vein (A) and that another portal vein (prepancreatic postduodenal portal vein) derives from the superior mesenteric vein (B).

vitelline vein.

**Author contributions:** S. Kitagawa wrote the manuscript and is the article guarantor.

**Funding:** None to report.

**Statement of ethics:** Patient consent was obtained for the publication of this report, including images.

## References

1. Brook W, Gardner M. Anterposition of the portal vein and spontaneous passage of gall-stones. Case report and embryological hypothesis. *Br J Surg* 1972; 59: 737–739. [[Medline](#)] [[CrossRef](#)]
2. Goussous N, Cunningham SC. Prepancreatic postduodenal portal vein: a case report and review of the literature. *J Med Case Reports* 2017; 11: 2. [[Medline](#)] [[CrossRef](#)]
3. Dighe M, Vaidya S. Case report. Duplication of the portal vein: a rare congenital anomaly. *Br J Radiol* 2009; 82: e32–e34. [[Medline](#)] [[CrossRef](#)]
4. Ito K, Matsunaga N, Mitchell DG, *et al.* Imaging of congenital abnormalities of the portal venous system. *AJR Am J Roentgenol* 1997; 168: 233–237. [[Medline](#)] [[CrossRef](#)]
5. Ozbülbul NI. Congenital and acquired abnormalities of the portal venous system: multidetector CT appearances. *Diagn Interv Radiol* 2011; 17: 135–142. [[Medline](#)]
6. Marks C. Developmental basis of the portal venous system. *Am J Surg* 1969; 117: 671–681. [[Medline](#)] [[CrossRef](#)]
7. Lee WK, Chang SD, Duddalwar VA, *et al.* Imaging assessment of congenital and acquired abnormalities of the portal venous system. *Radiographics* 2011; 31: 905–926. [[Medline](#)] [[CrossRef](#)]