

[ CASE REPORT ]

## Meningoencephalitis Caused by a *Campylobacter fetus* in a Patient with Chronic Alcoholism

Sho Tanabe, Satoshi Kutsuna, Motoyuki Tsuboi, Nozomi Takeshita,  
Kayoko Hayakawa and Norio Ohmagari

### Abstract:

We herein report a case of *Campylobacter fetus* meningoencephalitis in a patient with chronic alcoholism. *C. fetus* is a rare cause of meningitis. The patient presented with hallucinations and monology, and alcohol withdrawal was initially suspected. After he was unsuccessfully treated for alcohol withdrawal delirium, we diagnosed *C. fetus* meningoencephalitis. Ampicillin monotherapy gradually improved his clinical status. A previous report stated that *C. fetus* infection is associated with chronic alcoholism. In patients with chronic alcoholism and disturbed consciousness, an atypical bacterial central nervous system infection, such as *C. fetus* meningoencephalitis, should be considered.

**Key words:** *Campylobacter fetus*, meningoencephalitis, chronic alcoholism, ampicillin

(Intern Med 58: 2247-2250, 2019)

(DOI: 10.2169/internalmedicine.1486-18)

### Introduction

Meningoencephalitis can cause disturbed consciousness, and rapid identification with prompt appropriate therapy is important for achieving optimal outcomes. However, this disease may be misdiagnosed because disturbed consciousness makes it difficult to obtain enough information from the patient. We herein report a case of *Campylobacter fetus* meningoencephalitis that was treated as alcohol withdrawal because of the patient's history of habitual drinking.

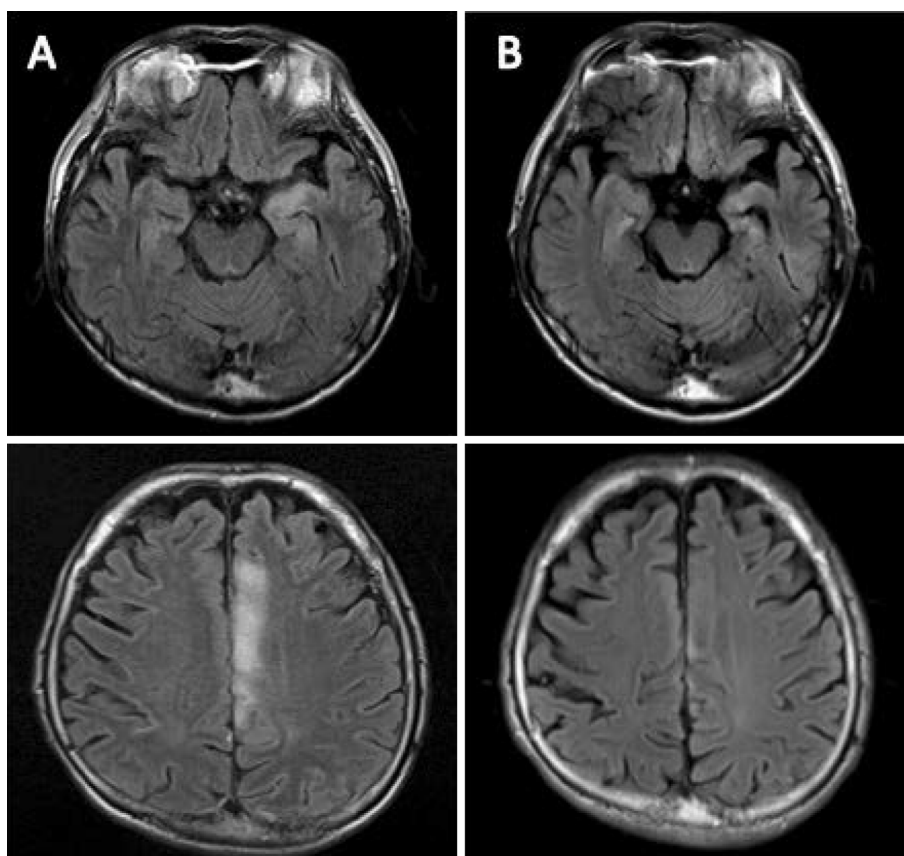
### Case Report

A 56-year-old man with a history of chronic alcoholism experienced disturbed consciousness over several days and was subsequently brought to the Psychiatry Department at our hospital from a nearby mental hospital. A psychiatric evaluation revealed that the patient presented with hallucinations and monology. Based on the patient's history of chronic alcoholism, he was treated for alcohol-withdrawal-associated delirium. Upon admission, he also exhibited a fever and decubitus, which was treated with cefazolin (1 g every 8 hours) for presumed infection.

On day 6 of admission, positive results for *C. fetus* were obtained from his blood culture. Psychiatrists contacted our Department of Infectious Diseases and we initiated a careful evaluation of the patient. When we contacted the patient, he still had hallucination and monology. He did not complain of headache or nausea and did not have a history of eating raw meat before admission. A physical examination revealed normal findings of his respiratory system, cardiovascular system, and abdomen. Although he did not have a headache, we detected mild neck rigidity, possibly indicating meningitis. Laboratory tests also revealed a slightly elevated white blood cell count (9,910/ $\mu$ L) and C-reactive protein level (0.9 mg/dL).

A lumbar puncture was performed, and the patient's cerebrospinal fluid (CSF) was clear and colorless. The initial pressure was 100 mmH<sub>2</sub>O. The CSF cell count was 142/ $\mu$ L (neutrophils: 56/ $\mu$ L, lymphocytes: 86/ $\mu$ L), glucose level was 58 mg/dL (plasma glucose level 99 mg/dL, CSF to serum glucose ratio 0.57), and protein level was 94 mg/dL; no micro-organisms were observed on Gram staining of CSF.

Contrast-enhanced magnetic resonance imaging (MRI) revealed multiple areas of inflammation in the cortex, meninx, and dura mater, which indicated meningoencephalitis. Considering the results of the blood culture and contrast-



**Figure.** Contrast-enhanced magnetic resonance image of the patient's brain. (A) Fluid-attenuated inversion recovery images from before treatment revealed acute brain inflammation. (B) Images obtained at the three-week follow-up after discharge revealed improvement in the inflammation.

enhanced MRI, we started ampicillin (3 g every 6 hours) for suspected *C. fetus* meningoencephalitis. On day 16, we identified growth of *C. fetus* in the culture of a CSF specimen, and it took 10 days to receive the results of the culture after we obtained CSF. Our lab measured the minimum inhibitory concentration (MIC) by the E test for ampicillin (4 µg/mL). The patient's condition gradually improved after initiating the ampicillin treatment, and we also detected improvements in his disturbed consciousness. After four weeks of intravenous ampicillin treatment, we observed that the patient had fully recovered his disturbed consciousness, and he was discharged. At three weeks post-discharge, MRI confirmed that his brain inflammation had improved (Figure).

## Discussion

In the present case, the patient did not complain of typical meningitis symptoms, such as headache or nausea. Previous reports have shown that few *C. fetus* meningoencephalitis cases present with a classic meningitis triad (1).

MRI was helpful in the diagnosis of *C. fetus* meningoencephalitis. The MRI finding implied central nervous system infection or limbic encephalitis and we could rule out other neurological diseases such as Wernicke's encephalopathy.

Although *C. fetus* infections are most frequently observed among patients with immunocompromised status, such as

those with diabetes, malignancy, corticosteroid therapy, or hepatic failure (2), we speculate that chronic alcoholism was strongly related to this case. In 1998, Dronda et al. reviewed the literature regarding *C. fetus* meningitis and reported that 4 of 8 cases (50%) involved chronic alcoholism (3). In addition, van Samkar et al. reviewed the literature regarding *C. fetus* meningitis and found that 9 of 22 patients (40%) with *C. fetus* meningitis between 1960 and 2013 had chronic alcoholism (1). In total, we identified 24 previously published cases that also showed a relationship between alcohol and *C. fetus* meningitis (Table) (1, 3-21). These findings imply that *C. fetus* meningoencephalitis may also be related to chronic alcoholism.

No treatment protocol for *C. fetus* meningoencephalitis has yet been established. While the present case was successfully treated with ampicillin monotherapy, as shown in Table, most previously documented *C. fetus* meningitis cases were treated with multiple or broad-spectrum antibiotics. However, there is no clear evidence that *C. fetus* meningitis should be treated with multiple antibiotics, as two other cases were successfully treated by ampicillin or amoxicillin monotherapy (4).

One other report recommended using imipenem for *C. fetus* central nervous system infections or patients with a severe status (5). However, this treatment has some problems.

First, the use of broad-spectrum antibiotics such as

**Table. Summary of the Clinical Data of Patients with Campylobacter Fetus Meningoencephalitis.**

Case no. (reference)	Sex	Age	Underlying condition(s)	WBC in CSF	CSF glucose	CSF protein	Neck stiffness	Headache	Confusion	Imaging	Treatment	Outcome
Present case	M	56	Chronic alcoholism	142/μL	58 mg/dL	94 mg/dL	+	-	+	contrast MRI	ABPC	Cured
1 (1)	F	23	NA	308/μL	30.6 mg/dL	90 mg/dL	+	-	-	NA	AMPC, CTRX	Cured
2 (1)	M	52	NA	243/μL	18 mg/dL	176 mg/dL	+	-	-	NA	AMPC, CTRX	Cured
3 (6)	M	38	Chronic alcoholism	2,048/μL	48.6 mg/dL	100 mg/dL	+	-	-	NA	ABPC, GM	Cured
4 (7)	M	68	Metastatic adenocarcinoma of rectum	NA	NA	NA	NA	NA	NA	NA	EM	Died
5 (7)	M	65	Alcoholic cirrhosis	NA	NA	NA	NA	NA	NA	NA	CEZ, TOB, AMPC, GM	Cured
6 (8)	M	47	Diabetes mellitus	48/μL	104.4 mg/dL	81 mg/dL	NA	NA	NA	NA	CP, EM	Cured
7 (9)	F	39	Chronic alcoholism	NA	5.4 mg/dL	131 mg/dL	NA	NA	NA	NA	AMPC/CVA	Cured
8 (9)	M	36	Chronic alcoholism	NA	30 mg/dL	95 mg/dL	NA	NA	NA	NA	ABPC, THP	Cured
9 (10)	M	83	Alcoholic cirrhosis	577/μL	91.8 mg/dL	60 mg/dL	NA	NA	NA	NA	CPFX, CTRX	Died
10 (3)	M	47	Chronic alcoholism	300/μL	57.6 mg/dL	85 mg/dL	NA	NA	NA	NA	OFLX, GM	Cured
11 (5)	M	71	Diabetes mellitus	11,100/μL	95.4 mg/dL	508 mg/dL	+	-	NA	NA	ABPC, GM, IPM, CTX, CPFX	Cured
12 (11)	M	47	Chronic alcoholism	2,128/μL	240 mg/dL	152 mg/dL	+	-	NA	NA	PEN, TET	Cured
13 (12)	M	55	Chronic lymphocytic leukemia	240/μL	NA	NA	+	-	NA	NA	PEN, TET	Cured
14 (13)	F	48	Rheumatic fever	1,399/μL	NA	NA	+	-	NA	NA	PEN, CP	Cured
15 (14)	M	50	Diabetes mellitus	3,436/μL	20 mg/dL	96 mg/dL	-	+	NA	NA	PEN, ABPC, CP	Cured
16 (15)	F	69	Diabetes mellitus	1,230/μL	NA	NA	-	-	NA	NA	PEN, CP, SFZ	Died
17 (16)	M	40	NA	8,464/μL	50 mg/dL	120 mg/dL	+	-	NA	NA	ABPC, PEN, STR, EM	Cured
18 (17)	M	50	NA	36/μL	70 mg/dL	73 mg/dL	-	+	-	NA	ABPC, CP	Cured
19 (9)	M	36	Chronic alcoholism	156/μL	22 mg/dL	95 mg/dL	-	-	-	NA	AMPC	Cured
20 (18)	M	55	Alcoholic hepatitis	400/μL	106 mg/dL	83 mg/dL	+	-	-	NA	ABPC	Cured
21 (19)	M	51	NA	NA	NA	NA	-	-	-	NA	ABPC, MFLX	Cured
22 (20)	M	40	Crohn's disease	344/μL	68 mg/dL	33 mg/dL	-	+	-	NA	NA	Cured
23 (21)	M	28	Epilepsy	170/μL	NA	NA	+	-	-	NA	EM	Cured
24 (4)	M	75	Diabetes mellitus	1,430/μL	268 mg/dL	114 mg/dL	-	-	+	NA	CTX, CPFX, AZM	Cured

ABPC: ampicillin, CTRX: ceftriaxone, GM: gentamicin, EM: erythromycin, CEZ: cefazolin, TOB: tobramycin, AMPC/CVA: amoxicillin/clavulanate, CP: chloramphenicol, OFLX: ofloxacin, IPM: imipenem, CPFX: ciprofloxacin, PEN: penicillin, TET: tetracycline, SFZ: sulfadiazine, STR: streptomycin, MFLX: moxifloxacin, AZM: azithromycin

imipenem must be limited in order to prevent the growth of organisms resistant to antibiotics. Ohmagari et al. showed that the use of carbapenems for seven days was a risk factor for infections with multidrug-resistant *Pseudomonas aeruginosa* (22). Second, imipenem carries an additional risk. Van De Beek et al. recommended avoiding imipenem for meningitis treatment because it could lower the seizure threshold (23). In the present case, once positive results for *C. fetus* were obtained from the blood culture, we suspected *C. fetus* meningoencephalitis and started ampicillin monotherapy. At this time, other bacteria were not suspected to be the cause of meningitis; therefore, we did not select empiric therapy and did not use imipenem, which is not recommended for bacterial meningitis.

When patients with chronic alcoholism present with central nervous system symptoms, we tend to diagnose alcohol-related diseases, such as alcohol withdrawal or Wernicke's encephalitis.

However, if the patient's symptoms do not improve after appropriate treatment for alcohol withdrawal, we should consider the possibility of central nervous system infection and expand the examinations. As seen in the present case, results of MRI and lumbar puncture helped us make a correct diagnosis. In conclusion, we encountered a case of *C. fetus* meningoencephalitis with chronic alcoholism successfully treated by ampicillin monotherapy.

**The authors state that they have no Conflict of Interest (COI).**

## References

- van Samkar A, Brouwer MC, van der Ende A. *Campylobacter fetus* meningitis in adults: report of 2 cases and review of the literature. *Medicine (Baltimore)* **95**: e2858, 2016.
- Farrugia DC, Eykyn SJ, Smyth EG. *Campylobacter fetus* endocarditis: two case reports and review. *Clin Infect Dis* **18**: 443-446, 1994.
- Drona F, GarcıBa-Arata I, Navas E, de Rafael L. Meningitis in adults due to *Campylobacter fetus* subspecies fetus. *Clin Infect Dis* **27**: 906-907, 1998.
- Suy F, Dũ D Le, Roux AL, Hanachi M, Dinh A, Crémieux AC. Meningitis and endocarditis caused by *Campylobacter fetus* after raw-liver ingestion. *J Clin Microbiol* **51**: 3147-3150, 2013.
- Herve J, Aissa N, Legrand P, et al. *Campylobacter fetus* meningitis in a diabetic adult cured by imipenem. *Eur J Clin Microbiol Infect Dis* **23**: 722-724, 2004.
- Malbrunot C, Zelinsky A, Genevray B. Méningite à *Campylobacter fetus* subsp. *fetus*. Une observation. *Presse Méd* **14**: 1608, 1985 (in French).
- Francioli P, Herzstein J, Grob JP. *Campylobacter fetus* subspecies *fetus* bacteremia. *Arch Intern Med* **145**: 289-292, 1985.
- Rao KV, Ralston RA. Meningitis due to *Campylobacter fetus intestinalis* in a kidney transplant recipient. *Am J Nephrol* **7**: 402-403, 1987.
- Clavelou P, Beytout J, Gourdiat A. Atteintes neurologiques au décours d'infections à *Campylobacter*. Cinq cas. *Rev Neurol (Paris)* **145**: 208-214, 1989 (in French).
- Wilhelm JM, Saraceni O, Penner MF. Méningite à *Campylobacter fetus* chez l'adulte. *Presse Méd* **25**: 1331-1332, 1996 (in French).
- Robin L, Duprey G, Jouannot J. A propos de trois cas de vibriose humaine (*Vibrio foetus*) dont une méningite. *Presse Méd* **70**: 321-323, 1962 (in French).
- Collins S, Blevins A, Benter E. Protracted bacteremia and meningitis due to *Vibrio fetus*. *Arch Intern Med* **113**: 361-364, 1964.
- Killam H, Crowder A, Jackson G. Pericarditis due to *Vibrio fetus*. *Am J Cardiol* **17**: 723-728, 1966.
- Stille W, Helm EB. Sepsis and meningitis caused by *Vibrio fetus*. *Dtsch Med Wochenschr* **94**: 2484-2488, 1969.
- Reyman TA, Silberberg B. *Vibrio fetus* septicemia. *Am J Clin Pathol* **51**: 578-583, 1969.
- Gubina M, Zajc-Satler J, Mehle J. Septicaemia and meningitis with *Campylobacter fetus* subspecies *intestinalis*. *Infection* **4**: 115-118, 1976.
- Zelinger KS, Vargas RD. Central nervous system infection by *Vibrio fetus*. *Neurology* **28**: 968-971, 1978.
- Kato H, Wakasugi H, Mukuta T. *Campylobacter fetus* subspecies *fetus* meningitis with chronic alcoholism and diabetes mellitus. *Jpn J Med* **29**: 542-544, 1990.
- Kanayama S, Ohnishi K, Yamaura T. Case of bilateral subdural empyema complicating *Campylobacter fetus* subspecies *fetus* meningitis. *Brain Nerve* **60**: 659-662, 2008.
- Umehara Y, Kudo M, Kawasaki M. *Campylobacter fetus* meningitis in a patient with Crohn's disease. *Inflamm Bowel Dis* **15**: 645-646, 2009.
- Martínez-Balzano C, Kohlitz PJ, Chaudhary P. *Campylobacter fetus* bacteremia in a young healthy adult transmitted by khat chewing. *J Infect* **66**: 184-186, 2011.
- Ohmagari N, Hanna H, Graviss L. Risk factors for infections with multidrug-resistant *Pseudomonas aeruginosa* in patients with cancer. *Cancer* **104**: 205-212, 2004.
- Van De Beek D, Brouwer MC, Thwaites GE, Tunkel AR. Advances in treatment of bacterial meningitis. *Lancet* **380**: 1693-1702, 2012.

The Internal Medicine is an Open Access journal distributed under the Creative Commons Attribution-NonCommercial-NoDerivatives 4.0 International License. To view the details of this license, please visit (<https://creativecommons.org/licenses/by-nc-nd/4.0/>).