

Oncology

Long-term survival of a patient with pulmonary metastatic urothelial carcinoma following metastasectomy



Kenichi Hasebe^a, Taku Naiki^{a,*}, Risa Oda^b, Toshiki Etani^a, Keitaro Iida^a, Yosuke Sugiyama^c, Satoshi Nozaki^a, Ryosuke Ando^a, Noriyasu Kawai^a, Ryoichi Nakanishi^b, Takahiro Yasui^a

^a Department of Nephro-urology, Nagoya City University, Graduate School of Medical Sciences, Japan

^b Department of Oncology, Immunology and Surgery, Nagoya City University, Graduate School of Medical Sciences, Japan

^c Department of Pharmacy, Nagoya City University Hospital, Nagoya, Japan

ARTICLE INFO

Keywords:

Urothelial carcinoma
Pulmonary metastasis
Bladder
Metastasectomy

ABSTRACT

Cisplatin-based systemic chemotherapy is the gold standard for the treatment of patients with metastatic urothelial carcinoma (UC), which is a chemosensitive cancer. However, long-term survival has been deemed disappointing. We describe here a case of UC with solitary pulmonary metastasis who had successfully achieved long-term disease-free survival by combination of cisplatin-based chemotherapy and pulmonary metastasectomy. From the finding of this article, we propose that adjuvant chemotherapy may be considered as a viable option after metastasectomy in low volume pulmonary metastatic UC patients.

Introduction

The gold standard for the treatment of patients with metastatic urothelial carcinoma (UC) is systemic cisplatin-based chemotherapy. A combination regimen of gemcitabine and cisplatin (GC) demonstrates an objective response rate of approximately 60%. However, long-term survival rates have been deemed disappointing in follow-up studies.¹⁾ Further, there is no other substantial therapeutic option that can improve patient survival on an individual basis. In 1982, Cowles et al.²⁾ first reported six UC patients with pulmonary metastasis who successfully achieved long-term survival with by complete resection of the metastatic lesion, however, the prognostic significance is not still fully understood. We report here a case of UC patient with solitary pulmonary metastasis who has successfully achieved long-term disease-free survival with a combination of GC adjuvant chemotherapy and pulmonary metastasectomy after induction systemic chemotherapy.

Case report

A 66-year-old Asian male visited our hospital with asymptomatic macrohematuria. Enhanced computed tomography (CT) and magnetic resonance imaging (MRI) revealed multiple advanced-stage bladder tumor that were 3 cm in maximum diameter (Fig. 1A and B), and transurethral resection was performed. Pathological findings revealed

invasive UC, thus, radical cystectomy and ileal conduit were also performed. The final diagnosis was high grade invasive UC without vascular invasion, and the pathological stage was T1N0M0 (Fig. 1C). Three years after the operation, CT revealed a solitary 8 mm-sized nodule in the right middle lobe of the lung (Fig. 1D). This lesion gradually enlarged in two months, therefore, after repeated systemic search by imaging examinations and based on a clinical diagnosis of metastatic UC from the bladder, a total of 6 cycles of combination induction chemotherapy using gemcitabine (gemcitabine 1000 mg/m² on days 1, 8 and 15), and cisplatin (70 mg/m² on day 2) were performed. In the interval between chemotherapy courses, CT revealed that the inner signal of the metastatic pulmonary lesion had turned rough (Fig. 1E), and the therapeutic evaluation based on RESIST ver1.0 was stable disease. However, in the view of adverse event, including grade 3 myelosuppression demonstrated by decreases in white blood cells and platelets appeared during the later courses of the induction GC chemotherapy, therefore, partial resection of the right middle lobe of the lung was performed after informed consent (Fig. 2A). Pathological finding revealed high grade invasive UC that had the following immunohistochemical profile: positivity for cytokeratin 7, negativity for cytokeratin 20, and TTF-1 (Fig. 2B, C, 2D, 2E, 2F). He was administered additional 3 cycles of GC combination chemotherapy as adjuvant therapy. Three years after the operation, he had no sign of recurrence and was considered to have achieved long-term disease-free survival.

* Corresponding author: Department of Nephro-urology, Nagoya City University, Graduate School of Medical Sciences, Kawasumi 1, Mizuho-cho, Mizuho-ku, 467-8601, Nagoya, Japan.

E-mail address: naiki@med.nagoya-cu.ac.jp (T. Naiki).

<https://doi.org/10.1016/j.eucr.2018.08.024>

Received 14 August 2018; Accepted 22 August 2018

Available online 03 September 2018

2214-4420/© 2018 The Authors. Published by Elsevier Inc. This is an open access article under the CC BY-NC-ND license (<http://creativecommons.org/licenses/by-nc-nd/4.0/>).

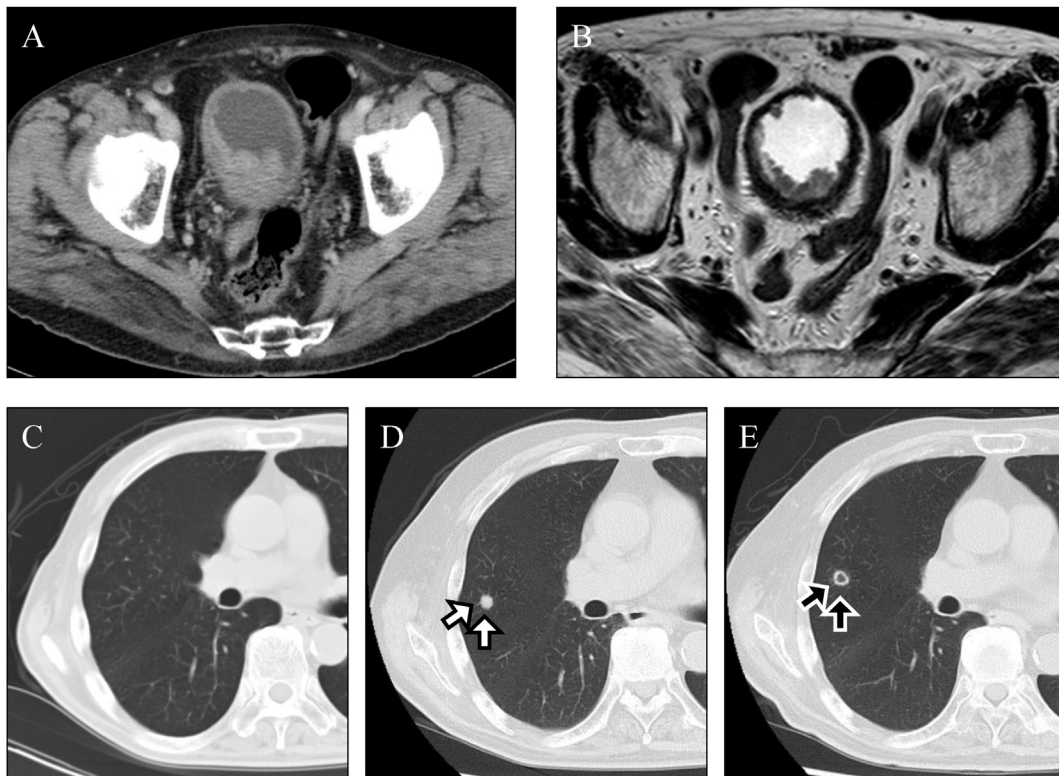


Fig. 1. A, B, Abdominal enhanced CT (A) and T2-weighted MRI (B) showed multiple advanced-stage bladder tumors that were 3 cm in maximum diameter. C, Plain CT of the chest demonstrated the absence of metastatic lesion in radical operation. D, Chest CT revealed a solitary 8 mm-sized nodule in the right middle lobe of the lung, 3 years after radical operation (white arrow). E, Chest CT revealed that the inner signal of the metastatic lesion had turned rough after 6 cycles of induction chemotherapy (black arrow).

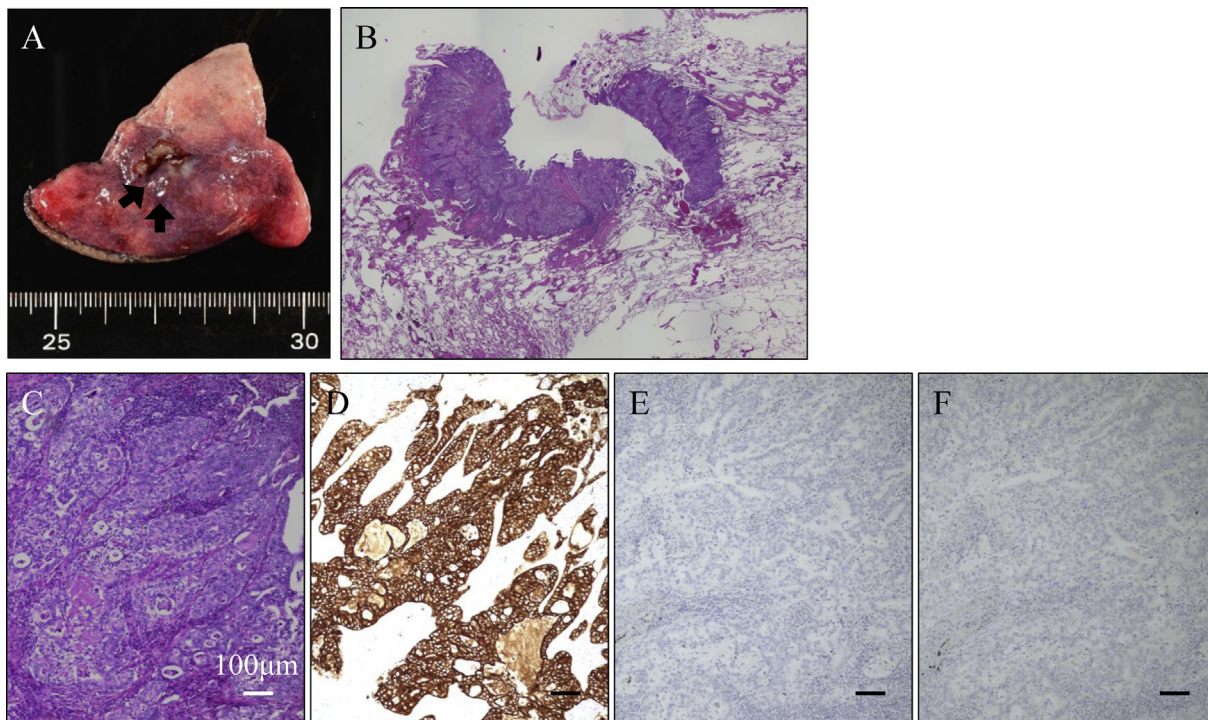


Fig. 2. A, Macroscopical findings of the specimen of the right middle lobe following partial resection. A tiny yellowish tumor was observed surrounded by normal tissue. B, C, HE staining of the specimen of the right middle lobe of the lung following partial resection. By gross examination, the infiltrating metastatic urothelial carcinoma was recognized. D, E, F Immunohistochemical staining of the metastatic urothelial carcinoma lesion shows positivity for cytokeratin 7 (D) and negativity for cytokeratin 20 (E) and TTF-1 (F).

Discussion

According to the guidelines, systemic chemotherapy is the standard treatment for metastatic UC patients. However, the survival rate is still disappointing, and median overall survival (OS) was approximately 12 months. Some reports have described consolidative metastasectomy after chemotherapy to treat single or oligometastatic lesion(s) in select patients in order to improve the survival. Further, several groups have evaluated the role of surgical resection of pulmonary metastasis as a part of a multidisciplinary approach.³⁾ However, the oncological outcomes were variable; and OS ranged from 7 to 62 months, and the 3-year survival rate ranged from 12% to 71.6%. The identification of prognostic factors is important for selecting patients who are likely to benefit the most from therapy, and poor performance status (PS), number of visceral metastatic lesions, and metastatic lesions less than 3 cm in size were identified to be independent factors associated with worse prognosis. Considering the clinical course of this case, there were several aspects, including a favorable PS and the presence of a solitary small volume pulmonary metastatic lesion, that may have led to the better prognosis.

Metastasectomy without chemotherapy is not usually recommended, however, there is no clear evidence against this. In 2009, Lehman et al.⁴⁾ reported two long-term survivors with UC after pulmonary metastasectomy who never received chemotherapy. However, they were very limited cases, and the retrospective design and selection bias may have overestimated the efficacy. Due to the benefits of neoadjuvant chemotherapy for muscle-invasive bladder cancer and the basic oncological concept that metastatic disease requires systemic therapy, it is preferable to administer preoperative chemotherapy. In this case, after 6 courses of chemotherapy, the MIB-1 index, which is the index of malignant proliferation, of the pulmonary metastatic specimen was approximately 20%, which was almost identical to that of the radical cystectomy specimen (Fig. 3A, B, 3C, 3D), which indicated

that repetition of the cisplatin-based chemotherapy alone did not have a substantial effect on the metastatic lesion. And in this case, we added additional 3 cycles of GC chemotherapy as adjuvant treatment because we assumed the existence of micrometastases of UC. Therefore, combination of sequential treatment of induction GC chemotherapy and metastasectomy following GC chemotherapy might be a potent tool for controlling metastatic UC.

Currently, treatment with an immune checkpoint inhibitor has been approved by the FDA as a promising second-line therapy for patients after failing platinum-based induction treatment for advanced/metastatic disease. Immune checkpoint inhibitor is well-tolerated, and can shift the treatment paradigm from response induction to long-lasting disease stabilization, although this is observed in only approximately 20% of patients.⁵⁾ And another important issue is the selection of the best predictive markers associated with clinical response in order to determine the most appropriate therapy, whether sequential treatment of chemotherapy and immunotherapy, or in combination with metastasectomy. In the future, further prospective trials with the addition of biomarkers to help select patients are warranted to evaluate these combination strategic approaches for patients with metastatic UC. Our conclusion is limited by the fact that it is based on only one case; however, combination of systemic chemotherapy and metastasectomy appears to be able to prolong survival in UC patients with pulmonary metastasis.

Conclusion

We report here a case of UC with solitary pulmonary metastasis who had successfully achieved long-term disease-free survival by combination of GC chemotherapy and pulmonary metastasectomy. Adjuvant chemotherapy may be considered as a viable option after metastasectomy to prolong disease-free survival in patients with pulmonary metastatic UC.

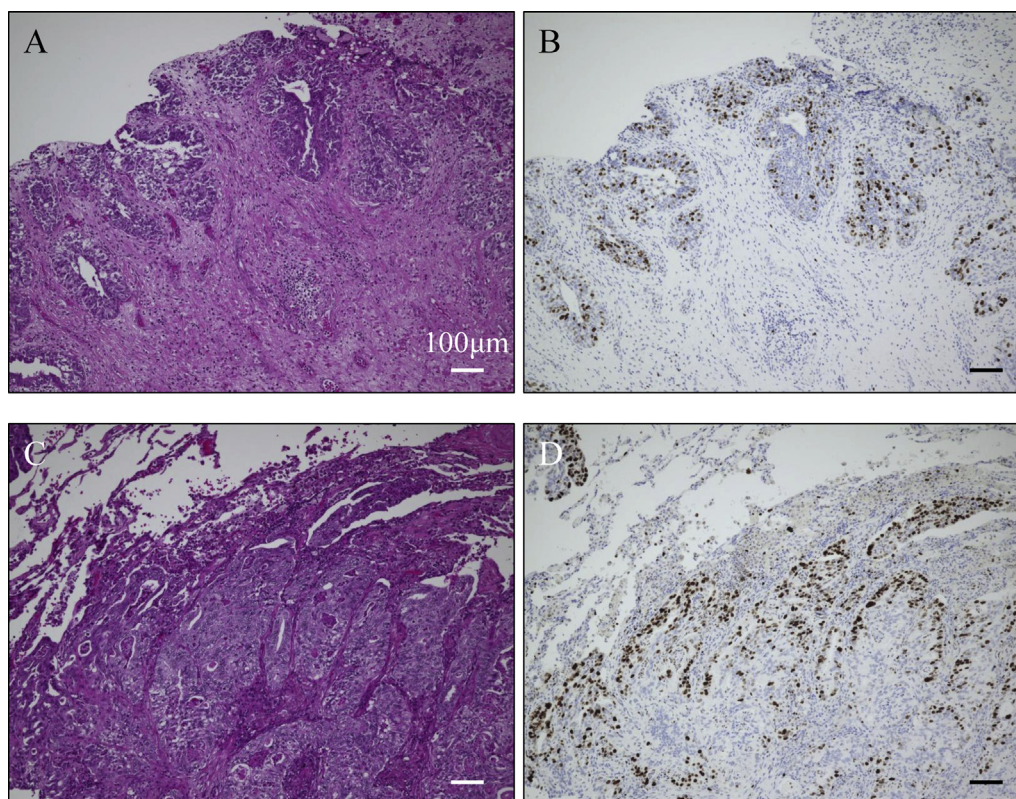


Fig. 3. HE and immunohistochemical staining of radical cystectomy specimen (A, B), and the right middle lobe of the lung specimen following partial resection (C, D). These specimens demonstrated very similar MIB-1 index (about 20%) by immunohistochemical analysis for Ki67 (B, D).

Declaration of potential conflicting interests

There are no potential conflicts of interest.

Funding

The authors received no financial support for the research, authorship, and/or publication of this article.

Declarations

This article was approved by the Nagoya City University Institutional Review Board, and the approval number was 60-18-0032.

Consent

Written informed consent was obtained from the patient for publication of this case report and accompanying images. A copy of the written consent is available for review by the Editor-in Chief of this journal.

Acknowledgments

None.

Appendix A. Supplementary data

Supplementary data related to this article can be found at <https://doi.org/10.1016/j.eucr.2018.08.024>.

References

1. Bellmunt J, von der Maase H, Mead GM, et al. Randomized phase III study comparing paclitaxel/cisplatin/gemcitabine and gemcitabine/cisplatin in patients with locally advanced or metastatic urothelial cancer without prior systemic therapy: EORTC Intergroup Study 30987. *J Clin Oncol*. 2012;30(10):1107–1113.
2. Cowles RS, Johnson DE, McMurtrey MJ. Long-term results following thoracotomy for metastatic bladder cancer. *Urology*. 1982;20(4):390–392.
3. Abufaraj M, Dalbagni G, Daneshmand S, et al. The role of surgery in metastatic bladder cancer: a systematic review. *Eur Urol*. 2018;73(4):543–557.
4. Lehmann J, Suttman H, Albers P, et al. Surgery for metastatic urothelial carcinoma with curative intent: the German experience (AUO AB 30/05). *Eur Urol*. 2009;55(6):1293–1299.
5. Bellmunt J, de Wit R, Vaughn DJ, et al. Pembrolizumab as second-line therapy for advanced urothelial carcinoma. *N Engl J Med*. 2017;376(11):1015–1026.