

Case Report

Unmasking of myoclonus by lacosamide in generalized epilepsy



Daniel Birnbaum*, Mohamad Koubeissi

George Washington University, 2150 Pennsylvania Ave NW, Suite #9-400, Washington, DC 20037, United States

ARTICLE INFO

Article history:

Received 11 March 2016

Received in revised form 25 August 2016

Accepted 13 September 2016

Available online 16 November 2016

Keywords:

Juvenile myoclonic epilepsy

Genetic generalized epilepsy (GGE)

Lacosamide

Seizure

Aggravate

Myoclonus

ABSTRACT

Lacosamide is a new-generation antiseizure medication that is approved for use as an adjunctive treatment and monotherapy in focal epilepsy. Its use in generalized epilepsy, however, has not been adequately evaluated in controlled trials. We report a 67-year-old woman who experienced new-onset myoclonic seizures after initiation of lacosamide. We presume that she had an undiagnosed generalized epilepsy syndrome, likely juvenile myoclonic epilepsy. Myoclonic seizures were not reported before introducing lacosamide and completely resolved after lacosamide was discontinued. This suggests that lacosamide may have the potential to worsen myoclonus, similar to what has been reported with another sodium channel agent, lamotrigine, in some individuals with genetic generalized epilepsy (GGE).

© 2016 The Author(s). Published by Elsevier Inc. This is an open access article under the CC BY-NC-ND license (<http://creativecommons.org/licenses/by-nc-nd/4.0/>).

1. Introduction

Juvenile myoclonic epilepsy (JME) comprises 2–10% of all epilepsies, and more than 25% of genetic generalized epilepsy (GGE). Estimates of frequency vary in different clinical settings and across regions and countries, which may be due to variations in diagnostic criteria [1]. Appropriate treatment includes valproic acid (VPA), levetiracetam (LEV), topiramate, zonisamide (ZNS), and lamotrigine (LTG) among others [2]. Some antiseizure medications (ASMs) are also known to aggravate JME, including sodium channel agents such as carbamazepine (CBZ), phenytoin (PHT) [3], and oxcarbazepine [4]. Another sodium channel blocker, LTG, is often used successfully in JME, although it can exacerbate myoclonus in some individuals [5].

Approximately 20% of individuals with JME continue to have seizures on VPA, the most efficacious ASM for the syndrome [2]. Although the indication for the majority of new-generation ASMs is in focal epilepsy, there is interest in exploring their application in generalized epilepsy. A case series of three individuals with refractory JME reported benefit from lacosamide (LCM) without adverse reactions [6]. Here, we report a case of *de novo* myoclonic seizures occurring after introducing LCM, which completely resolved with its discontinuation.

2. Case history

A 67-year-old right-handed woman has a history of generalized tonic-clonic seizures that started at age 17, when she was sleep-

deprived. Her seizures were managed well with phenobarbital (PB) until a decade prior to her presentation, when she had two breakthrough generalized tonic-clonic (GTC) seizures. She was found to have a left-sided subdural hemorrhage and was switched from PB to VPA 1500 mg/day. This was later adjusted to VPA 2000 mg/day and LEV 1000 mg/day was added. Later, VPA was replaced by LCM, given fewer cognitive side effects in the setting of comorbid dementia. Shortly after initiating treatment with LCM, she began experiencing myoclonic jerks 3–4 days per week for 15 min after awakening. According to her husband, these jerks consisted primarily of flexion at the trunk that could cause her to fall. The primary neurologist noted that myoclonic jerks also affected the upper extremities. On the morning prior to admission, she experienced repetitive myoclonic jerks of the entire body for 1 min, which were followed by a generalized seizure, and the myoclonus continued after the generalized seizure. Over the course of approximately fifty years, this was her fifth or sixth generalized seizure. She had a past medical history of advanced dementia, subdural hemorrhage in 2004 that was surgically evacuated, hypertension, and asymptomatic atrial fibrillation. Her family history was positive for epilepsy in her mother and grandmother.

The patient's physical examination upon admission to the hospital demonstrated confusion. Her general laboratory evaluation was normal. A CT brain taken on admission showed old left cerebellar and pontine lacunar strokes, and a subsequent MRI did not reveal mesial temporal sclerosis. Previous EEG in 2004, by charted information, revealed "bursts of generalized slowing and some sharp and slow waves", consistent with genetic generalized epilepsy. A later EEG in 2008 was entirely normal. An EEG after discharge in 2014 showed slowing of the posterior background rhythm to 6–7 Hz and generalized, frontal-maximum spike-and-slow waves occurring singly, at a frequency of once every

* Corresponding author.

E-mail addresses: DBirnbaum@gwu.edu (D. Birnbaum), MKoubeissi@mfa.gwu.edu (M. Koubeissi).

10–15 min, with phase reversals over F3 and F4 (Fig. 1). In addition, there were some asymmetric sharply-contoured waveforms occurring on the right and left, independently. A follow-up EEG showed only background slowing to 6–8 Hz.

The presentation of morning myoclonus followed by GTC seizure, teenage history of seizure after sleep deprivation, family history, and EEG findings were suggestive of generalized epilepsy, likely JME. Thus, LCM was discontinued and ZNS was initiated at 300 mg per day. LEV was increased to 1500 mg per day. A subsequent visit to the hospital, less than a month later, verified that her myoclonus had completely stopped upon discontinuation of LCM. An EEG three months after the admission revealed complete resolution of the interictal epileptiform discharges, with persistence of the background slowing.

3. Discussion

The diagnosis of JME in this individual was difficult because continuous video-EEG was not performed to capture ictal episodes. According to the International League Against Epilepsy definition of JME, interictal and ictal EEG may be similar and show rapid, generalized, often irregular spike-waves and polyspike-waves [7]. Other abnormalities that may be present in a random sampling of individuals with JME include frontal (>8%) and temporal (~5%) spike/sharp waves [8]. Our patient's EEG in 2004, 10 years prior to her presentation, was consistent with generalized epilepsy. A subsequent EEG in 2008 was normal, and an EEG after discharge from the hospital demonstrated generalized, frontal maximal, single spike-wave discharges, further supporting generalized epilepsy, associated with myoclonic seizures. Another EEG from 2013 noted frequent sharp waves and occasional higher voltage spikes over the left superior frontal and temporal areas. These focalities and the sharply contoured waves from the 2014 EEG may have represented focal discharges secondary to one of her many comorbidities, including subdural hemorrhage, multiple strokes, and advanced dementia. Alternatively, focal discharges may represent effective inhibitory mechanisms that successfully fragment generalized epileptiform discharges in JME [9]. Ultimately, focal EEG findings can be seen in JME and should not exclude JME as the etiology of an individual's epilepsy [8].

In the past, uncertainty about a diagnosis of JME in this individual likely revolved around a lack of morning myoclonus. Treatment with LCM unmasked her myoclonus and was followed by a GTC seizure.

Given this individual's dementia, it is also possible that earlier in her life she had myoclonus but had forgotten it when later questioned.

To verify that this was a drug-related adverse event, the Naranjo method was employed. It revealed that this was a “possible” adverse drug reaction. In the future, when myoclonus is encountered with LCM use, in order to establish this as a “probable” or “definite” reaction, clinicians can decrease the dose of LCM prior to discontinuation, consider readministration of LCM after cessation, obtain drug levels, and confirm myoclonus through direct visualization [10].

In consideration of this myoclonus exacerbation being peculiar to LCM use in IGE and JME, several points can be raised. A review of adverse side effects of LCM does not include myoclonus [11]. Additionally, this individual's myoclonus was unlikely to have been related to high or toxic drug levels. LTG, for example, at toxic levels, can trigger myoclonus even when a seizure history is not present [12]. This individual was using a standard dose of LCM. As there were no other reported side effects, toxicity was unlikely. LCM's pharmacology may have also played a role. Several medications that affect the voltage-gated sodium channel may worsen seizures in generalized epilepsy. In particular, CBZ, OXC, and PHT have been reported to worsen absence and myoclonic seizures in GGE. LTG can worsen myoclonic seizures in some individuals with GGE. This does not occur too commonly to preclude the inclusion of LTG as a first line treatment in JME [2]. Lastly, genetics can modulate the response of subsets of syndromes to medications. For example, individuals with the progressive myoclonic epilepsy, Unverricht-Lundborg disease, appear to be particularly susceptible to worsening of myoclonus when treated with LTG [13]. Similarly, the complex genetics of JME, with multiple chromosomes implicated and possibly with incomplete penetrance [14], may allow subsets of JME to be particularly vulnerable to myoclonus when LCM is utilized. Thus, some individuals may respond optimally to LCM [15], while others may experience adverse effects.

4. Conclusion

In summary, this individual's history, physical, and diagnostic information strongly suggest generalized epilepsy, likely JME, with myoclonus that was unmasked by LCM. This case suggests that LCM may have the potential to exacerbate underlying myoclonus, and its exploration as a treatment in generalized epilepsies should take into consideration the possibility of seizure exacerbation.

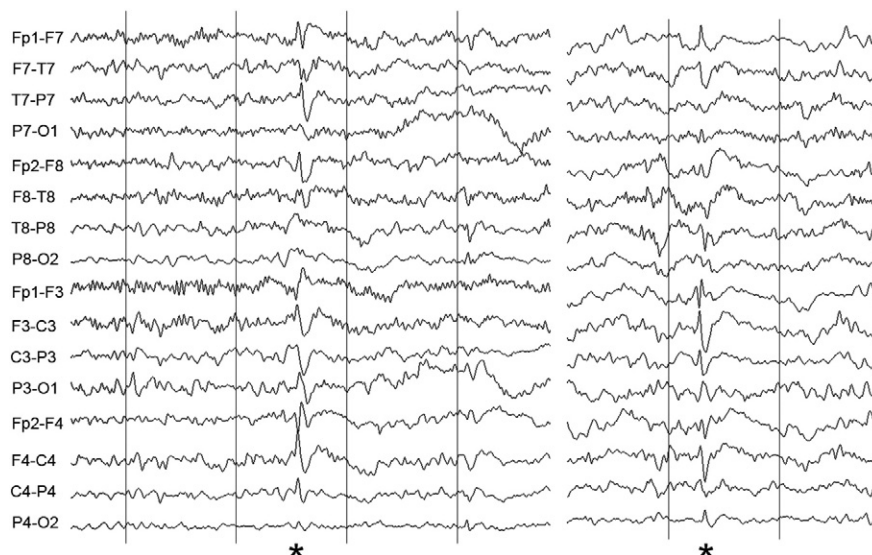


Fig. 1. Frontal-maximum, generalized spike-wave discharges (asterisks). Note the phase reversals over F3 and F4, typical of generalized epilepsy.

References

- [1] Camfield CS, Striano P, Camfield PR. Epidemiology of juvenile myoclonic epilepsy. *Epilepsy Behav* 2013;28(Suppl. 1):S15–7.
- [2] Mantoan L, Walker M. Treatment options in juvenile myoclonic epilepsy. *Curr Treat Options Neurol* 2011;13(4):355–70.
- [3] Genton P, Gelisse P, Thomas P, Dravet C. Do carbamazepine and phenytoin aggravate juvenile myoclonic epilepsy? *Neurology* 2000;55(8):1106–9.
- [4] Gelisse P, Genton P, Kuate C, Pesenti A, Baldy-Moulinier M, Crespel A. Worsening of seizures by oxcarbazepine in juvenile idiopathic generalized epilepsies. *Epilepsia* 2004;45(10):1282–6.
- [5] Auvin S. Treatment of juvenile myoclonic epilepsy. *CNS Neurosci Ther* 2008;14(3):227–33.
- [6] Afra P, Adamolekun B. Lacosamide treatment of juvenile myoclonic epilepsy. *Seizure* 2012;21(3):202–4.
- [7] Proposal for revised classification of epilepsies and epileptic syndromes Commission on classification and terminology of the international league against epilepsy. *Epilepsia* 1989;30(4):389–99.
- [8] Jayalakshmi SS, Srinivasa Rao B, Sailaja S. Focal clinical and electroencephalographic features in patients with juvenile myoclonic epilepsy. *Acta Neurol Scand* 2010;122(2):115–23.
- [9] Bonakis A, Koutroumanidis M. Epileptic discharges and phasic sleep phenomena in patients with juvenile myoclonic epilepsy. *Epilepsia* 2009;50(11):2434–45.
- [10] Naranjo CA, Busto U, Sellers EM, Sandor P, Ruiz I, Roberts EA, et al. A method for estimating the probability of adverse drug reactions. *Clin Pharmacol Ther* 1981;30(2):239–45.
- [11] Vimpat: prescribing information. [December 16, 2015]. Available from: http://www.vimpat.com/pdf/vimpat_PI.pdf; 2015.
- [12] Moore PW, Donovan JW, Burkhart KK, Haggerty D. A case series of patients with lamotrigine toxicity at one center from 2003 to 2012. *Clin Toxicol (Phila)* 2013;51(7):545–9.
- [13] Genton P, Gelisse P, Crespel A. Lack of efficacy and potential aggravation of myoclonus with lamotrigine in Unverricht-Lundborg disease. *Epilepsia* 2006;47(12):2083–5.
- [14] Panayiotopoulos C. *The epilepsies: seizures, syndromes and management*. Oxfordshire (UK): Bladon Medical Publishing; 2005.
- [15] Yorns Jr WR, Khurana DS, Carvalho KS, Hardison HH, Legido A, Valencia I. Efficacy of lacosamide as adjunctive therapy in children with refractory epilepsy. *J Child Neurol* 2014;29(1):23–7.