


ORIGINAL RESEARCH

Pneumoperitoneum after transoral endoscopic thyroidectomy vestibular approach

James Wei Ming Kwek MBBS (S'pore), DWD (CAW), MRCS (Edin), MMed (ORL)  |
Maria Judith Pang MBBS (S'pore), MRCS (Edin), MMed (ORL) |
Harold H. W. Heah MBBS (S'pore), MRCS (Edin), MMed (ORL)

Department of Otolaryngology Head and Neck Surgery, Singapore General Hospital, Singapore

Correspondence

James Wei Ming Kwek, Department of Otolaryngology, Singapore General Hospital, 20 College Road, The Academia Level 5, Singapore 169856.
Email: kwekhuman@gmail.com

Abstract

Background: Transoral endoscopic thyroidectomy vestibular approach (TOETVA) is a relatively safe procedure with comparable safety profile as open thyroidectomy. While gas insufflation complications such as subcutaneous emphysema and pneumomediastinum have been reported postoperatively, there have been no reports of pneumoperitoneum.

Case report: Our patient underwent an uneventful TOETVA to remove her left thyroid lobe. Postoperatively, she developed subcutaneous emphysema, pneumomediastinum, and pneumoperitoneum, which were confirmed on CT scan. She was managed conservatively and recovered uneventfully.

Conclusion: The authors report the first case of pneumoperitoneum following TOETVA. Surgeons performing TOETVA should be aware of pneumoperitoneum as a possible complication of this procedure after excluding other possible causes.

KEYWORDS

endoscopic, gas-insufflation complications, pneumoperitoneum, thyroidectomy, transoral endoscopic thyroidectomy

1 | INTRODUCTION

Transoral endoscopic thyroidectomy vestibular approach (TOETVA) is a relatively safe procedure and has comparable complication rates with respect to conventional thyroidectomy outcome with additional potential adverse outcomes.^{1,2,3,4} While gas insufflation-related complications such as subcutaneous emphysema, pneumothorax, and pneumomediastinum may arise from this approach, there have been no reports of pneumoperitoneum.

2 | CASE REPORT

The patient is a 30-year old Chinese woman with a past medical history of pan-ulcerative colitis in remission. She presented with a right thyroid upper pole 2.5 cm nodule. Ultrasonography of the thyroid showed a 2.5 cm × 2.1 cm × 1.5 cm solid TIRADS 3 right thyroid nodule. Size of right thyroid lobe was 4.4 cm × 1.8 cm × 1.1 cm. Fine needle aspiration of the nodule reported a follicular lesion of undetermined significance. She was counseled and consented for an elective transoral endoscopic

This is an open access article under the terms of the Creative Commons Attribution-NonCommercial-NoDerivs License, which permits use and distribution in any medium, provided the original work is properly cited, the use is non-commercial and no modifications or adaptations are made.

© 2020 The Authors. *Laryngoscope Investigative Otolaryngology* published by Wiley Periodicals, Inc. on behalf of The Triological Society.

right hemithyroidectomy. Preoperatively, she was reviewed by her gastroenterologist who confirmed that her ulcerative colitis was in remission and given clearance to proceed with thyroid surgery.

2.1 | Surgical procedure

The patient was placed under general anesthesia with transoral intubation with a nerve-monitoring endotracheal tube. She was placed in a supine position with her neck extended. The oral cavity was disinfected using chlorhexidine cleansing solution. Two percent of lignocaine in 1:80 000 adrenaline was injected into the oral vestibular area of the lower lip at the three port sites. Vestibular incisions were made for camera and working ports. The first 10 mm incision was made at the center of the oral vestibule, with a subsequent space created passing the mandibular area to the anterior neck using an electric scalpel and Kelly clamp forceps. A blunt-tipped 10-mm trocar was inserted for a 10-mm 30° laparoscope. The CO₂ insufflation pressure was set at 6 mm Hg with low-flow settings. Two 5 mm trocars were inserted at the uppermost and lateral areas near the lower lip on both sides pointing down to the anterior neck. Subsequently, a working space was created beneath the platysma first with hydro-dissection using 50 mL of 1:500 000 adrenaline-saline solution, followed by dissection with an olive-tip dilator. The boundaries of the working space created was as follows: level of the hyoid bone superiorly, sternal notch inferiorly and the anterior borders of both sternocleidomastoid muscles laterally. The sternohyoid muscles were separated in the midline. The sternothyroid muscle was dissected off the surface of the left thyroid lobe. The thyroid isthmus was dissected and isthmusectomy performed. An ultrasonic device was used for the dissection and division of tissue and vessels. The superior pole and superior pole vessels were identified, sealed and divided with the ultrasonic device. The superior parathyroid gland was identified and preserved. The upper pole of the gland was retracted and rotated medially to identify and preserve the recurrent laryngeal nerve (RLN). The inferior thyroid vessels were sealed and divided close to the gland. The hemithyroidectomy specimen was removed using an endopouch via the 10-mm incision. The sternothyroid muscles were re-apposed using absorbable sutures. The oral vestibule surgical wound was closed in layers, taking care to re-appose the mentalis. A pressure dressing was applied around the chin for 24 hours. Total duration of surgery was 3 hours 35 minutes.

2.2 | Postoperative care

In her first post-op review about 30mins later in the PACU, she was noted to have subcutaneous emphysema in the neck, chest and bilateral arms. There were no complaints of chest pain or shortness of breath. Eight hours postoperatively, she developed mild shortness of breath and chest pain. Her vital signs remained stable and oxygen saturations were normal on room air. The electrocardiogram was normal. Chest X-ray showed a small right pneumothorax and pneumomediastinum (Figure 1). She was placed on 5 L O₂ on O₂ prongs and her symptoms improved. On the

second postoperative day, a repeat chest X-ray showed interval improvement in size of pneumothorax and pneumomediastinum. However, a sliver of air was still seen under the right hemidiaphragm (Figure 2).

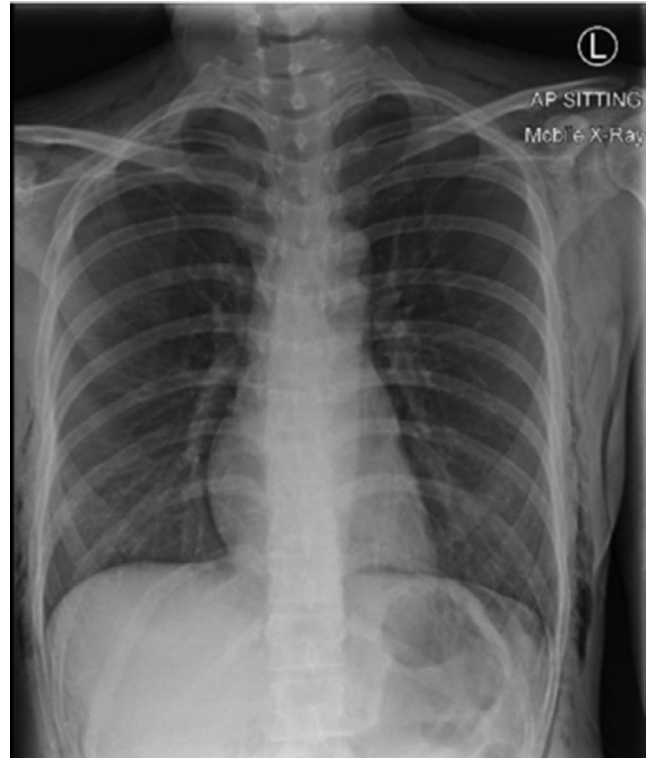

FIGURE 1 Chest X-ray done 8 hours postoperatively

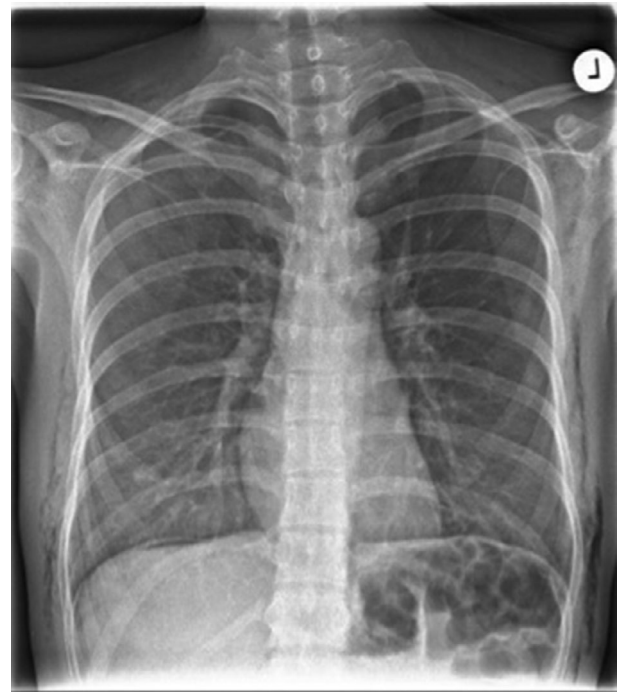


FIGURE 2 Repeat chest X-ray 24 hours postoperatively, showing (a) air under the right hemidiaphragm and (b) partial resolution of right pneumothorax

Computed tomography (CT) scan of the neck and abdomen was performed which showed subcutaneous emphysema tracking along neck, axilla and chest wall, a small pneumomediastinum and small bilateral apical pneumothoraxes. Gas locules were also noted in the right upper abdominal quadrant, around the gastric pylorus and duodenum as well as extraperitoneal and retroperitoneal gas. There was no evidence of viscus perforation or bowel inflammation (Figure 3). Serum amylase and lipase were in the normal range. The patient reported mild vague abdominal discomfort over the next 2 days. There was mild epigastric discomfort on palpation but no guarding or rebound tenderness. She was reviewed by the general surgeon whose opinion was that the pneumoperitoneum was not due to gastrointestinal perforation, and more likely due to gas insufflation from surgery. Decision was made to manage her conservatively. She was kept nil by mouth as a precaution and treated with prophylactic intravenous antibiotics.

Her diet was gradually escalated as her symptoms resolved. Repeat CT scan on postoperative day 7 showed interval reduction in intraperitoneal free air (Figure 4). Repeat chest X-ray also showed

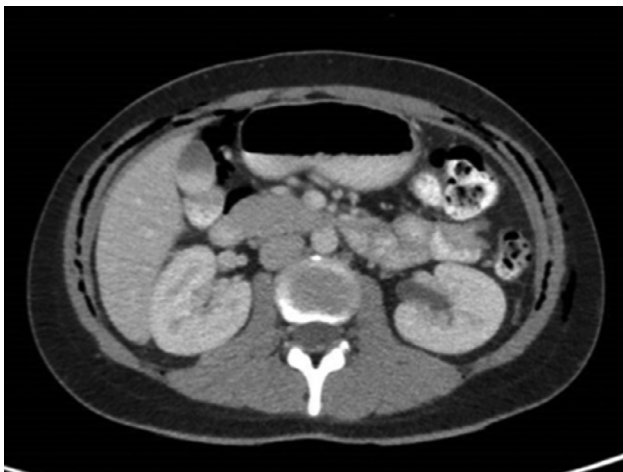

FIGURE 3 Axial cut of CT Abdomen on POD2 showing air collection around the stomach and duodenum as well as subcutaneous emphysema

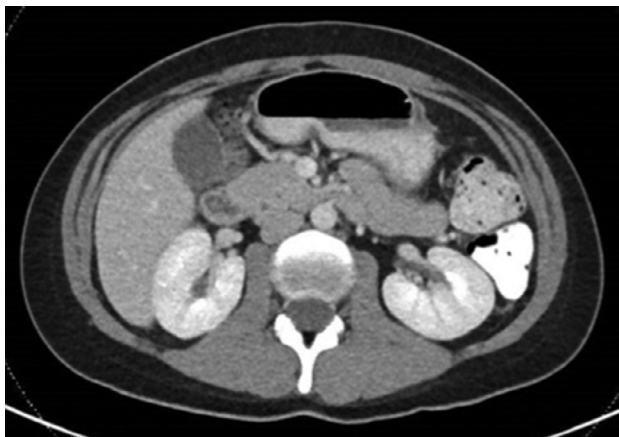


FIGURE 4 Axial cut of CT Abdomen on POD7 showing resolution of pneumoperitoneum and improvement in subcutaneous emphysema

complete resolution of pneumothorax and pneumomediastinum. She was discharged home well 7 days postoperatively.

3 | DISCUSSION

Transoral endoscopic thyroidectomy vestibular approach (TOETVA) is a relatively safe procedure^{3,4,5,6,7,8,9} with several large case series reporting comparable complication rates with open thyroidectomy.^{1,2,10} Anuwong et al reported a large series of 422 patients who underwent TOETVA showing no significant difference in complication rates between TOETVA and open approach.¹ Camenzuli et al concurred that the rates of recurrent laryngeal nerve palsy, postoperative hypocalcemia, infection, and bleeding after transoral thyroidectomy are comparable to those after conventional thyroidectomy.²

While gas-insufflation-related complications such as subcutaneous emphysema, pneumomediastinum and pneumothorax are possible, these are uncommon. Anuwong et al¹ reported no cases of mediastinal emphysema. A subsequent case series by the same unit reported seven cases of subcutaneous emphysema out of 200 patients, all of which were treated conservatively. In a systematic review by Camenzuli et al,² there were six (0.8%) cases of subcutaneous emphysema that were all self-limiting^{3,11} and an additional case (0.1%) of mediastinal emphysema that did not carry long-term consequences. In the small case series by Bakkar et al, all five patients developed subcutaneous emphysema that resolved within 12-48 hours.¹² One Taiwanese case series of 80 patients¹³ had a particularly high rate of post-op subcutaneous emphysema (38.8%), of which some had stridor and difficulty breathing requiring a longer PACU stay. However, all were managed conservatively with oxygen therapy and resolved with no major complications.

There have been some authors reporting on how best to avoid gas-insufflation-related complications.^{14,15} Anuwong¹⁵ recommended the following guidelines to prevent gas-insufflation-related complications: (a) CO₂ pressure should not exceed 6 mm Hg and a flow rate of 15 L/min should be set, (b) intermittent release of the gas from the working space through the valve of 5 mm ports is required, (c) close coordination with the anesthetist to titrate gas flow with end-tidal CO₂, and (d) proactive postoperative observation for gas-related complications. While limiting the size of flap dissection could also theoretically reduce the risk of gas insufflation complications, this was not found to be a significant factor in the authors' experience.

This is the first reported case of pneumoperitoneum following a TOETVA. In this case, there were no particular risk factors from the anesthesia and surgical approach point-of-view. Of note, the patient has a history of ulcerative colitis which was in remission. If the pneumoperitoneum was secondary to ulcerative colitis, it is more likely that she would have presented with an acute abdomen and other clinical features of active disease. The pneumoperitoneum would also not have resolved so quickly with conservative management. Literature¹⁶⁻²⁰ reports cases of perforation in acute ulcerative colitis but the absolute risk of perforation in ulcerative colitis remains low. The authors' operating CO₂ insufflation pressures were 6 mm Hg at low flow rate, similar to that recommended by Anuwong et al.¹⁵ It

is postulated that the pneumoperitoneum could have resulted from tracking of gas from the pneumomediastinum through the diaphragmatic hiatus, collecting around the stomach and proximal duodenum. In abdominal laparoscopic surgery, subcutaneous emphysema and pneumomediastinum are recognized complications (albeit typically self-limiting and mostly clinically insignificant) due to tracking of air from the intraperitoneal space into the thoracic cavity, mediastinum and subcutaneous layer despite the presence of a peritoneal lining. In TOETVA, the converse may be even more likely in the absence of a similar lining in the neck preventing gas from tracking into the subcutaneous layer into the mediastinum and peritoneum. To further reduce the risk of gas insufflation complications, the neck flaps should be made along the surface of the strap muscles, rather than just subplatysmal, to prevent any false entry into the supraplatysmal space.

An important point to note is that the pneumoperitoneum was picked up incidentally on the postoperative chest X-ray. While she later developed vague symptoms of abdominal discomfort, this could have easily been dismissed as a red herring. Surgeons performing TOETVA should be aware of pneumoperitoneum as a possible complication of this procedure. Although self-limiting, such a finding post-TOETVA would still necessitate a thorough work-up for viscus perforation to exclude other causes. In addition, a routine postoperative chest and abdominal X-ray should be considered. The authors also recommend that using lower pressures in patients with potential risks of colonic perforation. If the operative field cannot be sufficiently maintained with the lower pressures, 1 or 2 supporting sutures can be placed to the anterior neck to hold it up and maintain the working space. Minimizing operative time in such cases could potentially also minimize the risk of pneumoperitoneum.

4 | CONCLUSION

The authors report the first case of pneumoperitoneum following TOETVA. Surgeons performing TOETVA should be aware of pneumoperitoneum as a possible complication of this procedure and hence, strive to use lower pressures and minimize operative time. A routine postoperative chest and abdominal X-ray should be considered.

CONFLICT OF INTEREST

The authors declare no conflicts of interest.

ORCID

James Wei Ming Kwek  <https://orcid.org/0000-0002-9998-0349>

REFERENCES

- Anuwong A, Ketwong K, Jitpratoom P, Sasanakietkul T, Duh QY. Safety and outcomes of the transoral endoscopic thyroidectomy vestibular approach. *JAMA Surg*. 2017;153(1):21-27.
- Camenzuli C, Schembri Wismayer P, Calleja Agius J. Transoral endoscopic thyroidectomy: a systematic review of the practice so far. *JLS*. 2018;22(3):e2018.00026.
- Kim HK, Chai YJ, Dionigi G, Berber E, Tufano RP, Kim HY. Transoral robotic thyroidectomy for papillary thyroid carcinoma: perioperative outcomes of 100 consecutive patients. *World J Surg*. 2019;43:1038-1046.
- Chen S, Zhao M, Qiu J. Transoral vestibule approach for thyroid disease: a systematic review. *Eur Arch Otorhinolaryngol*. 2019;276:297-304.
- Shan L, Liu J. A systemic review of transoral thyroidectomy. *Surg Laparosc Endosc Percutan Tech*. 2018;28(3):135-138.
- Sivakumar T, Amizhthi RA. Transoral endoscopic total thyroidectomy vestibular approach: a case series and literature review. *J Minim Access Surg*. 2018;14(2):118-123.
- Wang Y, Xie Q, Yu X, et al. Preliminary experience with transoral endoscopic thyroidectomy via vestibular approach: a report of 150 cases in a single center. *Chin J Surg*. 2017;55(08):587-591.
- Russell JO, Clark J, Noureldine SI, et al. Transoral thyroidectomy and parathyroidectomy – a north American series of robotic and endoscopic transoral approaches to the central neck. *Oral Oncol*. 2017;71:75-80.
- Dionigi G, Bacuzzi A, Lavazza M, et al. Transoral endoscopic thyroidectomy: preliminary experience in Italy. *Updates Surg*. 2017;69:225-234.
- Jitpratoom P, Ketwong K, Sasanakietkul T, Anuwong A. Transoral endoscopic thyroidectomy vestibular approach (TOETVA) for Graves' disease: a comparison of surgical results with open thyroidectomy. *Gland Surg*. 2016;5(6):546-552.
- Anuwong A, Sasanakietkul T, Jitpratoom P, et al. Transoral endoscopic thyroidectomy vestibular approach (TOETVA): indications, techniques and results. *Surg Endosc*. 2018;32:456-465.
- Bakkar S, Al Hyari M, Naghawi M, et al. Transoral thyroidectomy: a viable surgical option with unprecedented complications - a case series. *J Endocrinol Invest*. 2018;41:809-813.
- Chen C-M, Hung I-Y, Liu W-C, et al. A great variation in the reported incidence of postoperative subcutaneous emphysema in trans-oral vestibular endoscopic thyroidectomy. *World J Surg*. 2017;41(10):2647-2648.
- Zhang D, Wu CW, Inversini D, et al. Lessons learned from a faulty transoral endoscopic thyroidectomy vestibular approach. *Surg Laparosc Endosc Percutan Tech*. 2018;28(5):e94-e99.
- Anuwong A. Strategy to prevent subcutaneous emphysema and gas insufflation-related complications in Transoral endoscopic thyroidectomy vestibular approach: reply. *World J Surg*. 2017;41:2649-2650.
- Alawad A, Ibrahim R, Tawfik S, Mansour M. Synchronous perforation of transverse and sigmoid colon due to ulcerative colitis: a rare case report. *J Chir*. 2015;11(1):349-350.
- Overbey D, Govekar H, Gajdos C. Surgical management of colonic perforation due to ulcerative colitis during pregnancy: report of a case. *World J Gastrointest Surg*. 2014;6(10):201-203.
- Choi YS, Lee IT, Cho KR, Kim JK, Suh JP, Lee DS. Education and imaging. Gastrointestinal: asymptomatic rectal perforation and massive pneumoretroperitoneum in patient with ulcerative colitis treated with mesalamine enemas. *J Gastroenterol Hepatol*. 2013;28(7):1071-1071.
- Travis S, Satsangi J, Lémann M. Predicting the need for colectomy in severe ulcerative colitis: a critical appraisal of clinical parameters and currently available biomarkers. *Gut*. 2011;60(1):3-9.
- Chahal D, Chahal T. Acute flare of ulcerative colitis resulting in perforation and managed with colectomy: case report and literature review. *UBC Med J*. 2017;8(2):27-28.

How to cite this article: Kwek JWM, Pang MJ, Heah HHW. Pneumoperitoneum after transoral endoscopic thyroidectomy vestibular approach. *Laryngoscope Investigative Otolaryngology*. 2020;5:580–583. <https://doi.org/10.1002/lio2.393>