



Contents lists available at ScienceDirect

International Journal of Surgery Case Reports

journal homepage: www.casereports.com

Total hip arthroplasty for femoral neck fracture with pyoderma gangrenosum patient: A case report



Guo Rong She^{a,1}, Jun Yuan Chen^{a,1}, Zi Qi Zhou^b, Zhen Gang Zha^{a,*}, Ning Liu^a

^a Department of Bone and Joint Surgery, The First Affiliated Hospital of Jinan University, Guangzhou, 510630, China

^b Department of Radiation Therapy, Peking Union Medical College Hospital, Beijing, 100730, China

ARTICLE INFO

Article history:

Received 10 October 2016

Received in revised form 6 December 2016

Accepted 6 December 2016

Available online 9 December 2016

Keywords:

Pyoderma gangrenosum

Femoral neck fracture

Total hip arthroplasty

ABSTRACT

INTRODUCTION: Pyoderma gangrenosum is a rare inflammatory aseptic, ulcerative neutrophilic dermatosis which manifest as skin recurrent, painful ulcers.

PRESENTATION OF CASE: A 65-year-old man with pyoderma gangrenosum underwent left total hip arthroplasty because of femoral neck fractures. Glucocorticoid, antibiotic, anticoagulant drug, etc. were given in perioperative period. Complication of pyoderma gangrenosum was prevented successfully in perioperative period.

DISCUSSION: No consensus has been reached about whether to use glucocorticoid, as well as the dosage and administration, in perioperative periods for pyoderma gangrenosum patients as prophylactic means of wound complication.

CONCLUSION: We herein report a case of pyoderma gangrenosum patient underwent total hip arthroplasty, meanwhile raise the issue of management in perioperative period for pyoderma gangrenosum patient, especially explore series of standardized therapies for this disease during arthroplasty.

© 2016 The Authors. Published by Elsevier Ltd on behalf of IJS Publishing Group Ltd. This is an open access article under the CC BY-NC-ND license (<http://creativecommons.org/licenses/by-nc-nd/4.0/>).

1. Introduction

Pyoderma gangrenosum is a rare inflammatory aseptic, ulcerative neutrophilic dermatosis, manifest as skin recurrent, painful ulcers. It was first described by Brunsting in 1930 [1]. However, pathogenesis of this disease is still unknown exactly until now. Pyoderma gangrenosum may occurs after surgery or trauma such as the surgery of breast or abdomen. It is very rare but do occurred after orthopedic surgery such as total hip replacement [2] and total knee arthroplasty [3]. Such disease is strikingly similar to the manifestation of infection. It is easy to be misdiagnosed and lead to incorrect management. We present a case of successful total hip arthroplasty for femoral neck fractures with Pyoderma Gangrenosum. This case report is in line with the SCARE criteria [4].

2. Presentation of case

A 65-year-old man, who was hospitalized in September 2015, complained bilateral hip joints pain for more than one year. Falling-down deteriorated the symptom of left side for one week. His

right malleolus medial skin was abraded and gradually formed a painful ulcer three years ago. Then he sought medical care including adequate debridement and vacuum sealing drainage treatment for several times in other hospital, but the ulcer failed to heal. Tissue from ulcer edges were taken for histopathological examination (Fig. 1), “Pyoderma Gangrenosum” was diagnosed definitely after dermatological department consultation. The ulcer was healed eventually after using prednisone acetate for two months (Fig. 2).

Physical examination: the left lower limb external rotation of 45°, 2 cm shorter than the contralateral side, left leg rolling test (+), vertical percussion pain (+), bilateral hip Patrick sign (+). Avascular necrosis in bilateral femoral heads, and left femoral neck fracture were suggested in X-ray (Fig. 3).

After adequate preoperative evaluation and preparation, left total hip arthroplasty was carried out under the combined spinal-epidural anesthesia. During operation, the deep fascia and adipose tissues were observed edematous while muscular tissues were pinky which indicated poor blood supply intraoperatively. Bleeding volume of whole surgery was about 100 ml. Drainage tube was kept conventionally.

Infection prevention, venous thrombosis prevention, analgesia and other conventional medical treatments were given according to standard clinical pathway in perioperative period of arthroplasty. In addition, 50 mg hydrocortisone was given intravenously 1 h preoperation, 1 h and 1st day postoperation respectively. Oral prednisone

* Corresponding author.

E-mail address: zhzgg@vip.163.com (Z.G. Zha).

¹ These authors contributed equally to this work.

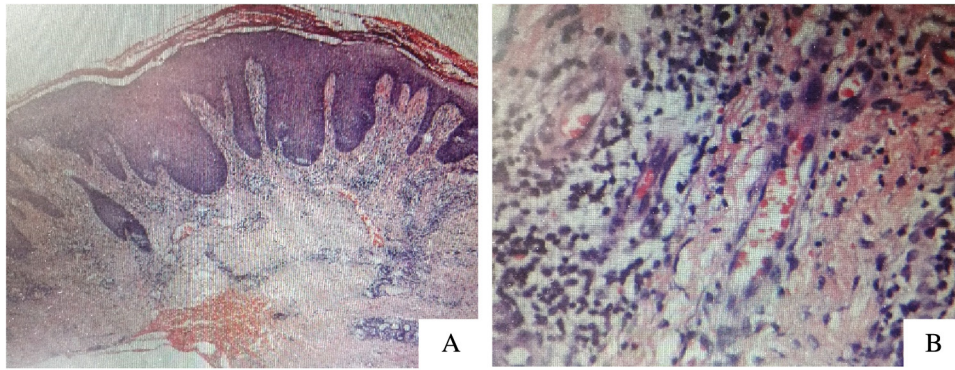


Fig. 1. Histopathological sections in other hospital. 1A (HE, ×40) Epidermal acanthosis, epidermal papilla irregular and wide extended; 1B(HE, ×100) Dermis shallow middle perivascular dense, lymphocyte and neutrophil infiltration.

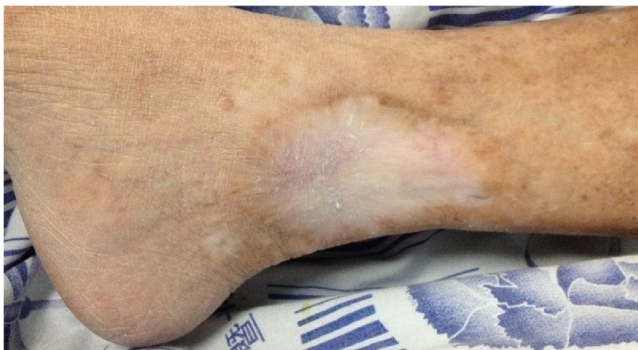

Fig. 2. Right malleolus medials skin scar healing.

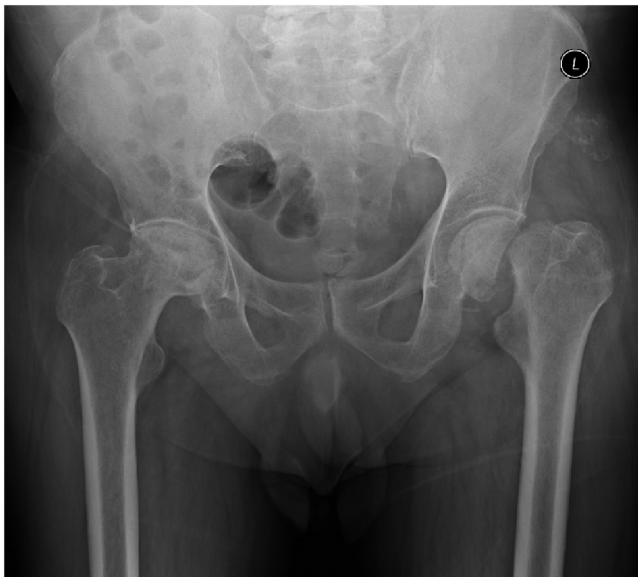

Fig. 3. Preoperative X-ray showed left femoral neck fracture.

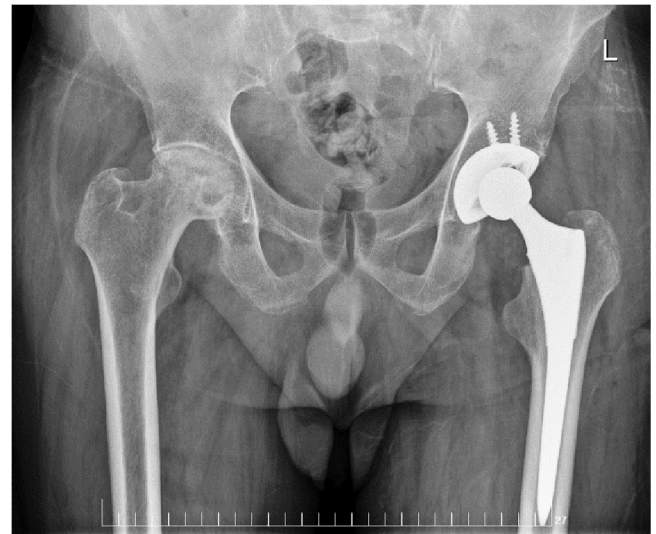


Fig. 4. Left total hip arthroplasty postoperative X-ray.

(5 mg, TID) were given from the 2nd day till the day when stitches were taken out. Drainage tube was removed 2nd day postoperation, then the patient began to walk with walking aid under medical supervision.

Yellow exudate oozed out for a week postoperation and dressing was done once or twice a day according to exudation.

decreased after 1 week, while stitches were taken out two weeks postoperation. Reexamination of X-ray showed left total hip arthroplasty prosthesis were in good position (Fig. 4).

Following-up for 1 year, the patient recovered well without any complication of surgical site. The range of motion of left hip joint is 0°–130°, which meet the daily needs (Fig. 5).

3. Discussion

Pyoderma gangrenosum is a rare disease that make tissue necrotic, causing deep ulcers which usually occur on the legs, occasionally on the whole body. Without specific therapy, the ulcers can lead to chronic wounds. Even though the etiology is not well understood, the disease is thought to be due to immune system dysfunction, and particularly improper functioning of neutrophils. It is now classified as one of the neutrophilic dermatosis (neutrophilic infiltrations of tissues). This disease may start either as a tender red nodule or a cluster of inflammatory pustules which break down to leave single or multiple irregularly shaped, deep ulcers with sloughy bases. 20% pyoderma gangrenosum is found in sites of trauma which may range from large surgical incisions to minor venipuncture sites [5].

For the pyoderma gangrenosum patients who have no history of skin ulcers, surgical incision ulceration and delayed healing after

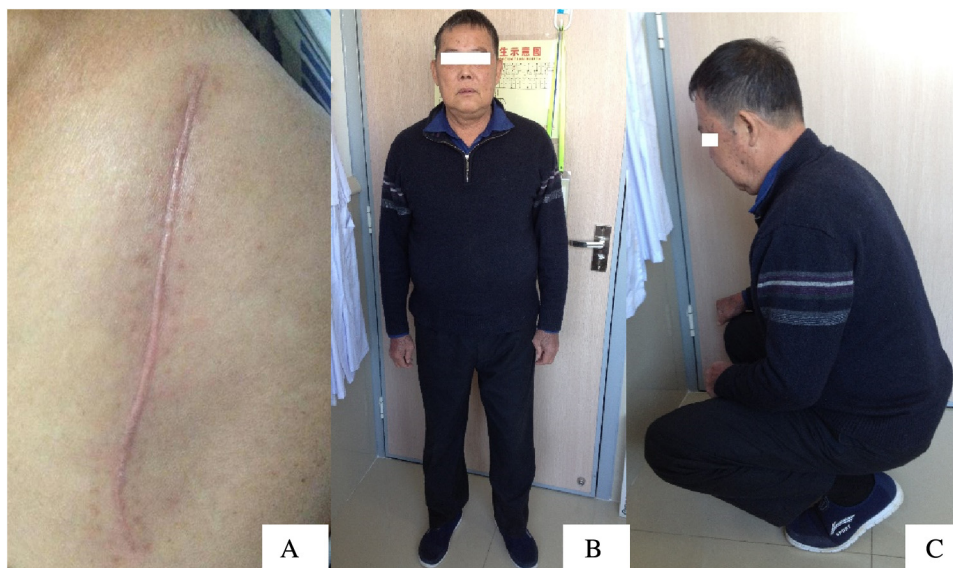


Fig. 5. left hip surgical scar healed well (5A) and hip joint function (5B, 5C) at 1 year' follow up.

surgery are likely to misdiagnosed as a simple infection due to lack of experience. Antibiotics, surgical debridement, vacuum aspiration and skin-grafting treatment were given which may delay treatment, extended treatment time and costs, and even lead to secondary infection. Dozens of cases at home and abroad like this [2,5–7]. Pyoderma gangrenosum is frequently associated with underlying systemic disorders, such as ulcerative colitis, Crohn's disease, leukaemia, rheumatoid arthritis. For the first time, we observed the comorbidity of pyoderma gangrenosum and bilateral necrosis of the femoral heads, which needs further research.

Infection is a catastrophic complication of arthroplasty. For the pyoderma gangrenosum patients who need arthroplasty to improve the joint function, preventing complications is a key factor of successful treatment.

There is not any generally acknowledged treatment for pyoderma gangrenosum, corticosteroid and immunosuppressant, such as cyclosporine and tacrolimus, play an important role to improve prognosis. Being rare, no treatment is standard as defined by prospective randomized studies. Moreover, Researches related to the diagnosis and treatment of arthroplasty with pyoderma gangrenosum are insufficient and standardized treatment in perioperative period is not reported yet.

No consensus has been reached about whether to use corticosteroid, as well as the dosage and administration, in perioperative periods for these patients as prophylactic means of wound complication. We report this case in order to share perioperative period experiences about pyoderma gangrenosum patients who undergo total hip arthroplasty, and provide reference to standardize the treatment for this disease alike in the future. However, the follow-up survey of this case is short (1 year), long-term following up is needed in the future.

4. Conclusion

We herein report a case of pyoderma gangrenosum patient underwent total hip arthroplasty, meanwhile raise the issue of management in perioperative period for pyoderma gangrenosum patient, especially explore series of standardized therapies for this disease during arthroplasty.

Conflict of interest

The authors declare that they have no conflicts of interest.

Funding

The authors have no sources of funding.

Ethical approval

None.

Consent

Written informed consent was obtained from the patient for publication of this case report and any accompanying images. A copy of the written consent is available for review by the Editor-in-Chief of this journal.

Author contribution

Guo Rong She and Jun Yuan Chen contributed equally by examining the patient, following up the patient, writing up the manuscript. Zi Qi Zhou revised the literature. Zhen Gang Zha and Ning Liu were the surgeons assigned to the case. All authors read and approve the final manuscript.

Guarantor

Zhen Gang Zha.

References

- [1] L.A. Brunsting, W.H. Goekerman, P.A. O'Leary, Pyoderma gangrenosum: clinical and experimental observation of five cases occurring in adults, *Arch. Dermatol. Syphilol* 22 (1930) 655–680.
- [2] E. de Thomasson, I. Caux, Pyoderma gangrenosum following an orthopedic surgical procedure, *Orthop. Traumatol. Surg. Res.* 96 (2010) 600–602.
- [3] F. Wadia, M.H. Malik, M.L. Porter, Postoperative wound breakdown caused by pyoderma gangrenosum after bilateral simultaneous total knee arthroplasty, *J. Arthroplast.* 22 (2007) 1232–1235.

- [4] R.A. Agha, A.J. Fowler, A. Saetta, I. Barai, S. Rajmohan, D.P. Orgill, for the SCARE Group, The SCARE statement: consensus-based surgical case report guidelines, *Int. J. Surg.* (2016) (in press).
- [5] P.M. Armstrong, I. Ilyas, R. Pandey, et al., Pyoderma gangrenosum. A diagnosis not to be missed, *J. Bone Joint Surg. (Br.)* 81 (1999) 893–894.
- [6] C. Kühn, C. Vente, J. Dörner, et al., Pyoderma gangrenosum: and important differential diagnosis from wound infection Case report of a life threatening course, *Anaesthesist* 49 (2000) 829–833.
- [7] C. Suarez, E. Mercier, P. Piquet, et al., Comments on: pyoderma gangrenosum following an orthopedic surgical procedure by E. de Thomasson, and I. Caux, published in *orthop traumatol surg res* 2010; 96:600–602, *Orthop. Traumatol. Surg. Res.* 97 (2011) 890–891.

Open Access

This article is published Open Access at sciedirect.com. It is distributed under the [IJSCR Supplemental terms and conditions](#), which permits unrestricted non commercial use, distribution, and reproduction in any medium, provided the original authors and source are credited.