

Nervus Intermedius Neuralgia Treated with Microvascular Decompression: A Case Report and Review of the Literature

Takuro Inoue,¹ Ayako Shima,¹ Hisao Hirai,¹ Fumio Suzuki,¹ and Masayuki Matsuda¹

Nervus intermedius neuralgia is one of the craniofacial neuralgias, which is extremely rare compared with trigeminal or glossopharyngeal neuralgia. Despite its unique symptom, the aetiology remains unclear. We present a case of a surgically treated 36-year-old woman who suffered from paroxysmal stabbing deep-ear pain for over 10 years. Preoperative magnetic resonance imaging demonstrated a vascular loop compressing the root entry zone of the vestibulocochlear nerve between the seventh and eighth cranial nerves, suggesting nervus intermedius neuralgia as a cause of her pain. Surgical exploration revealed that the nervus intermedius was displaced upward by the anterior inferior cerebellar artery. Transposition of the artery from the brainstem relieved the patient's neurological symptom immediately after the surgery, supporting the hypothesis that nervus intermedius neuralgia could be caused by neurovascular compression.

Keywords: nervus intermedius neuralgia, otalgia, microvascular decompression, neurovascular compression

Introduction

Nervus intermedius neuralgia is an extremely rare craniofacial neuralgia characterised by paroxysmal otalgia. In 1907 Hunt described otalgia as 'geniculate neuralgia,' believing an affection of the sensory fibre of the seventh cranial nerve to be its cause. Subsequently, Clark and Taylor concluded nervus intermedius neuralgia is the cause of deep-ear pain which is relieved by sectioning the nerve.¹⁾ The International Headache Society defines intermedius neuralgia as intermittent episodes of pain located deep in the ear that last for seconds or minutes and are often triggered by sensory or mechanical stimuli at the posterior wall of the auditory canal without any pathology. Although the aetiology of nervus intermedius neuralgia is not yet clear, some reports speculate vascular compression to be one of the causes.²⁻⁵⁾

Case Report

A 36-year-old woman with an unremarkable medical history presented with paroxysmal deep-ear pain of the left ear for more than 10 years. The paroxysmal pain occurred

several times a day, lasting up to 20 seconds per episode. Stimulation in the external auditory canal frequently triggered an episode. Although the severity of our patient's otalgia varied, some particularly severe episodes accompanied a radiating pain around the auricle and increased lacrimation. Gustation, however, was unaffected during her episodes of otalgia. She had no other medical complaints. Initial treatment with carbamazepine effectively reduced her otalgia; however, the pain became intolerable as the frequency and intensity of episodes increased. Neurological examination revealed nothing but the aforementioned pain. The territory of her pain was distinctly different from those of typical trigeminal neuralgia or glossopharyngeal neuralgia.

Neuroradiological examination was conducted according to our protocol for the patients with neurovascular compression (NVC) syndrome.⁶⁾ Magnetic resonance imaging (MRI) revealed neurovascular contact close to the brainstem at the complex of the seventh and eighth cranial nerves. Although the nervus intermedius was not identified on MRI, the widened space between the seventh and eighth nerves compared to the opposite side suggested the presence of NVC on the nervus intermedius together with the vestibulocochlear nerve. (Figs. 1A and 1B). No such vascular contact was found on the lower cranial nerves. Three-dimensional imaging clearly depicted the neurovascular contact around the root entry zone (REZ) of the vestibulocochlear nerve by the anterior inferior cerebellar artery (AICA) running between the seventh and eighth cranial nerves (Fig. 1C).

As our patient's severe pain disturbed her daily life despite carbamazepine therapy, microvascular decompression (MVD) was considered as the next step. Even though we explained her that the surgical treatment for this type of pain has not been established yet, she wanted to explore any possible cause. The operation was performed via retrosigmoid approach, which is similar fashion applied for hemifacial spasm or trigeminal neuralgia with the auditory evoked brainstem response (ABR) monitored. The nervus intermedius was observed being displaced upward and compressed together with the vestibulocochlear nerve by AICA (Fig. 2A). The facial nerve was not visible as AICA blocked the deeper operative view at this point. The proximal part of AICA coursed deep under the flocculus to the direction of the REZ of the vestibulocochlear nerve. No arterial compression was found on the lower cranial nerves (Fig. 2B). While dissecting and retracting the flocculus in order to observe the REZ of the eighth nerve, ABR was diminished in amplitude

¹Department of Neurosurgery, Subarukai Kotoh Kinen Hospital, Higashiohmi, Shiga, Japan

Received: October 21, 2016; Accepted: January 11, 2017
Online June 8, 2017

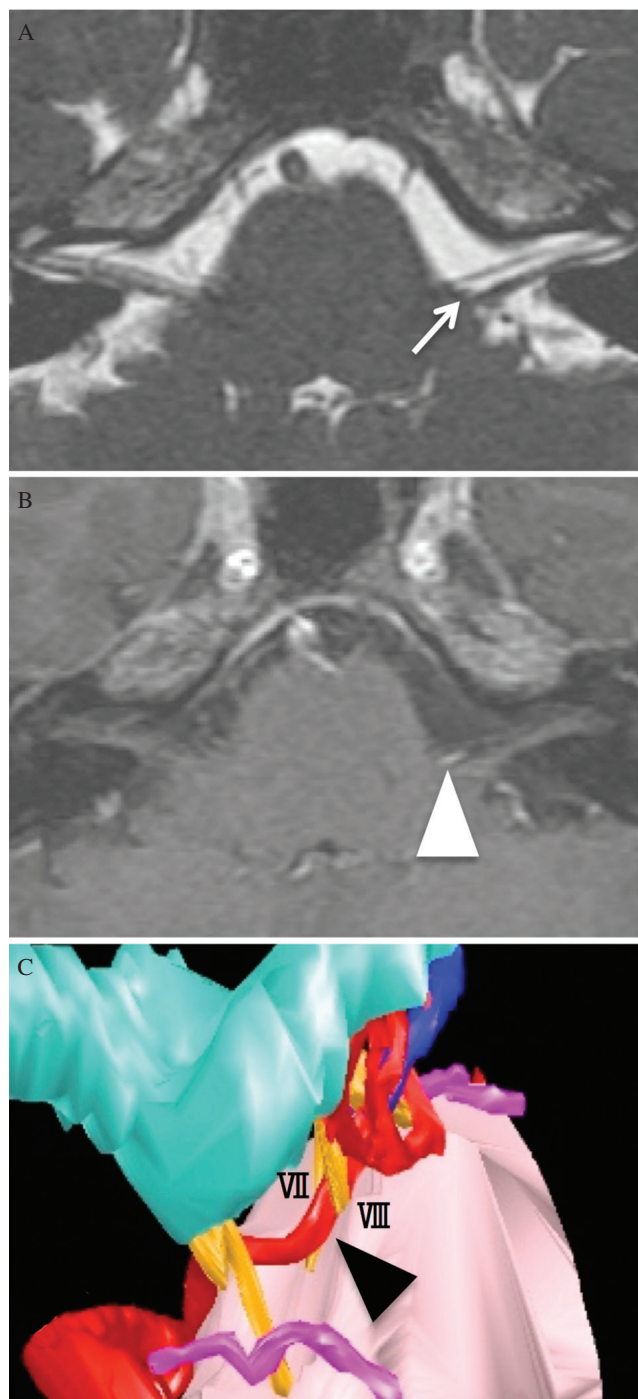


Fig. 1 Preoperative magnetic resonance imaging (MRI) and three-dimensional image constructed by GammaPlan®. (A) MRI (fast imaging employing steady-state acquisition) of the complex of the seventh and eighth cranial nerves shows the widened space between the seventh and the eighth nerves (white arrow) on the affected side. The nervus intermedius is invisible. (B) Contrast-enhanced MRI (T1-spoiled-gradient-recalled) revealed neurovascular contact at the root entry zone (REZ) of the vestibulocochlear nerve (white arrowhead), suggesting compression on the REZ of the nervus intermedius. (C) Three-dimensional image of the surgeon's view via the left retrosigmoid approach clearly demonstrates the anatomical relationship between the anterior inferior cerebellar artery (AICA, black arrowhead) and the complex of the seventh and eighth cranial nerves.

and the latency was prolonged. We could not proceed further in fear of causing hearing disturbance (Fig. 2C). However, judging from the preoperatively created three-dimensional picture, transposing the proximal part of the AICA could obtain enough decompression at the REZ of the nervus intermedius and the vestibulocochlear nerve. After the AICA was transposed to the petrous dural surface by use of Teflon® felt, the REZ of the facial nerve was finally visualized, suggesting the REZ of the nervus intermedius is also decompressed (Fig. 2D). As we believed that the AICA was successfully transposed from the REZ of both the seventh and eighth nerves, we did not attempt further dissection around the REZ in order to avoid complications, such as hearing disturbance and facial palsy. Immediately after the surgery, our patient's otalgia was relieved, and she was discharged 1 week after the operation without any complications. She had no recurrence of otalgia or excessive lacrimation of the left eye at the 30-month follow-up visit.

Discussion

Nervus intermedius neuralgia is well known for its characteristic symptom, paroxysmal lancinating deep-ear pain.^{7,8)} Episodes may be spontaneous or triggered by a stimulus at the posterior wall of the external ear canal. The pain is usually localised to the auditory canal and retroauricular region, but may radiate to the temporal region during particularly severe episodes. The pain is

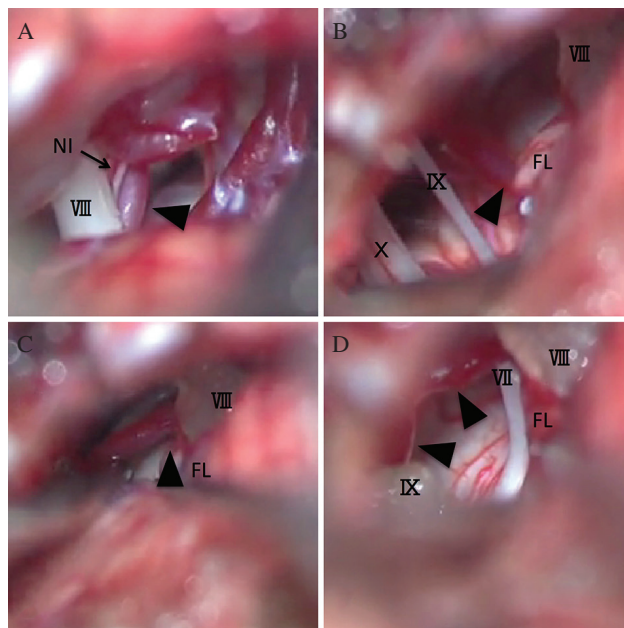


Fig. 2 Operative view via retrosigmoid approach on the left side. (A) The nervus intermedius (NI) is displaced upward by the distal part of the AICA (black arrowhead) together with the vestibulocochlear nerve (VIII). (B) The AICA (black arrowhead) courses under the flocculus (FL). The lower cranial nerves (IX, X) have no definitive vascular compression. (C) Before transposition of the AICA (black arrowhead). Gentle retraction of the flocculus (FL) revealed the proximal AICA entering the REZs of the seventh and the eighth cranial nerves. (D) After transposition of the AICA (black arrowhead) to the petrous dura by using Teflon® felt. The AICA is transposed away from the REZs of the seventh and the eighth cranial nerves. The REZ of the nervus intermedius is not exposed. Note the vestibulocochlear nerve (VIII) in B, C and D is covered by Surgicel®.

sometimes accompanied by disorders of lacrimation, salivation and gustation, as the nervus intermedius innervates into the greater superior petrosal nerve and chorda tympani nerve.⁹⁾ In contrast to its characteristic symptoms, however, it is extremely uncommon and difficult to specify the involvement of the nervus intermedius. Only about 150 cases have been reported since 1932.⁷⁾ In order to establish the diagnosis of nervus intermedius neuralgia, all other possible non-neuralgic causes of otalgia should first be excluded, such as otitis externa or media, tumors in the auditory canal, temporal bone or nasopharynx, and referred pain from nasopharyngeal or laryngeal lesions. Even after exclusion of these pathologies it is extremely difficult to specify the nerve involved in its symptoms, due to the presence of peripheral anastomotic connections of the tympanic plexus with other cranial nerves, such as the trigeminal, glossopharyngeal and cervical nerves. Therefore, trigeminal or glossopharyngeal neuralgia, especially Jacobson's neuralgia, should be included in differential diagnoses.^{5,10)}

The first-line therapy for this condition is pharmacological, typically comprising an anticonvulsant such as carbamazepine, gabapentin or lamotrigine.⁷⁾ For those who failed in comprehensive medical therapy, a variety of surgical treatments have been historically attempted, such as transection of the nervus intermedius or geniculate ganglion and MVD. Surgical treatments for nervus intermedius neuralgia are summarised in Table 1.^{1-5,9,11-17)} Transection of the nervus intermedius in combination with MVD for other cranial nerves was most commonly performed in the early days.^{1,12-17)} Yeh et al. first reported a case of a successful MVD for nervus intermedius neuralgia⁹⁾ and the following reports advocate the NVC can cause intermedius neuralgia.^{2,4,5,11)}

Table 1 Review of the literature on surgical treatments for nervus intermedius neuralgia

Author (s)	Year	Procedures	No. of cases
Clark & Taylor ¹⁾	1909	TS	1
Mckenzie ¹²⁾	1938	TS	1
Wilson ¹⁷⁾	1950	TS	1
Tsuru ¹⁶⁾	1962	TS	1
Sachs ¹⁵⁾	1968	TS	4
Pulec ¹³⁾	1976	TS	64
Yeh ⁹⁾	1984	MVD	[1]
Bellotti ²⁾	1988	MVD	[1]
Rupa ¹⁴⁾	1991	TS/MVD	9 / [9]
Lovely ³⁾	1997	TS	14
Sakas ⁴⁾	2007	MVD	[1]
Younes ⁵⁾	2010	MVD	[1]
Saers ¹¹⁾	2011	MVD	[1]
Present Case	2016	MVD	[1]
Total [MVD only]			110 [15]

MVD: microvascular decompression, TS: transection.

Unlike other common NVC syndromes, it is almost impossible to detect the NVC on MRI in nervus intermedius neuralgia, as the nerve is usually not detected on MRI because of its small diameter and its course along with the vestibular nerve. To the best of our knowledge, there is no report that depicts the nervus intermedius itself as a cause of NVC on the preoperative MRI. There are, however, a few reports of MVD with preoperative diagnosis based on the indirect radiological finding on MRI.^{4,8,11)} In their reports, the sole radiological finding for possible NVC on the nerve is the displacement of the eighth nerve by the AICA or the posterior inferior cerebellar artery which pass between the seventh and eighth nerves complex, suggesting the presence of NVC on the nervus intermedius.^{4,8,11)} In the present case, although the nervus intermedius itself was not identified on MRI, the three-dimensional images contributed to suggest the NVC on the nervus intermedius, as the arterial compression on the vestibulocochlear nerve was clearly depicted. During surgery, the picture of surgeon's view was of great help in estimating the course of the AICA covered by the flocculus and determining the appropriate direction of its transposition.

Rhoton et al. described comprehensive anatomy of the nervus intermedius in cadaveric specimens.¹⁸⁾ They found the nervus intermedius is a small single root in most cases and the bundle of up to four tiny rootlets in some specimens. It initially arises from the superior medial part of the REZ of the eighth nerve. It courses together with the superior vestibular nerve, then separates from it to incorporate into the seventh nerve. In approximately 20% of cases, however, it separates from the eighth nerve and joins the seventh nerve in the internal acoustic canal. In such cases, the nervus intermedius is not found in the cerebellopontine angle. Due to these anatomical characteristics, radiological visualization of the nerve is usually difficult. During MVD, exposing its REZ is challenging, as it locates just behind that of the vestibulocochlear nerve in the surgeon's view via retrosigmoid approach.

Unlike in the cases of hemifacial spasm and trigeminal neuralgia, however, pathogenic involvement of NVC is yet to be established in nervus intermedius neuralgia. Alfieri et al. reported an anatomical observation of the central myelin-peripheral myelin transition zone, or 'Obersteiner-Redlich zone (ORZ)' of the nervus intermedius.¹⁹⁾ They observed that the ORZ of the nervus intermedius is located closer to the brainstem than that of other cranial nerves, indicating the nervus intermedius is less likely to have NVC. The significance of NVC eliciting nervus intermedius neuralgia including its distinctive location is still controversial, and more evidence is required.

In conclusion, nervus intermedius neuralgia is not yet fully clarified due to its rarity and scarce radiological and surgical findings. Furthermore, direct exposure of the REZ of the nerve is challenging during surgery. MVD for nervus intermedius neuralgia should be limited to those who have failed in all other medical treatments.

Conflicts of Interest Disclosure

The authors have no personal financial or institutional interest to disclose. All authors who are members of The Japan Neurosurgical Society (JNS) have registered online COI Disclosure Statement Forms for JNS members.

References

- 1) Clark LP, Taylor AS: True tic douloureux of the sensory filaments of the facial nerve. I. Clinical report of a case in which cure was effected by physiological extirpation of the geniculate gan-glion. II. Report of surgical treatment. *JAMA* 53: 2144–2146, 1909
- 2) Bellotti C, Medina M, Oliveri G, Ettorre F, Barrale S, Sturiale C, Melcarne A: Neuralgia of the intermediate nerve combined with trigeminal neuralgia: case report. *Acta Neurochir (Wien)* 91: 142–143, 1988
- 3) Lovely TJ, Jannetta PJ: Surgical management of geniculate neuralgia. *Am J Otol* 18: 512–517, 1997
- 4) Sakas DE, Panourias IG, Stranjalis G, Stefanatou MP, Maratheftis N, Bontozoglou N: Paroxysmal otalgia due to compression of the intermediate nerve: a distinct syndrome of neurovascular conflict confirmed by neuroimaging. Case report. *J Neurosurg* 107: 1228–1230, 2007
- 5) Younes WM, Capelle HH, Krauss JK: Microvascular decompression of the anterior inferior cerebellar artery for intermediate nerve neuralgia. *Stereotact Funct Neurosurg* 88: 193–195, 2010
- 6) Inoue T, Hirai H, Shimizu T, Tsuji M, Shima A, Suzuki F, Matsuda M: Ocular neuromyotonia treated by microvascular decompression: usefulness of preoperative 3D imaging: case report. *J Neurosurg* 117: 1166–1169, 2012
- 7) Tang IP, Freeman SR, Kontorinis G, Tang MY, Rutherford SA, King AT, Lloyd SK: Geniculate neuralgia: a systematic review. *J Laryngol Otol* 128: 394–399, 2014
- 8) Tubbs RS, Steck DT, Mortazavi MM, Cohen-Gadol AA: The nervus intermedius: a review of its anatomy, function, pathology, and role in neurosurgery. *World Neurosurg* 79: 763–767, 2013
- 9) Yeh HS, Tew JM: Tic convulsif, the combination of geniculate neuralgia and hemifacial spasm relieved by vascular decompression. *Neurology* 34: 682–683, 1984
- 10) Singh PM, Kaur M, Trikha A: An uncommonly common: Glossopharyngeal neuralgia. *Ann Indian Acad Neurol* 16: 1–8, 2013
- 11) Saers SJ, Han KS, de Ru JA: Microvascular decompression may be an effective treatment for nervus intermedius neuralgia. *J Laryngol Otol* 125: 520–522, 2011
- 12) Mckenzie KG: Discussion of paper presented by W.S. Keith on “Glossopharyngeal neuralgia: Recurrence after intracranial section of nerve”. *Zentralbl. Neurochir* 38: 371, 1938
- 13) Pulec JL: Geniculate neuralgia: long-term results of surgical treatment. *Ear Nose Throat J* 81: 30–33, 2002
- 14) Rupa V, Saunders RL, Weider DJ: Geniculate neuralgia: the surgical management of primary otalgia. *J Neurosurg* 75: 505–511, 1991
- 15) Sachs E: The role of the nervus intermedius in facial neuralgia. Report of four cases with observations on the pathways for taste, lacrimation, and pain in the face. *J Neurosurg* 28: 54–60, 1968
- 16) Tsuru M, Takamura H: [A case of intermedius neuralgia]. *No To Shinkei* 14: 129–133, 1962 (Japanese)
- 17) Wilson AA: Geniculate neuralgia; report of a case relieved by intracranial section of the nerve of Wrisberg. *J Neurosurg* 7: 473–481, 1950
- 18) Rhoton AL, Kobayashi S, Hollinshead WH: Nervus intermedius. *J Neurosurg* 29: 609–618, 1968
- 19) Alfieri A, Fleischhammer J, Strauss C, Peschke E: The central myelin-peripheral myelin transitional zone of the nervus intermedius and its implications for microsurgery in the cerebellopontine angle. *Clin Anat* 25: 882–888, 2012

Corresponding author:

Takuro Inoue, MD, PhD, Department of Neurosurgery, Subarukai Kotoh Kinen Hospital, 2-1 Hiramatsu-cho, Higashiohmi, Shiga 527-0134, Japan.

✉ takuro39@gmail.com