



Case report

The tipping point: Tamoxifen toxicity, central serous chorioretinopathy, and the role of estrogen and its receptors



Nicole Koullis^{a, b}, Stavros N. Moysidis^a, Lisa C. Olmos de Koo^a, Christy A. Russell^c, Amir H. Kashani^{a, *}

^a USC Roski Eye Institute, Department of Ophthalmology, Keck School of Medicine, University of Southern California, Los Angeles, CA, United States

^b University of Massachusetts Medical School, Worcester, MA, United States

^c Department of Medicine-Oncology, Keck School of Medicine, University of Southern California, Los Angeles, CA, United States

ARTICLE INFO

Article history:

Received 14 January 2016

Received in revised form

9 May 2016

Accepted 16 May 2016

Available online 18 May 2016

Keywords:

Tamoxifen toxicity

Central serous chorioretinopathy

Diagnostic dilemma

Estrogen receptor

Optical coherence tomography (OCT)

Microperimetry

ABSTRACT

Purpose: To describe a case of tamoxifen toxicity superimposed on central serous chorioretinopathy (CSCR). We review the role of estrogen and the effect of tamoxifen on ocular tissues.

Observations: A 32-year-old Hispanic female with infiltrating ductal carcinoma of the left breast (T2N1M0, triple-positive), status post chemotherapy and bilateral mastectomy, presented with complaint of a floater and decreased central vision of the right eye (OD). Symptoms began three weeks after initiating tamoxifen and five months after the last cycle of chemotherapy and dexamethasone. Visual acuity (VA) was 20/30 OD at presentation. Clinical examination and multimodal imaging revealed subretinal fluid (SRF) and pigment epithelial detachment (PED) suggestive of CSCR. After one month of monitoring, VA improved to 20/20; there was SRF resolution, small PED, and focal ellipsoid zone (EZ) band loss. Two weeks later, after undergoing surgery and starting a topical steroid, she returned with count fingers (CF) VA and large SRF OD. Steroid cessation improved SRF after one month, but VA was unchanged. Tamoxifen was discontinued, and VA improved to 20/100 with near-complete resolution of SRF at three weeks, and significant reduction in choroidal thickness at two months. At final follow-up, VA was 20/200, and there was focal EZ band loss sub-foveally, minimal SRF, and small PED.

Conclusions and Importance: Treatment with tamoxifen may lead to ocular toxicity and can complicate the recovery course of patients affected with CSCR. Variations in levels of the estrogen receptor-alpha (ER- α) and treatment with tamoxifen (ER- α partial agonist) may lead to loss of the protective effect of estrogen in the retinal pigment epithelial cells in premenopausal women. Furthermore, tamoxifen toxicity can lead to focal photoreceptor loss. Treatment in these cases should be coordinated together with the oncologist.

© 2016 The Authors. Published by Elsevier Inc. This is an open access article under the CC BY-NC-ND license (<http://creativecommons.org/licenses/by-nc-nd/4.0/>).

1. Introduction

Tamoxifen is an important, potentially life-saving medicine used in the treatment of patients with hormone-receptor positive breast cancer.^[1] It is a selective estrogen receptor modulator that is usually well tolerated. Common systemic side effects include nausea, vomiting, rash, hot flashes, and mood changes, but more severe systemic and ocular side effects are rare. When ocular toxicity results, vision loss can be greatly disturbing to the patient, and may

result from crystalline retinopathy, macular edema, or optic neuritis amongst other toxicities.^[2] Advances in ophthalmic imaging modalities have allowed for greater characterization and understanding of this toxicity. Here we describe a case of tamoxifen toxicity with a novel presentation, which posed a clinical dilemma.

2. Case Report

A 32-year-old Hispanic, premenopausal female with history of infiltrating ductal carcinoma of the left breast (T2N1M0, ER/PR/HER2 positive), status post chemotherapy, bilateral mastectomy, and reconstruction surgery, presented with complaint of a floater and decreased central vision of the right eye (OD), which started the prior evening. She characterized the deficit as a small, dark area

* Corresponding author. USC Roski Eye Institute, 1450 San Pablo Street, 4th floor, Los Angeles, CA, 90033, United States.

E-mail address: ahkashan@med.usc.edu (A.H. Kashani).

involving only the center of her vision. She denied flashes of light, diplopia, ocular pain, and other ocular symptoms. She noted no changes in her left eye. She reported no previous ocular problems or trauma. She denied fever, chills, headaches, nausea, vomiting, rashes, tinnitus, and joint pain. She provided written consent to include her medical information in this report.

Five months prior, the patient had completed six cycles over fifteen weeks of neoadjuvant chemotherapy with docetaxel (125 mg), carboplatin (900 mg), trastuzumab (540 mg), and pertuzumab (840 mg) administered intravenously at each cycle. Included in this peri-chemotherapy regimen was daily dexamethasone (8 mg oral), monthly leuprolide (7.5 mg intramuscular), and pegfilgrastim (6 mg subcutaneous) injected once per chemotherapy cycle. She suffered one episode of neutropenic fever, but otherwise her course was well tolerated. Next, she underwent left modified radical mastectomy and right prophylactic mastectomy with immediate reconstruction bilaterally, and she declined radiation therapy. Her surgical history and past medical history were otherwise unremarkable; she denied obstructive sleep apnea and family history of ocular disease or cancer. She denied tobacco or drug use, and drank limited alcohol socially. She also denied the use of steroids, inhalers, and energy drinks within the past five months.

At the time of ophthalmic evaluation, five months had passed since her last cycle of chemotherapy and dexamethasone, and her only active medications were low-dose, oral tamoxifen (20 mg daily; initiated three weeks prior) and intravenous trastuzumab (540 mg every three weeks; initiated eight months prior). Best-corrected visual acuity (BCVA) was 20/30 OD and 20/25 in the left eye (OS). Intraocular pressure was 19 in both eyes (OU). Pupils were round and reactive with no afferent pupillary defect. Extraocular movements were full OU. Confrontation visual fields were full. Amsler grid was normal, and Ishihara color plates were 8 of 8 in each eye. Slit lamp and dilated fundus exam were normal, except for vitreous syneresis OU and macular edema OD (Fig. 1A&D; Optos, Marlborough, MA).

Spectral domain optical coherence tomography (SD-OCT; Cirrus 5000, Carl Zeiss Meditec, Inc., Dublin, CA) revealed a large amount of subretinal fluid (SRF) and detachment of the neurosensory retina, resulting in disruption of the foveal contour and two underlying retinal pigment epithelial detachments (PED) OD. Also

noted were few, small, hyperreflective foci in the outer plexiform layer (OPL; Fig. 1B–C). SD-OCT macula OS was normal (Fig. 1E–F). Fluorescein angiography revealed small foci of hyperfluorescence inferior to the fovea, which began early during the arterial phase and increased slightly in intensity and size on later phases, localizing to the PED, consistent with an expansile dot pattern (Fig. 2; Optos). She was counseled that she had clinical findings suggestive of central serous chorioretinopathy. We recommended steroid avoidance, stress reduction if possible, and decided to monitor closely.

She returned one month later with subjective improvement in vision, as well as improvement in BCVA to 20/20 OU. We noted marked reduction of SRF with a small PED remaining, and focal, granular hyperreflectivity and loss of the EZ band subfoveally, above the PED OD (Fig. 3A; Spectralis, Heidelberg, Germany). We opted to continue to monitor. As she continued to do well, she cancelled her follow-up appointment. During that time, she underwent revision of her reconstructive breast surgery and concurrently developed a rash above her eyebrows, which she self-treated with an over-the-counter, topical hydrocortisone 1% cream.

She presented two weeks later with sudden and severe worsening of her vision to count fingers OD and with extensive SRF OD, more severe than on initial presentation (Figs. 3B and 4A; Spectralis). Autofluorescence OS was normal (Fig. 4B). Her choroidal thickness OD and OS measured an average of $443 \pm 44.3 \mu\text{m}$ ($491 \mu\text{m}$ subfoveally) and $405 \pm 43.1 \mu\text{m}$ ($432 \mu\text{m}$ subfoveally), respectively (Fig. 5A–B). We counseled her to stop the hydrocortisone cream, discussed various treatment options, and after discussion of the risks and benefits, we decided to monitor closely and follow-up in one month. At this next visit, after cessation of topical steroid, her vision had not improved despite a reduction in SRF. Given these findings, after discussion with her oncologist, we asked her to discontinue the tamoxifen, five months after its initiation.

Three weeks later, vision improved to 20/200 OD with near-complete resolution of SRF but with persistent PED and focal loss of the EZ band subfoveally on OCT (Fig. 3C). One month later, we noted a statistically significant reduction in choroidal thickness OD ($p < 0.01$; compare Fig. 5A and C), with no difference in OS ($p = 0.35$; compare Fig. 5B and D; DRI OCT-1, Topcon Medical Systems, Oakland, NJ). Four months after cessation of tamoxifen,

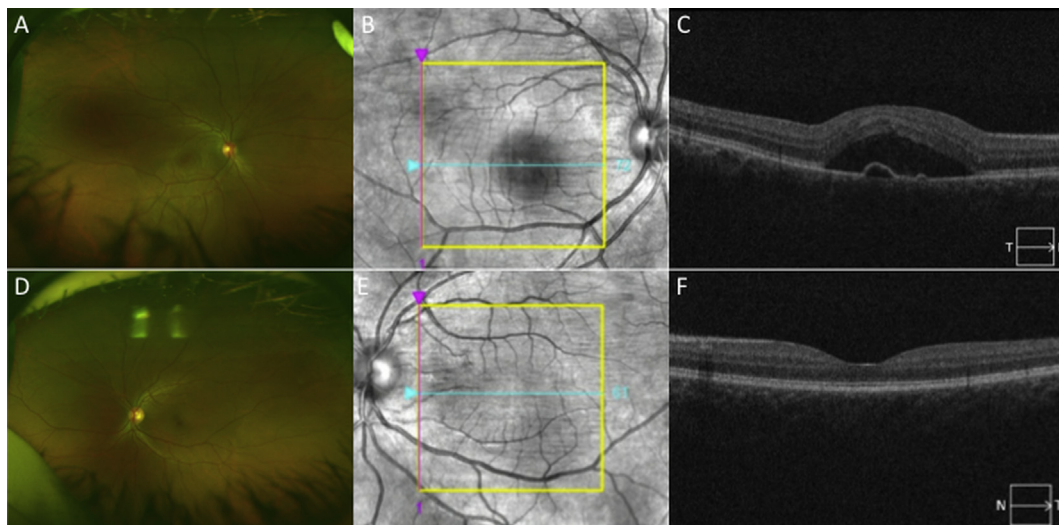


Fig. 1. A. Wide-field color photograph revealing normal appearance of the optic nerve, vessels, and periphery, but significant edema in the macula OD. B–C. Fundus overlay and spectral domain optical coherence tomography (SD-OCT) of the macula OD revealing an enlarged foveal avascular zone corresponding to a large amount of subretinal fluid (SRF) with disruption of the foveal contour and a retinal pigment epithelial detachment. There are foci of hyperreflectivity within the outer plexiform layer. D. Wide-field color photograph revealing normal appearance of the optic nerve, macula, vessels, and periphery OS. E–F. Fundus overlay and SD-OCT of the macula OS, which is normal in appearance.

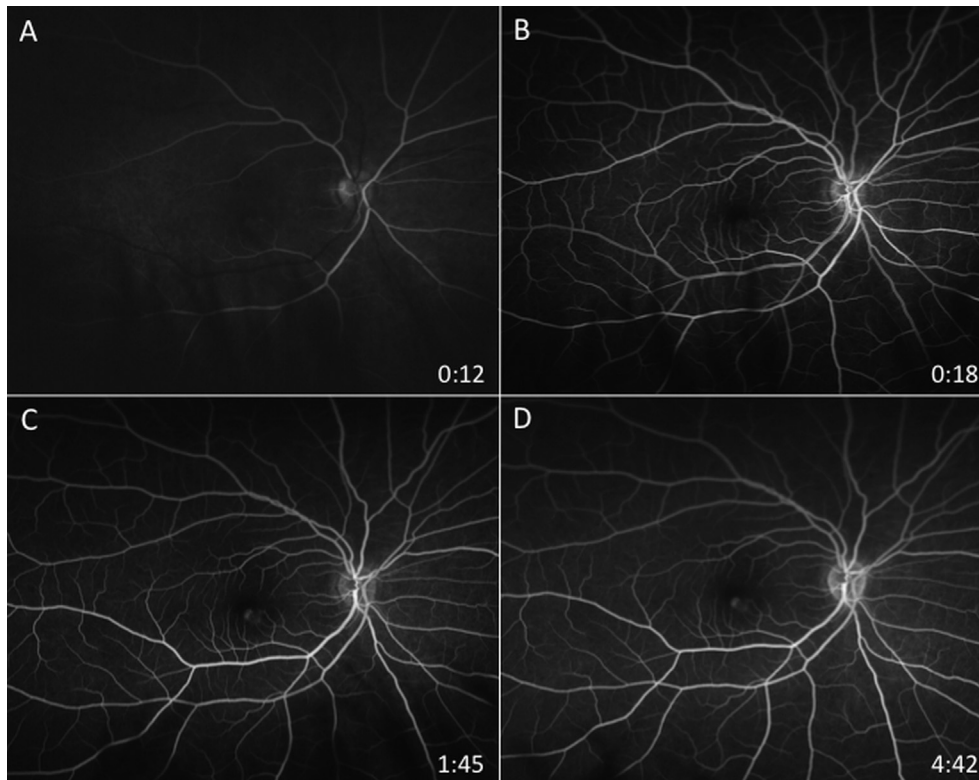


Fig. 2. A–D. Fluorescein angiography OD, revealing small foci of hyperfluorescence, which is subtle in appearance early during the arterial phase and increases mildly in size and intensity through the late phases, consistent with an expansile dot pattern.

BCVA was 20/100 OD with a persistent central scotoma OD on microperimetry (MP-1, Nidek Technologies, Italy; Fig. 6A–B), and clinical exam and OCT findings remained stable. At sixteen-month follow-up, BCVA remained stable at 20/200.

3. Discussion

The ATLAS trial demonstrated that ten years of tamoxifen therapy is more beneficial than the current five-year standard of therapy for hormone-receptor positive breast cancer.^[1] Meanwhile, the incidence of tamoxifen ocular toxicity is estimated to be between 0.9% and 12%.^[3] It is likely that certain patients will be treated with tamoxifen for longer periods.^[1] It is not known whether this will be accompanied by an increase in the number of cases of drug-related ocular toxicity.

Ocular manifestations of tamoxifen toxicity include but are not limited to crystalline retinopathy, optic neuropathy, macular edema, pseudocystic foveal cavitation, and corneal deposits.^[2,4] When ocular toxicity occurs, the treatment is to stop tamoxifen. There have not been reports of an efficacious antidote, though corticosteroid use for tamoxifen-induced optic neuropathy has been attempted with only transient improvement in visual acuity.^[5] OCT findings have included crystalline deposits in the inner retina, EZ band loss, thinning of the inner retina and cystic foveal cavitation, corresponding to hyperfluorescence on FA, without leakage.^[4] Toxicity to the retina has been irreversible even after cessation.^[2] While ocular toxicity has occurred with high dose therapy (≥ 180 mg daily; cumulative dose >100 g)^[6], it has also occurred at low dose (20 mg daily), after as little as 0.42 g cumulative dose, within three weeks of initiating therapy.^[5]

Our patient presented with ocular findings three weeks after initiating tamoxifen (cumulative dose 0.42 g). Her clinical exam,

OCT, and FA findings including SRF with PED and expansile dot pattern were consistent with the typical angiographic and clinical signs of CSCR; however, the extent of her vision loss and poor final visual acuity may have been related to her tamoxifen treatment rendering her retinal pigment epithelium (RPE) more susceptible to damage from a CSCR episode. She did not have the typical risk factors for CSCR, except for stress at work and bilaterally enlarged, choroidal thickness, and she denied recent steroid use, energy drinks, or history of OSA. Furthermore, she had completed a fifteen-week course of oral steroids five months prior to presentation without symptoms. Nevertheless, within three weeks of initiating tamoxifen, the patient presented to clinic, and three weeks after tamoxifen cessation (cumulative dose 3.08 g), the patient had her greatest improvement. Her vision improved from CF to 20/100, SRF improved substantially, and choroidal thickness OD improved significantly. While tamoxifen cessation coincided with improvement, the natural history of CSCR alone could have been responsible for the fluid resolution. Nevertheless, the patient's worse than expected visual outcome and severe disruption of the EZ band subfoveally may have been due to superimposed, tamoxifen-induced RPE damage. Perhaps, she suffered “two hits” – one from CSCR and one from tamoxifen, damaging the RPE and leading to her devastating sequelae.

Tamoxifen is a partial agonist, which activates the estrogen receptor- α (ER- α) with lower efficacy compared to estrogen, its natural ligand. When tamoxifen binds ER- α , it produces a net decrease in ER- α activation compared to the response observed when estrogen is bound. There are two ER subtypes (ER- α and ER- β), and when ligand bound, the ERs act as hormone-inducible transcription factors capable of translocation into the nucleus for the modulation of gene expression.^[7,8] Both subtypes are expressed in the human retina and RPE.^[9–11] Human ER- α is also detected in

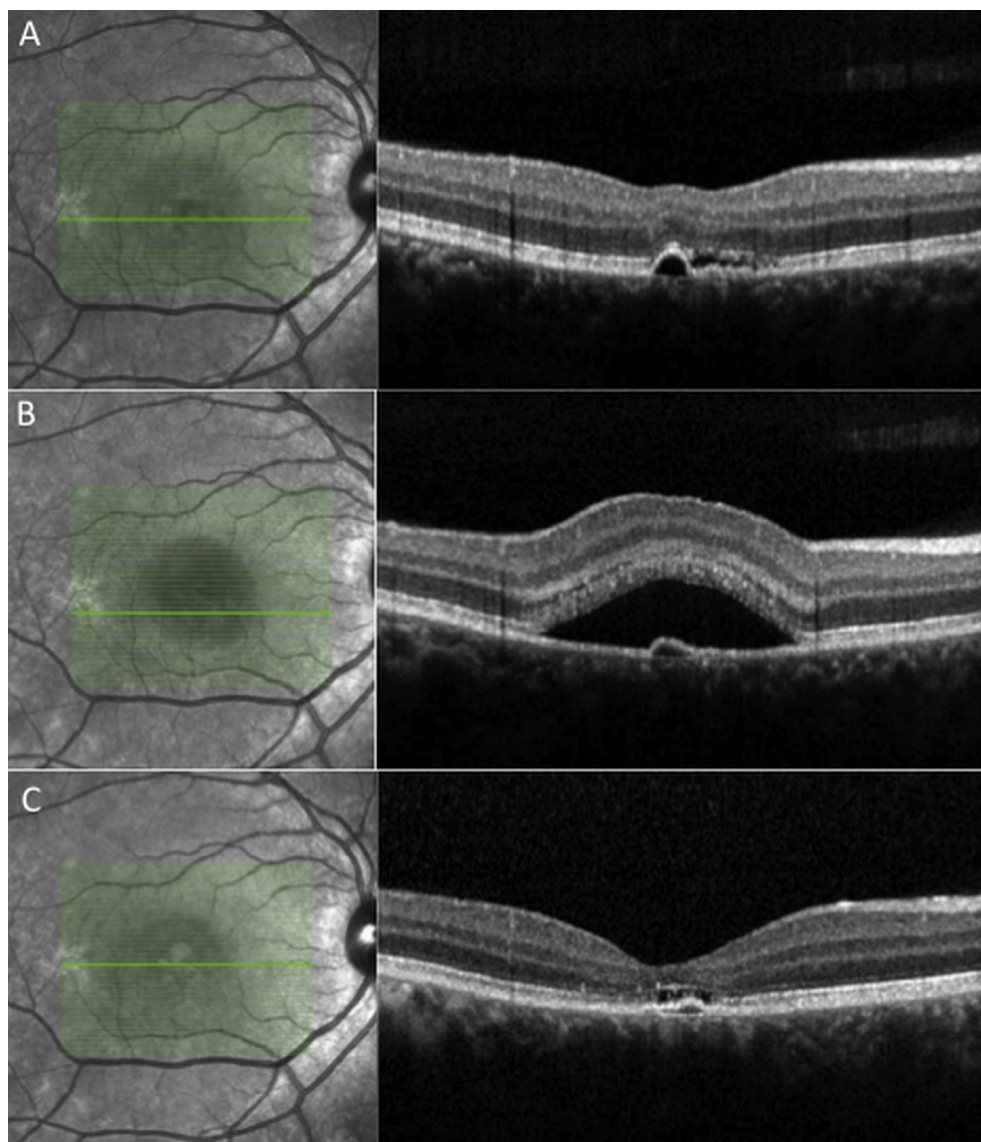


Fig. 3. A. Spectral domain optical coherence tomography (SD-OCT) of the macula OD demonstrating near-complete resolution of subretinal fluid (SRF) with a small pigment epithelial detachment (PED) remaining, one month after initial presentation. B. SD-OCT of the macula OD, two months later and after the self-administration of topical hydrocortisone cream, revealing large amount of SRF, worse than initial presentation, with underlying PED, and multiple, small hyperreflective foci in the outer plexiform and outer nuclear layers. C. SD-OCT of the macula OD, two months after the cessation of tamoxifen, revealing near-complete resolution of SRF. There is ellipsoid zone band loss and granularity subfoveally with a small remaining PED.

the non-pigmented ciliary body, the iris, the stroma, and the lens epithelium.^[10] While studies suggest a predominance of ER- β over ER- α , especially in the ganglion cell layer and choroid, ER- α expression varies considerably with gender and age, with highest amounts present in young, premenopausal women and little to none present in men and postmenopausal women.^[9,10,12] Interestingly, those with the most reduced ER- α levels are the ones with an increased incidence of CSCR: males (6:1) and postmenopausal women.^[13,14] Perhaps, a reduced expression of ER- α relative to ER- β in these patients plays a role in the epidemiology of CSCR. In the case of our patient, the use of tamoxifen may have resulted in a decrease in the protective effects of estrogen and ER- α in the choroid and RPE.

Extensive work has demonstrated the protective effects of estrogen in ocular tissues. Estrogen deficiency is linked to the development of dry eyes and age-related macular degeneration (AMD) in women.^[15–18] Conversely, hormone replacement therapy

in postmenopausal women is linked by some researchers to a decreased risk of glaucoma, central retinal vein occlusion, idiopathic macular hole, cataract, and AMD^[19–24], although the latter is disputed.^[9,25,26] At the cellular and mitochondrial level, estrogen protects the human RPE from *in vitro* oxidative stress in an ER-dependent fashion, with 17- β estradiol (an ER- β ligand) affording greater protection than 17- α estradiol (a weak ER- α ligand) in a male-derived cell line.^[11] It is not known whether 17- α estradiol would have a more protective effect in a cell line with greater ER- α expression, for example in a premenopausal, female-derived RPE cell line.

Tamoxifen *in vitro* causes structural changes to the human RPE cytoskeleton^[27], and is toxic to the human RPE and photoreceptors.^[28,29] This toxicity is driven by caspase-dependent and caspase-independent cell death pathways; the effect is dose-dependent, causing rapid cell death at high concentrations, but even at lower concentrations, it demonstrates cumulative insult to

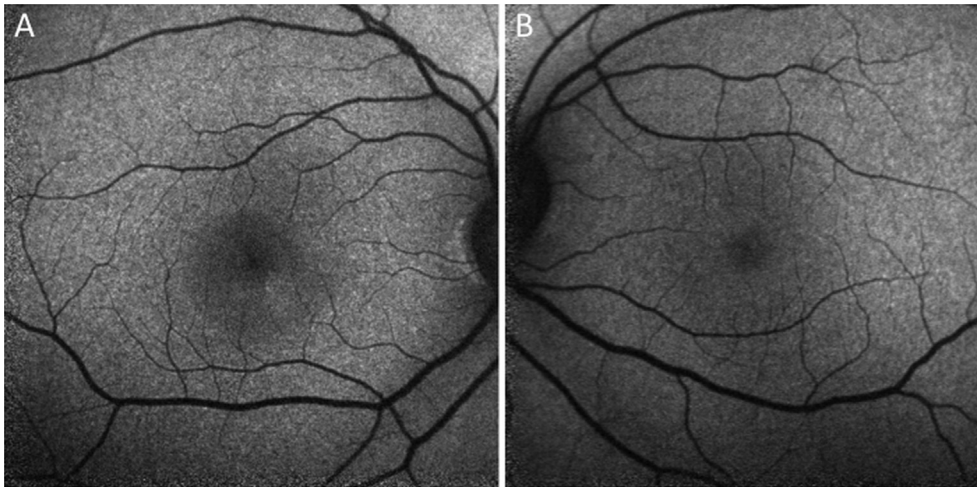


Fig. 4. A. Fundus autofluorescence OD revealing subtle hyperautofluorescence inferior to the fovea. B. Fundus autofluorescence OS which is normal in appearance.

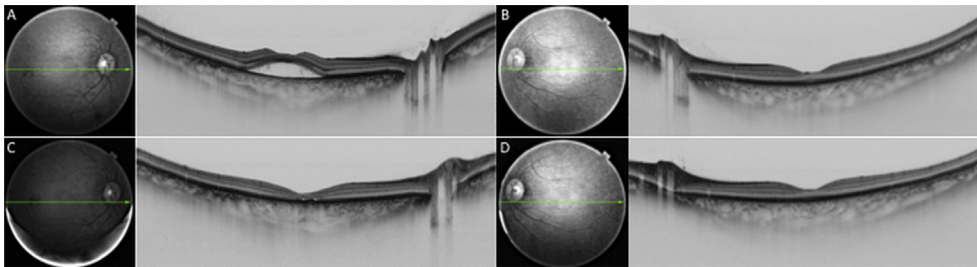


Fig. 5. A. Swept source optical coherence tomography (SS-OCT) OD with choroidal thickness measuring an average of $443 \pm 44.3 \mu\text{m}$ and $491 \mu\text{m}$ subfoveally OD. B. SS-OCT OS with choroidal thickness measuring an average of $405 \pm 43.1 \mu\text{m}$ and $432 \mu\text{m}$ subfoveally OS. C. SS-OCT OD, two months after cessation of tamoxifen, with choroidal thickness measuring an average of $414 \pm 46.4 \mu\text{m}$ and $451 \mu\text{m}$ subfoveally OD. There was a statistically significant decrease in choroidal thickness OD two months after cessation of tamoxifen ($p = 0.0098$). D. SS-OCT OS, two months after cessation of tamoxifen, with choroidal thickness measuring an average of $415 \pm 38.9 \mu\text{m}$ and $422 \mu\text{m}$. There was no significant difference in choroidal thickness OS before and two months after cessation of tamoxifen ($p = 0.35$).

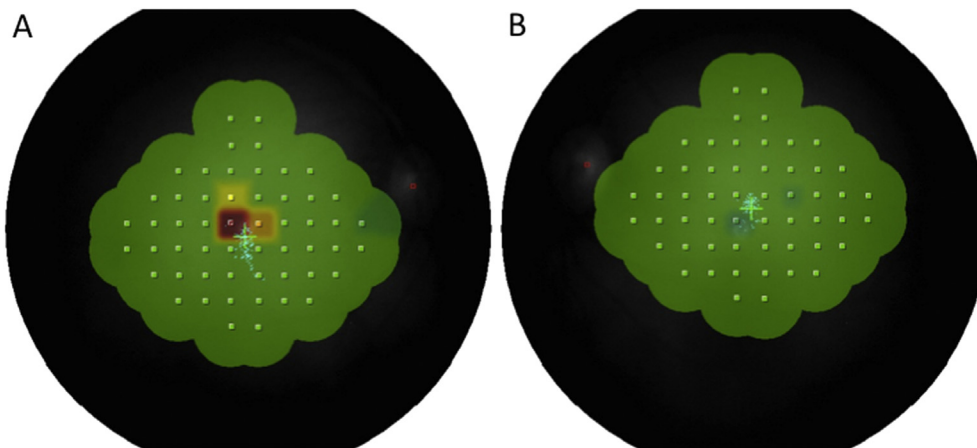


Fig. 6. A. Microperimetry four months after discontinuation of tamoxifen revealed a central scotoma OD. VA remained 20/200. B. Microperimetry OS was normal with VA of 20/20.

the RPE at two weeks.^[29] In the case of our patient, her RPE detachment occurred within three weeks of initiating low-dose tamoxifen. After the cessation of tamoxifen, within three weeks, there was improvement of the SRF and PED, and significant reduction of choroidal thickness OD from $443 \pm 44.3 \mu\text{m}$ ($491 \mu\text{m}$ subfoveally) to $414 \pm 46.4 \mu\text{m}$ ($451 \mu\text{m}$ subfoveally; $p < 0.01$). These findings may represent a restoration of the protective effects of estrogen on ER- α after the cessation of tamoxifen.

Our patient was treated with docetaxel, carboplatin, pertuzumab, leuprolide, pegfilgrastim, and dexamethasone during the course of her chemotherapy, and treatment with these agents had been completed five months prior to her presentation, making it lower in likelihood that they were acutely responsible for her presentation. Severe ocular toxicity has been reported with these agents, but such a delayed onset of toxicity has not been reported. Although the patient had received eight months of trastuzumab

therapy at the time of presentation, ocular toxicity from this is unlikely. Only one case of trastuzumab toxicity has been reported.^[30] The patient presented with bilateral visual acuity loss, hemorrhage and hard exudates on funduscopy, and bilateral cystic macular edema, and subretinal fluid on SD-OCT, which began three months after initiating trastuzumab.

Our patient's clinical presentation posed a diagnostic and therapeutic dilemma. The initiation of tamoxifen may have represented a hormonal tipping point in a patient who had previously undergone chemotherapy and treatment with steroids, and who had a predisposition for CSCR. Since our patient was previously on steroids during her course of chemotherapy and did not have any visual symptoms, tamoxifen may have increased the risk of CSCR in our premenopausal patient. This may represent a "two-hit" mechanism involving toxicity to the RPE. Whether this involves two separate molecular pathways or overlapping pathways is not clear. Based on the sudden and irreversible vision loss in this case, it is reasonable to counsel patients to closely self-monitor for changes in their vision with Amsler grid while taking both steroids and tamoxifen. We recommend prompt evaluation by an ophthalmologist in those patients on tamoxifen who report floaters, scotoma, or decreased vision. Treatment in these patients should be coordinated together with the patient's oncologist.

Funding

Supported by an unrestricted grant from Research to Prevent Blindness, New York, NY 10022.

Conflict of Interest

None of the authors have any relevant financial/conflicting interests to disclose.

Acknowledgements

We thank Research to Prevent Blindness, New York, NY 10022, for an unrestricted departmental grant.

References

- [1] C. Davies, H. Pan, J. Godwin, et al., G. Adjuvant Tamoxifen: Longer against Shorter Collaborative, Long-term effects of continuing adjuvant tamoxifen to 10 years versus stopping at 5 years after diagnosis of oestrogen receptor-positive breast cancer: atlas, a randomised trial, *Lancet* 381 (2013) 805–816.
- [2] A.G. Nair, D. Das, A. Goyal, R.A. Gandhi, The eyes have it! Tamoxifen maculopathy revisited: a case report, *J Ocul Pharmacol Ther* 28 (2012) 640–642.
- [3] A. Alwitry, I. Gardner, Tamoxifen maculopathy, *Arch Ophthalmol* 120 (2002) 1402.
- [4] R.R. Doshi, J.A. Fortun, B.T. Kim, S.R. Dubovy, P.J. Rosenfeld, Pseudocystic foveal cavitation in tamoxifen retinopathy, *Am J Ophthalmol* 157 (2014) 1291–1298 e3.
- [5] J. Zvornicanin, O. Sinanovic, S. Zukic, V. Jusufovic, A. Burina, Tamoxifen associated bilateral optic neuropathy, *Acta Neurol Belg* 115 (2015) 173–175.
- [6] S.G. Nayfield, M.B. Gorin, Tamoxifen-associated eye disease. A review, *J Clin Oncol* 14 (1996) 1018–1026.
- [7] V. Kumar, S. Green, G. Stack, M. Berry, J.R. Jin, P. Chambon, Functional domains of the human estrogen receptor, *Cell* 51 (1987) 941–951.
- [8] K. Dahlman-Wright, V. Cavailles, S.A. Fuqua, et al., International union of pharmacology. Lxiv. Estrogen receptors, *Pharmacol Rev* 58 (2006) 773–781.
- [9] C. Munaut, V. Lambert, A. Noel, et al., Presence of estrogen receptor type beta in human retina, *Br J Ophthalmol* 85 (2001) 877–882.
- [10] S.B. Ogueta, S.D. Schwartz, C.K. Yamashita, D.B. Farber, Estrogen receptor in the human eye: influence of gender and age on gene expression, *Investig Ophthalmol Vis Sci* 40 (1999) 1906–1911.
- [11] A. Giddabasappa, M. Bauler, M. Yepuru, E. Chaum, J.T. Dalton, J. Eswaraka, 17-beta estradiol protects arpe-19 cells from oxidative stress through estrogen receptor-beta, *Investig Ophthalmol Vis Sci* 51 (2010) 5278–5287.
- [12] K. Kobayashi, H. Kobayashi, M. Ueda, Y. Honda, Estrogen receptor expression in bovine and rat retinas, *Investig Ophthalmol Vis Sci* 39 (1998) 2105–2110.
- [13] A.S. Kitzmann, J.S. Pulido, N.N. Diehl, D.O. Hodge, J.P. Burke, The incidence of central serous chorioretinopathy in olmsted county, minnesota, 1980-2002, *Ophthalmology* 115 (2008) 169–173.
- [14] A. Daruich, A. Matet, A. Dirani, et al., Central serous chorioretinopathy: recent findings and new physiopathology hypothesis, *Prog Retin Eye Res* 48 (2015) 82–118.
- [15] M.N. Haan, R. Klein, B.E. Klein, et al., Hormone therapy and age-related macular degeneration: the women's health initiative sight exam study, *Arch Ophthalmol* 124 (2006) 988–992.
- [16] R. Klein, B.E. Klein, S.C. Jensen, S.M. Meuer, The five-year incidence and progression of age-related maculopathy: the beaver dam eye study, *Ophthalmology* 104 (1997) 7–21.
- [17] J.R. Vingerling, I. Dielemans, J.C. Witteman, A. Hofman, D.E. Grobbee, P.T. de Jong, Macular degeneration and early menopause: a case-control study, *BMJ* 310 (1995) 1570–1571.
- [18] W.D. Mathers, D. Stovall, J.A. Lane, M.B. Zimmerman, S. Johnson, Menopause and tear function: the influence of prolactin and sex hormones on human tear production, *Cornea* 17 (1998) 353–358.
- [19] R.G. Cumming, P. Mitchell, Hormone replacement therapy, reproductive factors, and cataract. The blue mountains eye study, *Am J Epidemiol* 145 (1997) 242–249.
- [20] B.E. Klein, R. Klein, L.L. Ritter, Is there evidence of an estrogen effect on age-related lens opacities? the beaver dam eye study, *Arch Ophthalmol* 112 (1994) 85–91.
- [21] M.O. Sator, E.A. Joura, P. Frigo, et al., Hormone replacement therapy and intraocular pressure, *Maturitas* 28 (1997) 55–58.
- [22] W. Smith, P. Mitchell, J.J. Wang, Gender, oestrogen, hormone replacement and age-related macular degeneration: results from the blue mountains eye study, *Aust N Z J Ophthalmol* 25 (Suppl 1) (1997) S13–S15.
- [23] Risk factors for central retinal vein occlusion, The eye disease case-control study group, *Arch Ophthalmol* 114 (1996) 545–554.
- [24] Risk factors for idiopathic macular holes. The eye disease case-control study group, *Am J Ophthalmol* 118 (1994) 754–761.
- [25] D. Feskanich, E. Cho, D.A. Schaumberg, G.A. Colditz, S.E. Hankinson, Menopausal and reproductive factors and risk of age-related macular degeneration, *Arch Ophthalmol* 126 (2008) 519–524.
- [26] S.L. Fine, in: J.W. F.S. Berger, M.G. Maguire (Eds.), *Age-related Macular Degeneration*, Mosby, St. Louis, 1999.
- [27] M.E. Verdugo-Gazdik, D. Simic, A.C. Opsahl, M.W. Tengowski, Investigating cytoskeletal alterations as a potential marker of retinal and lens drug-related toxicity, *Assay Drug Dev Technol* 4 (2006) 695–707.
- [28] K.S. Cho, Y.H. Yoon, J.A. Choi, S.J. Lee, J.Y. Koh, Induction of autophagy and cell death by tamoxifen in cultured retinal pigment epithelial and photoreceptor cells, *Investig Ophthalmol Vis Sci* 53 (2012) 5344–5353.
- [29] L.A. Kim, D. Amarnani, G. Gnanaguru, W.A. Tseng, D.G. Vavvas, P.A. D'Amore, Tamoxifen toxicity in cultured retinal pigment epithelial cells is mediated by concurrent regulated cell death mechanisms, *Investig Ophthalmol Vis Sci* 55 (2014) 4747–4758.
- [30] M. Saleh, T. Bourcier, G. Noel, C. Speeg-Schatz, D. Gaucher, Bilateral macular ischemia and severe visual loss following trastuzumab therapy, *Acta Oncol* 50 (2011) 477–478.